


**LISBON
2023**
Joint Congress of the
ECVP · ESVP · ECVCP · ESVCP



Joint European Congress of Veterinary Pathology & Clinical Pathology

Convention Center Lisbon Portugal
30 August - 2 September 2023





Contents

WELCOME MESSAGE

LOCAL ORGANISING COMMITTEE →

ESVP →

ECVP →

ESCVP →

PROGRAM

Wednesday 30 August - Thursday 31 August 2023 →

Friday 1 September - Saturday 2 September 2023 →

SPEAKER ABSTRACTS

Wednesday 30 August 2023 | Resident Day →

Thursday 31 August 2023 →

Friday 1 September 2023 →

Saturday 2 September 2023 →

ORAL ABSTRACTS

Veterinary Pathology Thursday 31 August 2023 →

Veterinary Pathology Friday 1 September 2023 →

Clinical Pathology Thursday 31 August 2023 →

Clinical Pathology Friday 1 September 2023 →

POSTER ABSTRACTS

Veterinary Pathology Animal models →

Veterinary Pathology Exotics, wildlife and non-human primates →

Veterinary Pathology Fish →

Veterinary Pathology Forensic matters →

Veterinary Pathology Livestock →

Veterinary Pathology Miscellaneous →

Veterinary Pathology Miscellaneous infectious disease →

Veterinary Pathology New methods, new technology, teaching →

Veterinary Pathology Tumour pathology →

Clinical Pathology →

PARTNERS →

SAVE THE DATES →



Joint European Congress of Veterinary Pathology & Clinical Pathology

Welcome to the 2023 Joint European Congress of Veterinary Pathology and Clinical Pathology (ESVP/ECVP/ESVCP/ECVCP), at the Lisbon Convention Center, in the beautiful, historical quarter of Belem, Lisbon, Portugal. Last year's congresses, in Greece and Serbia, were proof that we do need a place to connect to each other. In a world where devices are clearly invading and demanding our time, it feels safe to have a place to gather, a community to share ideas, experiences, languages, viewpoints, and mindsets.

The dream of organizing the European Pathology Meeting in Portugal has finally come true. We first applied to host this meeting 5 years ago, and we have been working since then to organize a successful and unforgettable event. It has been a rollercoaster ride, with doubts, hesitations, and stressful moments, altogether with joy, enrichment, and a sense of accomplishment. We hope that this endeavor will be reflected in the fulfillment that each of you may feel after attending this congress.

It will be the first time that these two Societies and Colleges organize a joint meeting in Portugal, and we have prepared a thrilling, diverse, and appealing program that will be of interest to all. With this joint congress, we aim to highlight the importance of an integrated approach in deciphering animal pathology, providing the maximal interaction between the two specialties on a program built around state-of-the-art joint sessions, keynote and educational talks, workshops, and more.

Lisbon is mainland Europe's westernmost capital city and the only one along the Atlantic coast. It is one of the oldest cities in the world and the second oldest in Europe. It is a historical city full of history, where the sun shines 290 days a year and the temperature rarely drops below 15°C. A city full of authenticity where old customs and ancient history intermix with cultural entertainment and hi-tech innovation. Lisbon is ageless, and famous for its hospitality and family-like way to welcome visitors. We look forward to welcoming you in Lisbon.

Pedro Faísca, DVM, DEA, PhD
Maria C. Peleteiro, DVM, PhD, dipl. ECVP
Nazaré Pinto da Cunha, DVM, PhD, dipl. ECVCP
Co-Chairs of the Local Organising Committee





European Society of Veterinary Pathology



Here we are. Lisbon is in front of us. Our next Joint Congress, with our sister society, the European Society of Veterinary Clinical Pathology (ESVCP), is already a success, with an attendance that would be among the highest of our Annual Conference since several years. After Athens and Belgrade, that were the successful comebacks of our face-to-face Annual Congresses, we perfectly know how such events are crucial in terms of sociability and human interactions among our community.

The increased number of young colleagues, residents and PhD Students attending our Meetings, are also a promising feature and a strong encouraging signal. Working for them is our honour. Lisbon 2023 will be a wonderful opportunity to strengthen the natural link between our communities, of pathologists. Particularly between the residents of both our Colleges, the ECVP and ECVCP ones. The LOC team, Pedro Faisca, Nazaré Pinto da Cunha and Maria Peleteiro with the help of our PCO Pauwels, has remarkably organized this event. And the program that has been built by the Scientific Committee of the ESVP-ECVP-ESVCP will undoubtedly cover our expectations.

Looking forward to see you all in Portugal.

Sincerely and kindly

Jérôme Abadie
President ESVP





European College of Veterinary Pathologists



It is time to meet again in person at our yearly meeting, organized in Lisbon, Portugal, together with the European Society of Veterinary Pathology and again with our colleagues from Clinical Pathology. The Scientific Committee and the Local Organizing Committee has worked hard and put together an exciting meeting program taking place at the Lisbon Congress Centre. A pre-congress day, aimed for residents, yet open for all, will start the meeting followed by two-and-a half days of joint key-note lectures, oral communications, workshops and coffee breaks offering the opportunity to catch up with each other.

Topics cover the whole broad spectrum of Veterinary Pathology: infectious and degenerative diseases, oncology, in species ranging from fish over to birds, dogs and farm animals, with spotlights on current topics like climate change, artificial intelligence, avian influenza... Lectures from our colleagues working in clinical pathology, open to all, will bring new insights and bridge both our specialties. There will be many opportunities to hear about the latest findings of fascinating research topics, get great overviews by experts in their fields, exchange different opinions and discuss contrasting views. The beauty of Lisbon will enhance our meeting and we encourage all of you to discover the old city and its attractions after conferences are over. Most importantly, our meeting is the best opportunity to meet old friends, make new ones, and feel part of our great community of people fascinated by veterinary pathology in one way or the other.

I wish you a great and pleasant meeting with many enjoyable moments.

Andrea Gröne
ECVP President





European Society of Veterinary Clinical Pathology



This year we have a joint congress of ESVCP/ECVCP and ESVP/ECVP. In the past we already had the opportunity to unite both disciplines in a joint congress. Thereby we repeatedly noticed how inspiring the exchange between clinical pathologists and pathologists is. This year we will also meet in the beautiful city of Lisbon, where we will follow in the footsteps of famous explorers and adventurers. Henry the Navigator, Vasco da Gama, Ferdinand Magellan, Bartolomeus Dias and Christopher Columbus are all associated with this city in different ways. And are we clinical pathologists and pathologists not also explorers? While we do not explore the oceans, we do explore the hidden worlds of animals.

This year's Congress is an opportunity to exchange ideas, share insights, and broaden experiences. We all know that our work in the lab often seems somewhat mysterious when viewed from the outside. But we are the heroes in the background and may selfconfidently share our knowledge with clinicians. Not infrequently, clinical decisions are made on the basis of laboratory tests and pathological examinations. This should motivate us to establish new or improve existing tests. But we don't just want to talk about our work here, we also want to have a great time together. Therefore we have put together an exciting program of lectures, discussions and workshops to expand our knowledge, but this should take place in a relaxed environment. Hence the choice for Lisbon.

At this point I would like to thank all the organizers who made this congress possible. It takes a lot of work and commitment to organize such an outstanding event. A special thanks also goes to our sponsors who support us in making this congress an unforgettable experience.

Let's use these days in Lisbon to inspire each other, to learn and to laugh. I wish us a fantastic congress, full of valuable insights, warm encounters and unforgettable moments!

With bestly best regards,

Stephan Neumann
President ESVCP



30 August

RESIDENT DAY AUDITORIUM III

09.00-10.30
QuPath Workshop II - Part 1
 Learn how to use open source software for quantitative pathology & bioimage analysis - focus on AI
Zbigniew Mikulski, Robert Klopfeisch

10.30-11.00 **Break**, Foyer D

11.00-12.30
QuPath Workshop II - Part 2
 Learn how to use open source software for quantitative pathology & bioimage analysis - focus on AI
Zbigniew Mikulski, Robert Klopfeisch

12.30-14.00 **Lunch** Foyer D

14.00-15.30
Research Methodology II - Part 1
 The Scientific Method. The design of clinical studies and basic statistics
Laura Peña, Adelina Gama, Guillermo Valdivia

15.30-16.00 **Break**, Foyer D

16.00-17.30
Research Methodology II - Part 2
 The Scientific Method. The design of clinical studies and basic statistics
Laura Peña, Adelina Gama, Guillermo Valdivia

19.00-20.00 **Welcome Reception**
 Auditorium I & Foyer D

31 August

AUDITORIUM I

08.00-09.00 **Residents breakfast** 
 Separate registration required

09.00-09.45
Climate change & animal health session
 Keynote Lecture: Sand fly borne-diseases in Europe - epidemiological overview and potential triggers for their emergence and re-emergence
Carla Maia

09.45-10.30
Special session
 Exploring the Potential of Natural Language Processing in Veterinary Pathology: Applications and Insights from ChatGPT
Lev Stimmer

10.30-11.00 **Break | Exhibition & Poster Tour:** Exotic, Wild Animals, NHP & Miscellaneous & Poster Flash

11.00-11.45
Exotics, zoo & wild animals
 Oral Presentations

11.45-12.30
Special session

12.30-14.00 **Lunch | Exhibition**

14.00-15.30
Keynote Lecture: Aquaculture & wild fish pathology session
 Parasitic diseases of relevance in aqua-culture and wild fish in Europe and the impact of global warming
Heike Schmidt-Posthaus, Roberto Bermudez Pose

16.00-17.15
New methods, new technology; teaching
 Oral Presentations

17.30-19.00
ECVP AGM

AUDITORIUM II

11.00-11.45
Pathophysiology and clinical pathology of bone and joint disease
Stephan Neumann

11.45-12.30
Hematology
 Oral Presentations

14.00-14.45
Biochemistry
 Oral Presentations

14.45-15.30
Biochemistry
 Oral Presentations

16.00-16.45
Evolution of Erythrocytes in Vertebrates
John Harvey


16.45-17.30
Equine Haematology: Foal to Adult
Alexandra Draper

17.30-18.30
ECVCP AGM

AUDITORIUM III

11.00-11.45
Miscellaneous
 Oral Presentations

11.45-12.30
Poster flash
 Oral Presentations

14.00-14.45
Immature platelet fraction (IPF) in the differential diagnosis of canine and feline thrombocytopenia

Alejandro Pérez Écija

14.45-15.30
Hematology
 Oral Presentations

16.00-16.45
Fish pathology
 Oral Presentations

16.45-17.30
ECVP Examination
 Tips and tricks for residents and supervisors



ROOM 1.07

09.00-10.30
Workshop - Part 1 Scientific Poster
 How do I do it? Visual communication strategies for scientific posters
Diana Vieira da Silva

11.00-12.30
Workshop - Part 2 The Visual Abstract
 What is it and how do I do it?
Ana Rita Baptista

ROOM 1.08

14.00-15.30
Workshop Digital Gross Photography in Anatomic Pathology
Luján Lluís

-  **Joint Sessions**
-  **Veterinary Pathology**
-  **Veterinary Clinical Pathology**

1 September

AUDITORIUM I

08.45-10.15
Livestock pathology session
 Keynote lecture: Update on Avian influenza virus infection in Europe *Natàlia Majo*
Diagnostic talk
 Emerging problems in poultry: What are the poultry diagnosticians facing? *Alex Cobos*

AUDITORIUM II

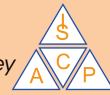08.45-09.30
Repeat Patient Testing for Veterinary haematology analysers *Susan Daly*
 09.30-10.15
A Practical Approach to Testing For Common Equine Endocrinopathies
Alex Draper

AUDITORIUM III

08.45-09.30
Cytology
 Oral Presentations
 09.30-10.15
Cytology
 Oral Presentations

10.15-10.45 **Break | Exhibition & Poster Tour** Tumour & Livestock & Clinical Pathology

10.45-11.30
Bone Marrow Biopsies: Aspirates versus Cores *John Harvey*
 11.30-12.15
Cytology grading schemes what can and can not be said *Paola Monti*




10.45-11.30
Tumour Pathology
 Oral Presentations
 11.30-12.15
Tumour Pathology
 Oral Presentations

10.45-11.30
Livestock
 Oral Presentations
 11.30-12.15
Livestock
 Oral Presentations

12.15-13.30 **Lunch | Exhibition**

13.30-15.30
Oncology & oncopathology session
 Keynote lectures: Closing the circle: Bridging the advances in cancer understanding with advances in therapeutics and diagnosis *David Argyle*
 Clinical laboratory experience with a next-generation sequencing-based liquid biopsy test for cancer detection in dogs *Andi Flory*
 Is histopathology of tumors outdated? Advances and potentials of old-fashioned techniques in the -omics era *Giancarlo Avallone*



15.30-16.00 **Break | Exhibition & Poster Tour** Animal Models & Forensic Matters

16.00-17.30
Cytology Mystery Slides
Carlo Masserdoti
 17.30-18.30
ESVCP AGA



16.00-16.45
Animal models
 Oral Presentations
 16.45-17.30
Animal models
 Oral Presentations
 17.30-18.30
ESVP AGM

16.00-17.00
Forensic matters
 Oral Presentations
 17.00-17.30
Vet pathology journal session
 An overview and update on publishing in Veterinary Pathology *Joshua Webster*

19.30-00.00 **Gala Dinner & Dance Party** Venue: *Estufa Fria*

2 September

AUDITORIUM I

09.00-10.30
Clinical cases through the lens of clinical and anatomical pathologists
Helena Ferreira, Danilo Wasques



AUDITORIUM II

10.30-11.00 **Break**

11.00-12.30
Anatomic Pathology Mystery Slide Session
Second Opinion Round
Elena Riccardi, Dimitra Psalla
 12.30-13.00
Congress conclusions
 Veterinary Pathology

11.00-12.30
Clinical Pathology Case Presentations
Mariana Serra, Marta Costa
 12.30-13.00
Congress conclusions
 Clinical Pathology

Microscopes Room 1.05

THURSDAY 31 AUGUST 09.00-17.30
FRIDAY 1 SEPTEMBER 08.45-17.30
SATURDAY 2 SEPTEMBER 09.00-13.00

Speaker preview Room 1.14

WEDNESDAY 30 AUGUST 08.00-19.00
THURSDAY 31 AUGUST 08.00-17.00
FRIDAY 1 SEPTEMBER 08.00-17.00
SATURDAY 2 SEPTEMBER 08.00-13.00

- Joint Sessions**
- Veterinary Pathology**
- Veterinary Clinical Pathology**


AnaPath – your reliable Histopathology and *in vivo* Safety Assessment Partner!

AnaPath is a global contract research organization (CRO) for Pharma, Biotech, (Agro) Chemical & MD companies. AnaPath serves third party CROs and direct client equally. It is renowned for its scientific competence in toxicological pathology, high operational speed and reliability. AnaPath Services was founded by Dr. Klaus Weber, Dipl. JSTP, 10 years ago. Today AnaPath engages over 230 employees on 5 sites in Switzerland, Spain, and Korea.

AnaPath Services GmbH, based in Liestal, Switzerland, offers various special techniques in addition to routine histopathology, all supported by 9 pathologists.

AnaPath offers in-house Scanning and Transmission Electron Microscopy (SEM, TEM) equipped with EDX services, Digital Pathology, Slide Scanning, Histomorphometry and Image Analysis. The latter ranges from routine Fibrosis Measurements or Neurohistomorphometry to bespoke projects supporting also Medical Device Pathology to extract data by supervised machine learning.

The service extends into Biomarker analysis, Tissue Cross Reactivity (TCR), Endocrine Disruptor evaluation, and pathology of uncommon laboratory species like fish, amphibian, birds and invertebrates.



AnaPath Research S.A.U. in Barcelona, Spain, is AAALAC accredited and like AnaPath Services GLP certified. Backed by over 30 years of experience, AnaPath Research provides *in vivo* safety assessment in all pre-clinical species and dosing routes from acute to cancerogenicity studies, managed First-in-to Human enabling packages, DART studies, Safety Pharmacology, fitted with bioanalytics and biomarker evaluation.

AnaPath

Interested in our services
or scientific discussion
with AnaPath scientists?


Visit us at
booth no. 1
Pavilion 4

Or contact us via email:
info@anapath.ch



Meet our Pathologists:

**AnaPath
Services GmbH**
Hammerstrasse 49
4410 Liestal
Switzerland
www.anapath.ch





Speaker Abstracts

Wednesday 30 August 2023
Resident Day

JOINT STREAM

- 09.00 -12.30** QUPATH WORKSHOP II – LEARN HOW TO USE OPEN SOURCE SOFTWARE FOR QUANTITATIVE PATHOLOGY & BIOIMAGE ANALYSIS -
FOCUS ON AI *Zbigniew Mikulski & Robert Klopfeisch* →
- 14.00 -17.30** RESEARCH METHODOLOGY II - THE SCIENTIFIC METHOD.THE DESIGN OF CLINICAL STUDIES AND BASIC STATISTICS
Adelina Gama & Guilherme Valdivia & Laura Peña →

Speaker Abstracts

Thursday 31 August 2023

JOINT STREAM


- 09.00 -09.45** SAND FLY BORNE-DISEASES IN EUROPE - EPIDEMIOLOGICAL OVERVIEW AND POTENTIAL TRIGGERS FOR THEIR EMERGENCE AND RE-EMERGENCE *Carla Maia* →
- 09.00 -10.30** WORKSHOP SCIENCE COMMUNICATIONS PART 1 - SCIENTIFIC POSTER. HOW DO I DO IT? VISUAL COMMUNICATION STRATEGIES FOR SCIENTIFIC POSTERS *Diana Vieira da Silva* →
- 09.45 -10.30** EXPLORING THE POTENTIAL OF NATURAL LANGUAGE PROCESSING IN VETERINARY PATHOLOGY: APPLICATIONS AND INSIGHTS FROM CHATGPT *Lev Stimmer* →
- 11.00 -12.30** WORKSHOP SCIENCE COMMUNICATION PART 2 - THE VISUAL ABSTRACT. WHAT IS IT AND HOW DO I DO IT? *Ana Rita Baptista* →
- 14.00 -14.45** WORKSHOP DIGITAL GROSS PHOTOGRAPHY IN ANATOMIC PATHOLOGY *Luján Lluís* →

VETERINARY PATHOLOGY STREAM

- 14.00 -15.30** PARASITIC DISEASES OF RELEVANCE IN AQUACULTURE AND WILD FISH IN EUROPE AND THE IMPACT OF GLOBAL WARMING *Heike Schmidt-Posthaus, Roberto Bermudez Pose* →

CLINICAL PATHOLOGY STREAM

- 11.00 -11.45** PATHOPHYSIOLOGY AND CLINICAL PATHOLOGY OF BONE AND JOINT DISEASES *Stephan Neuman* →
- 14.00 -14.45** IMMATURE PLATELET FRACTION (IPF) IN THE DIFFERENTIAL DIAGNOSIS OF CANINE AND FELINE THROMBOCYTOPENIA *Alejandro Pérez Écija* →
- 16.00 -16.45** EVOLUTION OF ERYTHROCYTES IN VERTEBRATES *John Harvey* →
- 16.45 -17.30** EQUINE HAEMATOLOGY - FOAL TO ADULTS *Alexandra Draper* →



Speaker Abstracts

Friday 1 September 2023

JOINT STREAM

- 13.30-14.10** CLOSING THE CIRCLE: BRIDGING THE ADVANCES IN CANCER UNDERSTANDING WITH ADVANCES IN THERAPEUTICS AND DIAGNOSIS *David Argyle* →
- 14.10-14.50** CLINICAL LABORATORY EXPERIENCE WITH A NEXT-GENERATION SEQUENCING-BASED LIQUID BIOPSY TEST FOR CANCER DETECTION IN DOGS *Andi Flory* →
- 14.50-15.30** IS HISTOPATHOLOGY OF TUMORS OUTDATED? ADVANCES AND POTENTIALS OF OLD-FASHIONED TECHNIQUES IN THE -OMICS ERA *Giancarlo Avallone* →

VETERINARY PATHOLOGY STREAM

- 08.45-09.30** KEYNOTE LECTURE: UPDATE ON AVIAN INFLUENZA VIRUS INFECTION IN EUROPE *Natàlia Majó Masferrer* →
- 09.30-10.15** DIAGNOSTIC TALK: EMERGING PROBLEMS IN POULTRY: WHAT ARE THE POULTRY DIAGNOSTICIANS FACING? *Alex Cobos* →

CLINICAL PATHOLOGY STREAM

- 08.45-09.30** REPEAT PATIENT TESTING FOR VETERINARY HAEMATOLOGY ANALYSERS *Susan Daly* →
- 09.30-10.15** A PRACTICAL APPROACH TO TESTING FOR COMMON EQUINE ENDOCRINOPATHIES *Alexandra Draper* →
- 10.45-11.30** BONE MARROW BIOPSIES: ASPIRATES VERSUS CORES *John Harvey* →
- 11.30-12.15** CYTOLOGY GRADING SCHEMES - WHAT CAN AND CAN NOT BE SAID *Paola Monti* →
- 16.00-17.30** CYTOLOGY MYSTERY SLIDES *Carlo Masserdoti* →



Speaker Abstracts

Saturday 2 September 2023

JOINT STREAM

09.00 -10.30 CLINICAL CASES THROUGH THE EYES OF CLINICAL AND ANATOMICAL PATHOLOGISTS *Danilo Gouveia Wasques & Helena Ferreira* →

VETERINARY PATHOLOGY STREAM

11.00 -12.30 ANATOMIC PATHOLOGY MYSTERY SLIDE SESSION - SECOND OPINION ROUND *Dimitra Psalla & Elena Riccardi* →





Oral Abstracts

Veterinary Pathology

Thursday 31 August 2023

11.00-11.45 | SESSION 1: MISCELLANEOUS

- 11.00-11.15** PATHOLOGICAL FEATURES OF AN OUTBREAK OF A NON-VIRAL PANCYTOPAENIA IN CATS *J. Williams* →
- 11.15-11.30** DIAGNOSTIC PITFALLS IN CLINICAL MEDICAL DEVICE STUDIES: A CASE STUDY ANALYSIS *O.K. Richard* →
- 11.30-11.45** EFFECT OF AGE ON THE OCCURRENCE OF ENDOMETRIAL ADENOCARCINOMA, PYOMETRA AND ENDOMETRIAL CYSTIC HYPERPLASIA IN CATS: A DESCRIPTIVE STUDY *A. Jordão* →

11.00-12.00 | SESSION 2: EXOTICS, ZOO AND WILD ANIMALS

- 11.00-11.15** CETACEAN NEUROBRUCELLOSIS: PATHOLOGICAL AND IMMUNOLOGICAL COMPARATIVE ASPECTS WITH HUMANS AND ANIMAL MODELS *A. Rebollada-Merino* →
- 11.15-11.30** ERYSIPELAS IN A DOLPHIN WITH UNUSUAL CENTRAL NERVOUS SYSTEM INVOLVEMENT. WHAT DO PIGS AND DOLPHINS HAVE IN COMMON? *L. Martino* →
- 11.30-11.45** SPONTANEOUS OUTBREAK OF MYCOBACTERIUM TUBERCULOSIS COMPLEX IN LABORATORY CYNOMOLGUS MONKEYS (MACACA FASCICULARIS) *K. Kegler* →

11.45-12.30 | SESSION 3: POSTER FLASH

- 11.45-11.50** DIFFERENTIAL DIAGNOSIS FOR HEPATIC DISEASE AS THE CAUSE OF SERUM ALAT INCREASE; MYOPATHY OF THE SCHAPENDOES BREED DOG *P. Syrjä* →
- 11.50-11.55** BEYOND ANGIOGENESIS: UNVEILING VESSEL CO-OPTION AND VASCULOGENIC MIMICRY IN HIGHLY MALIGNANT CANINE CANCER *G. Valdivia* →
- 11.55-12.00** A ONE PATHOLOGY, MULTICENTRE PORTUGUESE APPROACH TO THYROID TUMOURS OF DOGS AND CATS *T.B. Gaspar* →
- 12.00-12.05** NUCLEAR MORPHOMETRY AND EXPRESSION OF CK20, P53 AND KI-67 IN THE DIAGNOSIS OF BLADDER TRANSITIONAL CELL CARCINOMAS IN DOGS *J.G. Xavier* →
- 12.05-12.10** DETECTION OF PD-L1, PD-1, AND CTLA-4 BY RNA IN SITU HYBRIDIZATION IN CANINE ORAL MELANOCYTIC NEOPLASMS AND THEIR MICROENVIRONMENT *G. Foian* →
- 12.10-12.15** METHYLATION ANALYSIS OF LINE-1 ELEMENTS AND MORPHOLOGICAL NUCLEAR PARAMETERS IN THE DIFFERENTIAL DIAGNOSIS OF CUTANEOUS MELANOCYTIC TUMORS IN DOGS *J.G. Xavier* →
- 12.15-12.20** IMMUNO-ONCOLOGICAL CHARACTERIZATION OF CANINE CUTANEOUS HISTIOCYTOMA BY GENE EXPRESSION PROFILING UTILIZING NANOSTRING NCOUNTER® RNA HYBRIDIZATION TECHNIQUE *A. Haake* →
- 12.20-12.25** STREAMLINING MICROSCOPE-BASED KI-67 INDEX ESTIMATION: LET'S MAKE IT SIMPLE! *S. Valente* →
- 12.25-12.30** ARTIFICIAL INTELLIGENCE PREDICTS THE C-KIT-11 MUTATIONAL STATUS OF CANINE CUTANEOUS MAST CELL TUMOURS THROUGH THEIR PHENOTYPE IN HE STAINED HISTOLOGICAL SLIDES *C. Puget* →

Oral Abstracts

Veterinary Pathology

Thursday 31 August 2023

16.00-16.45 | SESSION 4: FISH PATHOLOGY

- 16.00-16.15** AN OUTBREAK OF CRYPTOCARYON IRRITANS DURING QUARANTINE-NEW VARIATIONS OF AN OLD THEME *D. Denk* →
16.15-16.30 SYSTEMIC GRANULOMATOSIS IN MEAGRE (*ARGYRO SOMUS REGIUS*): A LINK WITH ATYPICAL MYCOBACTERIA *M. Polinas* →
16.30-16.45 RECURRENT FISH KILLS IN A SMALL WARM RESERVOIR: LIFE ON THE VERGE OF DEATH *F. Godinho* →

16.00-17.15 | SESSION 5: NEW METHODS, NEW TECHNOLOGY, TEACHING

- 16.00-16.15** PROCESSING METHODOLOGY FOR HISTOPATHOLOGICAL ASSESSMENT OF BLACK SOLDIER FLY (*HERMETIA ILLUCENS*) LARVAE GUT. *A. Alvarado-Muñoz* →
16.15-16.30 CANINE MAMMARY TUMORS DATASET (CMTD): AN OPEN HISTOPATHOLOGY RESOURCE FOR COMPUTER-AIDED PATHOLOGY *G.P. Burrai* →
16.30-16.45 COMPARATIVE SPATIAL PROTEOMICS BETWEEN SARS-COV-2 INFECTED LUNGS OF ROBOROVSKI DWARF HAMSTERS AND SYRIAN HAMSTERS *S. Kunder* →
16.45-17.00 TRAINING ON HEALTHY TO LEARN PATHOLOGY": AN ALTERNATIVE APPROACH FOR A.I. SUPERVISED LEARNING IN NEOPLASTIC TISSUES *L. Ressel* →
17.00-17.15 THE VIRTUAL POST MORTEM ROOM: IMMERSIVE GROSS PATHOLOGY EXPERIENCE IN THE METAVERSE *L. Ressel* →





Oral Abstracts

Veterinary Pathology

Friday 1 September 2023

10.45-12.15 | SESSION 6: LIVESTOCK

- 10.45-10.58** RE-EMERGENCE OF OVINE SHEEPPOX INFECTION IN SPAIN AFTER 54 YEARS *L. Luján* →
- 10.58-11.11** A SEVERE OUTBREAK OF COLIBACILLOSIS IN BROILERS *S. Kromann* →
- 11.11-11.24** UNRAVELLING THE PROTEIN SIGNATURE OF BOVINE AND PORCINE GRANULOMAS IN ANIMALS WITH A MYCOBACTERIUM TUBERCULOSIS COMPLEX FIELD INFECTION BY USING MALDI-MSI *J. Gómez Laguna* →
- 11.24-11.37** DISCOVERY OF THE AVIAN RECEPTOR IN THE PORCINE NASAL MUCOSA REVEALS NEW INSIGHT INTO INFLUENZA A VIRUS HOST TROPISM *C. Kristensen* →
- 11.37-11.50** PORCINE CIRCOVIRUS 3 (PCV-3) EXPERIMENTAL INOCULATION IN PREGNANT GILTS *A. Cobos* →
- 11.50-12.03** EFFICIENCY OF DIFFERENT ORF VIRUS INFECTION ROUTES FOR THE EXPERIMENTAL REPRODUCTION OF CONTAGIOUS ECTHYMA IN LAMBS *Á. Gómez* →
- 12.03-12.16** IS MECHANICAL MUCOSAL INJURY THE HIDDEN CULPRIT OF HAEMORRHAGIC BOWEL SYNDROME IN CATTLE? *B. De Jonge* →

10.45-12.15 | SESSION 7: TUMOUR PATHOLOGY

- 10.45-10.58** FREE-CIRCULATING AND EXTRACELLULAR VESICLE-ASSOCIATED MICRORNAS IN HEALTHY AND T CELL LYMPHOMA BEARING DOGS *V. Moccia* →
- 10.58-11.11** STEREOLOGICAL ESTIMATION OF MEAN NUCLEAR VOLUME AS PROGNOSTIC FACTOR IN CANINE SUBCUTANEOUS MAST CELL TUMORS *J. Catarino* →
- 11.11-11.24** COMPARISON OF CYTOLOGICAL AND HISTOLOGICAL CLASSIFICATION SYSTEMS FOR THE DETECTION OF NODAL METASTASES OF CANINE MAST CELL TUMOURS *A. Renzi* →
- 11.24-11.37** PROPOSAL FOR A NEW HISTOLOGICAL GRADING SYSTEM FOR CANINE ORAL MELANOCYTIC TUMORS *F. Chocteau* →
- 11.37-11.50** RAC1 PATHWAY IN CANINE ORAL MELANOMA PROGRESSION AND PROGNOSIS *A. Lo Giudice* →
- 11.50-12.03** CORRELATION BETWEEN MALIGNANT HISTOLOGICAL FEATURES OF CANINE DIGITAL SQUAMOUS CELL CARCINOMA AND GENETIC KIT LIGAND COPY NUMBER VARIATION *A. Cerezo Echevarría* →
- 12.03-12.16** EXPRESSION OF THE INHIBITOR-OF-APOPTOSIS SURVIVIN IS ASSOCIATED WITH POOR PROGNOSIS IN CANINE INVASIVE MAMMARY CARCINOMA *M. Cuvelier* →



Oral Abstracts

Veterinary Pathology Friday 1 September 2023

16.00 - 17.30 | SESSION 8: ANIMAL MODELS

- 16.00-16.11** NEURONAL AND MYOCARDIAL DAMAGE IN A RAT MODEL OF VENTRICULAR FIBRILLATION CARDIAC ARREST WITH EXTRACORPOREAL CARDIOPULMONARY RESUSCITATION *S. Högler* →
- 16.11-16.22** PATHOLOGICAL AND TRANSCRIPT ANALYSIS OF PROTECTION INDUCED BY MTBVAC AND BCG AGAINST MYCOBACTERIUM TUBERCULOSIS INFECTION IN RHESUS MACAQUES *F.J. Salguero* →
- 16.22-16.33** USUTU VIRUS EXPERIMENTAL INFECTION IN EURASIAN BLACKBIRDS (TURDUS MERULA): A STEP TOWARDS THE IDENTIFICATION OF AN EXPERIMENTAL AVIAN MODEL *G. Agliani* →
- 16.33-16.44** VASCULAR CHANGES IN ASSOCIATION WITH NON-SUPPURATIVE ENCEPHALITIS IN SARS-COV-2 INFECTED K18-HACE2 MICE *S. De Neck* →
- 16.44-16.55** COULD HAMSTERS BE A MODEL FOR RESPIRATORY POST-ACUTE SEQUELAE OF SARS-COV-2? *L. Heydemann* →
- 16.55-17.06** NERVE REGENERATION AFTER TRAUMA-INDUCED WALLERIAN DEGENERATION: WHAT DO WE LEARN FROM MURINE ANIMAL MODELS? *R. de Miguel* →
- 17.06-17.17** MITOCHONDRIAL DEFECTS IN THE PARL DEFICIENT MOUSE MODEL LEAD TO ARRESTED SPERMATOGENESIS AND FERROPTOSIS *E. Radaelli* →
- 17.17-17.27** IMPACT OF THE CGAS/STING PATHWAY ON THE TUMOUR ECOSYSTEM UNDER CHEMOTHERAPEUTIC PRESSURE IN TRIPLE NEGATIVE BREAST CANCER *F. Chocteau* →

16.00 - 17.00 | SESSION 9: FORENSIC MATTERS

- 16.00-16.15** GROSS, HISTOLOGICAL, AND CHEMICAL EVALUATION OF GUNSHOT WOUNDS IN VETERINARY FORENSIC PATHOLOGY *G. Piegari* →
- 16.15-16.30** FORENSIC EVALUATION OF TAIL LESIONS IN PIGS: HISTOLOGICAL AND RADIOLOGICAL OBSERVATIONS *C.K. Flyger* →
- 16.30-16.45** SKIN ULCERATIONS IN DANISH NURSERY PIGS *K. Barington* →
- 16.45-17.00** BETA-AMYLOID PRECURSOR PROTEIN (β APP) AS A BIOMARKER FOR DETECTING TRAUMATIC AXONAL INJURY IN CATS *W.H. Huang* →



Oral Abstracts

Clinical Pathology

Thursday 31 August 2023

11.45-12.30 | SESSION 1: HEMATOLOGY

- 11.45-12.00** ESTABLISHING A MURINE MODEL ON LOW-DENSITY NEUTROPHILS GRANULOPOIESIS FOR PAEDIATRIC CEREBRAL MALARIA *C. Attipa* →
- 12.00-12.15** BOMBAY-LIKE DISCORDANCE BETWEEN ABC BLOOD GENOTYPE AND PHENOTYPE IN A DOMESTIC SHORT-HAIRED CAT *A. Ginoudis* →
- 12.15-12.30** PLASMA MRNA LEVELS OF CDC6 DECREASE IN RESPONSE TO CHEMOTHERAPY IN CANINE LYMPHOMA PATIENTS *A. Musi* →

14.00-14.45 | SESSION 2: BIOQUEMISTRY

- 14.00-14.15** DETECTION OF RENAL TUBULAR TRANSPORTER PROTEINS IN CANINE URINARY EXTRACELLULAR VESICLES USING LIQUID CHROMATOGRAPHY TANDEM MASS SPECTROMETRY *T. Williams* →
- 14.15-14.30** DETECTION OF TOTAL CELLULAR HISTAMINE IN BLOOD FROM CANINE AND FELINE PATIENTS USING A NOVEL BASOPHIL HISTAMINE RELEASE ASSAY *A. Krogh* →
- 14.30-14.45** RELATIONSHIP BETWEEN INFLAMM-AGING AND MYXOMATOUS MITRAL VALVE DISEASE (MMVD) IN SENIOR AND GERIATRIC DOGS: PRELIMINARY RESULTS *F. Bonsembiante* →

14.45-15.30 | SESSION 3: BIOQUEMISTRY

- 14.45-15.00** GLYCATED HAEMOGLOBIN (HBA1C) AND SERUM FRUCTOSAMINE IN SICK, NON-DIABETIC DOGS RECEIVING ORAL PREDNISOLONE: PRELIMINARY RESULTS *I. Oikonomidis* →
- 15.00-15.15** CAN WE USE OUR PATIENT DATABASE FOR ESTIMATING REFERENCE INTERVALS? CHALLENGES AND OPPORTUNITIES OF THE NEW "INDIRECT METHODS" *S. Manzocchi* →
- 15.15-15.30** EVALUATION OF A NOVEL APPROACH TO DETERMINE A REFERENCE INTERVAL OUT OF MIXED DATA SETS AND CALCULATION OF OPTIMIZED CUTOFFS FOR CANINE DGGR LIPASE *A. Pankraz* →

14.45-15.30 | SESSION 4: HEMATOLOGY

- 14.45-15.00** AGREEMENT BETWEEN NUCLEATED RED BLOOD CELLS INSTRUMENTAL COUNT USING SYSMEX XN-V AND MANUAL COUNTS AND POSSIBLE IMPACT ON THE DIAGNOSIS OF ANEMIA AND LEUKOPENIA *S. Paltrinieri* →
- 15.00-15.15** ASSOCIATION BETWEEN LIPAEMIA, HAEMOLYSIS AND ICTERUS, AND DIFFERENCE BETWEEN MEAN CORPUSCULAR HAEMOGLOBIN CONCENTRATION (MCHC) AND MEAN CELLULAR HAEMOGLOBIN CONCENTRATION (CHCM) (δ MCHC-CHCM) IN CANINE COMPLETE BLOOD COUNT ASSESSED WITH SIEMENS ADVIA 2120 *M. Ferrari* →
- 15.15-15.30** DEFINITIVE RADIOTHERAPY IN DOGS WITH SOLID TUMORS ALTERS PERIPHERAL LYMPHOCYTES AND MONOCYTES *J. Lawrence* →



Oral Abstracts

Clinical Pathology

Friday 1 September 2023

08.45-09.30 | SESSION 5: CYTOLOGY

- 08.45-09.00** PREDICTING CANINE CUTANEOUS MAST CELL TUMOR BEHAVIOR BY INTEGRATING CYTOLOGY AND STEREOLOGY *R. Marcos* →
- 09.00-09.15** FLOW CYTOMETRY APPLICATION IN THE DETECTION OF NODAL METASTASIS IN DOGS WITH MAST CELL TUMOUR *G. Iamone* →
- 09.15-09.30** CYTOLOGY OF AQUEOUS HUMOR IN CATS WITH UVEITIS *D. Legroux* →

09.30-10.15 | SESSION 6: CYTOLOGY

- 09.30-09.45** CEREBROSPINAL FLUID FINDINGS AND CENTRAL NERVOUS SYSTEM DISORDERS IN SMALL RUMINANTS – A RETROSPECTIVE STUDY IN SHEEP AND GOATS *B. Riond* →
- 09.45-10.00** CYTOMORPHOLOGICAL ASSESSMENT OF CANINE INTERMEDIATE/LARGE CELL LYMPHOMA – A PROPOSED MODEL FOR PHENOTYPE PREDICTION: PRELIMINARY RESULTS *M. Neta* →
- 10.00-10.15** IMMUNOHISTOCHEMICAL CLASSIFICATION OF THE FOÀ-KURLOFF CELL IN GUINEA PIGS *K. Weber* →



Poster Abstracts

Veterinary Pathology

ANIMAL MODELS

- 1** EFFECT OF TESTOSTERONE AND TACROLIMUS ON NERVE REGENERATION PROCESS AFTER INJURY IN RAT: HISTOPATHOLOGIC EVALUATION *M. Jazinidorcheh* →
- 17** THREE-DIMENSIONAL QUALITATIVE AND QUANTITATIVE ANALYSIS OF MOUSE CORNEAL NERVE *M. Inanaga* →
- 22** CHARACTERIZATION OF RENAL (DYS)FUNCTION IN RAT MODELS OF EARLY AND ADVANCED CHRONIC KIDNEY DISEASE *H. Vala* →
- 40** A NEW WILD TYPE MOUSE MODEL PAVES THE WAY FOR THE STUDY OF USUTU VIRUS PATHOGENICITY IN MAMMALS *M. Gérardy* →
- 48** ACCELERATION OF AGE-ASSOCIATED CHANGES AND DECREASED SURVIVAL IN OLD MICE BY DELETION OF THE GENE FLOWER *T. Carvalho* →
- 66** INSIGHTS INTO THE PATHOGENESIS OF PERIPHERAL NERVE LESIONS IN A MODIFIED VIRUS-INDUCED ANIMAL MODEL OF MULTIPLE SCLEROSIS *E. Leitzen* →
- 67** DCIR EXPRESSION ON DENDRITIC CELLS DECELERATES EARLY T CELL ACTIVATION IN A MURINE MIXED BONE MARROW CHIMERA MODEL OF NEUROTROPIC VIRUS INFECTIONS *M. Stoff* →
- 69** OLFACTORY AND RESPIRATORY EPITHELIAL IMPAIRMENT AND RECOVERY AFTER VANADIUM EXPOSURE IN RATS *M.I. Pinto* →
- 70** CAUSES AND INCIDENCE OF FAILURE TO LITTER IN CONTROL RATS FROM EXTENDED ONE-GENERATION REPRODUCTIVE TOXICITY STUDIES *M. Levi* →
- 71** EFFECTS OF VANADIUM IN THE CNS AT DIFFERENT TIME POINTS – PRELIMINARY RESULTS IN RATS *M.L. Pinto* →
- 73** KETAMINE ADMINISTRATION AT THE 1-4 SOMITES STAGE ZEBRAFISH DOES NOT ALTER THE DISTRIBUTION PATTERN OF SEROTONIN 5-HT-2B RECEPTORS IN ADULT ANIMALS *M.L. Pinto* →
- 76** PATHOGENESIS OF INTRANASAL INOCULATION OF RIFT VALLEY FEVER VIRUS IN THE FERRET *A.L. Schlachter* →
- 103** TREG-ABLATED FOXP3DTR MICE ARE A MODEL OF INFLAMMATORY MYOPATHY AND AUTOIMMUNE MYOCARDITIS *F. Prisco* →
- 106** SIGNALLING OF THE C-TYPE LECTIN RECEPTOR CLEC12A RESTRAINS PROTECTIVE IMMUNITY DURING ACUTE THEILER'S MURINE ENCEPHALOMYELITIS VIRUS INFECTION *M.K. Ameen* →
- 109** CHARACTERIZATION OF DORSAL ROOT GANGLIA OF GOLDEN SYRIAN HAMSTERS (MESOCRICETUS AURATUS) IN A PHYSIOLOGICAL AND POTENTIAL PATHOLOGICAL STATE *I. Zdora* →
- 111** UNEXPECTED HISTOPATHOLOGICAL FINDINGS IN SELECTED PRE-CLINICAL MEDICAL DEVICE STUDIES *P. Ortega* →
- 119** REFINEMENT OF MICRONEEDLES APPLICATION – A COMPARATIVE STUDY REGARDING SPECIES VARIATION IN SKIN HISTOLOGY *M.L. Pinto* →
- 121** EFFECTS OF KETAMINE ADMINISTRATION ON THE EXPRESSION OF SOX 2 IN THE ZEBRAFISH CNS *M.L. Pinto* →
- 124** ASSESSING THE IN VIVO EFFECTS OF ALOYSIA CITRODORA EXTRACT: DATA FROM K14-HPV16 TRANSGENIC MICE *H. Vala* →
- 141** HERPES SIMPLEX VIRUS TYPE 1 (HSV-1) INDUCED KERATITIS: NANOPARTICLES AND ANTIVIRAL PEPTIDES AS A NOVEL TOPICAL TREATMENT *I. Ruedas-torres* →
- 165** POST-MORTEM FINDINGS IN NEONATAL C57BL/6J PUPS *S. Capas-Peneda* →
- 202** AI-DRIVEN QUANTIFICATION OF CRYPTOSPORIDIUM SPP. IN THE INTESTINE OF INFANT *C. Goepfert* →
- 207** A NOVEL SARS-COV-2 MODIFIED LIVE VACCINE WITH AN OPTIMIZED SAFETY PROFILE INDUCES STERILE IMMUNITY IN SYRIAN HAMSTERS *A. Breithaupt* →



Poster Abstracts

Veterinary Pathology

EXOTICS, WILDLIFE AND NON-HUMAN PRIMATES

- 7** PCR-CONFIRMED ENTAMOEBA INVADENS-ASSOCIATED HEPATOCOLITIS IN 3 CO-HOUSED HOME'S HINGEBACK TORTOISES (KINIXYS HOMEANA) *A.F. Rich* →
- 28** FIRST ISOLATION OF STAPHYLOCOCCUS PSEUDINTERMEDIUS IN A CASE OF PYOMETRA IN A RED FOX (VULPES VULPES) *S. Roels* →
- 29** TESTICULAR DEGENERATION DUE TO SUSPECT CHRONIC THEOBROMINE POISONING IN TWO RESCUED COATIS (NASUA SPP.) *E. Correa dos Santos* →
- 41** CRYPTOSPORIDIUM ANDERSONI ASSOCIATED PROLIFERATIVE ABOMASITIS IN A ROAN ANTELOPE (HIPPOTRAGUS EQUINUS) *S. Fingerhood* →
- 47** INTRAABDOMINAL SOFT TISSUE SARCOMA IN AN ELDERLY CALIFORNIA SEA LION FROM A ZOO *I.C. šoštarčić-Zuckermann* →
- 51** OVARIAN TERATOMA IN A FREE RANGING ROE DEER (CAPREOLUS CAPREOLUS) *E. Brambilla* →
- 60** MULTICENTRIC CUTANEOUS HISTIOCYTIC PROLIFERATION RESEMBLING LANGERHANS CELL HISTIOCYTOSIS IN A HOWLER MONKEY (ALLOUATA PALLIATA) *A. Reyes-Matute* →
- 74** TRICHOMONOSIS IN WILD BIRDS FROM ENGLAND AND WALES: A RETROSPECTIVE STUDY OF SUBMISSIONS TO THE ANIMAL AND PLANT HEALTH AGENCY (APHA) *C. Guerreiro* →
- 81** TEMPERATURE AFFECTS REPTARENAVIRUS INFECTION AND INCLUSION BODY FORMATION IN A HOMOTYPIC IN VITRO MODEL *U. Hetzel* →
- 102** FATAL SEPTICAEMIC LISTERIOSIS IN A GOLDEN-HANDED TAMARIN (SAGUINUS MIDAS) *P. Carvalho* →
- 123** OCULAR LESIONS IN BIRDS OF PREY IN PORTUGAL – A RETROSPECTIVE STUDY *M.L. Pinto* →
- 127** BOTULISM OUTBREAK IN ASIAN ELEPHANTS: HISTOPATHOLOGICAL FINDINGS AT NECROPSY *P.J. de Andres Gamazo* →
- 135** NEURODEGENERATIVE DISEASE WITH LAFORA BODIES IN AN EMU (DROMAIUS NOVAEHOLLANDIAE) *M.A. Jimenez Martinez* →
- 137** CAUSES OF MORTALITY IN WILD EUROPEAN HEDGEHOG (ERINACEUS EUROPAEUS) POPULATIONS IN ITALY AND SWITZERLAND *I. Prandi* →
- 143** GRANULOMATOUS PNEUMONIA CAUSED BY MYCOBACTERIUM SIMIAE AND NECROULCERATIVE ENTERITIS CAUSED BY ENTAMOEBA SPP IN A PANTHER CHAMELEON (FURCIFER PARDALIS) *E. Martínez Fuentes* →
- 148** UV-LIGHT SKIN DAMAGE IN A CYNOMOLGUS MACAQUE (MACACA FASCICULARIS) *M. Orlandi* →
- 162** PULMONARY ANGIOMATOSIS IN A MEDITERRANEAN STRIPED DOLPHIN *M. Domingo* →
- 184** PATHOLOGICAL FINDINGS ASSOCIATED WITH HIGHLY PATHOGENIC AVIAN INFLUENZA VIRUS (H5N1) INFECTION IN NATURALLY INFECTED FREE-RANGING BIRDS IN BARCELONA ZOO *L. Fuentes* →
- 186** SEPTICAEMIA IN TWO PYGMY MARMOSETS (CEBUELLA PYGMAEA) ASSOCIATED WITH KLEBSIELLA PNEUMONIAE *L. Fuentes* →
- 187** PRIMARY LUNG ADENOCARCINOMA IN A LION (PANTHERA LEO) *R. Pop* →
- 199** NEMATODE INFESTATION IN THREE HARBOUR PORPOISES (PHOCOENA PHOCOENA) ON THE BLACK SEA COAST OF ROMANIA *G. Nicolae* →
- 211** COMPREHENSIVE PATHOLOGICAL ANALYSIS OF NORTHERN WHITE-BREADED HEDGEHOG (ERINACEUS ROUMANICUS): INSIGHTS INTO HEALTH AND DISEASE *E. Gagniuc* →
- 213** ORAL MELANOMA IN A RED FOX (VULPES VULPES) *M.A. Pires* →



Poster Abstracts

Veterinary Pathology

FISH PATHOLOGY

- 57** WILD FISH PARASITES CONTROL IN FISHERY PRODUCTS *P. Ramos* →
- 58** COMPARATIVE PARASITOLOGICAL STUDIES OF CULTURED GILTHEAD SEABREAM, SPARUS AURATA AND EUROPEAN SEABASS, DICENTRARCHUS LABRAX IN PORTUGUESE FISH FARMS *P. Ramos* →
- 209** MICROSCOPIC EXAMINATION OF THE TISSUES FROM WILD BROWN TROUT WITH ULCERATIVE DERMAL NECROSIS SYNDROM (UDN) CAUGHT IN THE SŁUPIA RIVER IN POLAND *M. Reichert* →

FORENSIC MATTERS

- 204** RETROSPECTIVE STUDY OF FORENSIC NECROPSIES PERFORMED AT THE FACULTY OF VETERINARY MEDICINE OF THE UNIVERSITY OF LISBON BETWEEN 2014-2022 *H. Pissarra* →
- 220** FORENSIC ANALYSIS OF FATALITIES WITH SUSPECTED COMPANION ANIMAL CRUELTY INVOLVING TOXIC SUBSTANCES *K. Lee* →
- 221** CURRENT STATUS OF VETERINARY FORENSIC EXAMINATION FOR COMPANION ANIMALS IN KOREA *K. Lee* →



Poster Abstracts

Veterinary Pathology

LIVESTOCK


- 30** FIRST DETECTION OF SYSTEMIC PORCINE CIRCOVIRUS 3 ASSOCIATED DISEASE IN SWITZERLAND *G. Rosato* →
- 42** DELAYED VIRUS CLEARANCE AFTER RECOVERY FROM AFRICAN SWINE FEVER - A CHALLENGE FOR DISEASE CONTROL AND MONITORING *K. Mehinagic* →
- 46** TORQUE TENO SUS VIRUS: AN INNOCENT BYSTANDER OR A TRUE EMERGING VIRUS PATHOGEN IN SWINE FARMS? *M. Polinas* →
- 49** INTRALESIONAL NON-ACID-FAST MYCOBACTERIUM BOVIS PHENOTYPES IN THE LYMPH NODES OF NATURALLY-INFECTED CATTLE *E. Brambilla* →
- 64** DISCOVERY OF A NOVEL PORCINE BASTROVIRUS ASSOCIATED WITH NON-SUPPURATIVE ENCEPHALITIS IN PIGS *C. Gurtner* →
- 94** STRAIN DIVERSITY IN CAPRINE PARATUBERCULOSIS - CORRELATION OF MYCOBACTERIUM AVIUM SSP. PARATUBERCULOSIS GENOTYPES WITH MORPHOLOGICAL LESIONS *F. Seehusen* →
- 96** INFLAMMATORY CELL PHENOTYPING AND EPITHELIAL PROLIFERATION IN PORCINE LAWSONIA INTRACELLULARIS INFECTION *F. Seehusen* →
- 97** EVALUATION OF TWO RECOMBINANT VIRAL-VECTORED VACCINES AGAINST ORF VIRUS IN SHEEP *Á. Gómez* →
- 100** PINNAL NECROHAEMORRHAGIC DERMATITIS WITH VASCULITIS AND INTRALESIONAL BACTERIA IN RABBITS *G. De Zan* →
- 105** SWINE CONJUNCTIVITIS DUE TO THE NOVEL SPECIES MYCOPLASMA SP.1654_15 IN ITALY *G. De Zan* →
- 120** ANTEMORTEM DIAGNOSIS OF CAPRINE PARATUBERCULOSIS BY FAECAL PCR IN RELATION TO HISTOPATHOLOGICAL LESIONS *E. Párraga-ros* →
- 128** ALPACA PATHOLOGY IN IRELAND: 13 YEARS OF SURVEILLANCE *S.A. Mignacca* →
- 131** DIFFERENTIAL DIAGNOSIS OF ACUTE POST-VACCINAL MENINGOENCEPHALITIS IN SHEEP (ACUTE PHASE OVINE ASIA SYNDROME) *N. Calvo-sánchez* →
- 140** IMPACT OF SWINE ENTERIC CORONAVIRUSES IN THE INTESTINAL BARRIER: A HISTOPATHOLOGICAL AND IMMUNOHISTOCHEMICAL APPROACH *I. Ruedas Torres* →
- 180** IS ALUMINIUM REPLACEABLE IN VACCINES? A SHEEP MODEL FOR NEW BIODEGRADABLE VACCINE ADJUVANTS *E. Pérez* →
- 196** HISTOPATHOLOGICAL ASSESSMENT OF THE INTESTINAL BARRIER IN BROILERS TREATED WITH A PHYTOGENIC OREGANO RICH ESSENTIAL OIL AND CHALLENGED WITH EIMERIA SPP *I. Stylianakis* →
- 218** COMPARATIVE STUDY OF GROSS LESIONS IN PIGS INOCULATED WITH A GLAESSERELLA PARASUIS TBPBY167A MUTANT-BASED VACCINE AND CHALLENGED WITH SPANISH CLINICAL ISOLATES OF G. PARASUIS *A. González Fernández* →

Poster Abstracts

Veterinary Pathology

MISCELLANEOUS

- 3** CONGENITAL IDIOPATHIC MEGAESOPHAGUS IN A 5 WEEK OLD FEMALE GORDON SETTER PUPPY *C.B. Becker* →
- 11** THE PRESENCE OF THYMUS DETECTABLE AT NECROPSY IN ADULT CATS WITH HYPERTROPHIC CARDIOMYOPATHY *I. Dolka* →
- 43** NECROTIZING MENINGOENCEPHALITIS IN A MALTESE DOG *S. Nešić* →
- 72** FIRST PATHOLOGICAL REPORT OF SUCCESSFUL transcatheter PULMONARY VALVE IMPLANTATION IN A CLIENT-OWNED DOG *G. Terrade* →
- 75** STENOTIC NASOPHARYNGEAL DYSGENESIS AND SUSPECT MUSCULAR DYSTROPHY IN A JACK RUSSELL TERRIER *S. Degl'innocenti* →
- 87** EVALUATION OF PROCALCITONIN IMMUNOHISTOCHEMISTRY AS A POST-POSTMORTEM DIAGNOSTIC MARKER FOR SEPSIS IN DOGS *B. de Jonge* →
- 90** SEGMENTAL CAUDAL VENA CAVA ANEURYSM WITH THROMBOSIS IN A ONE-YEAR-OLD BRACCO ITALIANO DOG (CANIS LUPUS FAMILIARIS) *M. Pereira* →
- 108** CHRONIC PROGRESSIVE LYMPHOEDEMA AND CHORIOPTIC MANGE: COINCIDENTAL COPIES OR CAPTIVATING CONNECTIONS? *M. Brys* →
- 115** IN DONKEY, ARE UTERINE AND BLOOD EOSINOPHILS ASSOCIATED? *A. Radar Chafirovitch* →
- 132** FELINE HYPERTROPHIC CARDIOMYOPATHY: PHENOTYPICAL AND FUNCTIONAL CHANGES IN CARDIOMYOCYTES *A. Kipar* →
- 136** OVARIOHYSTERECTOMY AS A POTENTIAL TRIGGER FOR ACQUIRED SKIN FRAGILITY SYNDROME IN A JUVENILE CAT. *V. Castiglioni* →
- 152** BILATERAL GRANULOMATOUS AND NECROTIZING PANOPHTHALMITIS OCCURRING AFTER VACCINATION IN A DOG *C. Naranjo Freixa* →
- 166** LEFT VENTRICULAR APICAL DIVERTICULUM WITH AORTIC THROMBOEMBOLISM IN A CAT *I. Constantin* →
- 168** MECONIUM ASPIRATION SYNDROME AS INDICATOR OF VITALITY AND PERINATAL ILLNESS STATUS IN FOALS *R.E. Tiu* →
- 183** HISTOLOGICAL AND IMMUNOHISTOCHEMICAL CHARACTERIZATION OF THE DONKEY (EQUUS ASINUS) MAMMARY GLAND *A. Gama* →
- 201** VANIN-1 IS EXPRESSED IN THE AIRWAY EPITHELIUM OF HORSES AND HAS A HIGHER ABUNDANCE IN THE MUCUS OF HORSES WITH SEVERE EQUINE ASTHMA COMPARED TO HEALTHY HORSES *K. Landmann* →





Poster Abstracts

Veterinary Pathology

MISCELLANEOUS INFECTIOUS DISEASE

- 20** COMPLICATIONS ENCOUNTERED IN LETHAL EUROPEAN BABESIOSIS *D. Huber* →
- 92** UNUSUAL PATHOLOGICAL FINDINGS IN A HORSE INFECTED WITH TAPEWORM ANOPELOCEPHALA PERFOLIATA *D. Gorbacevska* →
- 153** DOWN-REGULATION OF THE MICROBICIDAL PROFILE OF M1 MACROPHAGES BY ENCEPHALITOOZON CUNICULI *J.G. Xavier* →
- 154** CROTOXIN MODULATES THE M1 PROFILE OF MACROPHAGES INFECTED WITH ENCEPHALITOOZON CUNICULI *J.G. Xavier* →
- 182** INTERSTITIAL PNEUMONIA ASSOCIATED WITH EHV-5 IN THREE ADULT DONKEYS: PATHOLOGICAL AND MOLECULAR FINDINGS OF THE FIRST CASES IN ROMANIA *D.L. Hodor* →
- 189** MASS SPECTROMETRY IMAGING (MALDI-MSI) AS A MOLECULAR HISTOLOGY APPLICATION FOR CHARACTERIZING PULMONARY LESIONS CAUSED BY PRRSV-1 STRAINS OF DIFFERENT VIRULENCE *J. Sánchez-carvajal* →
- 206** CHARACTERIZATION OF AQUAPORIN-4 EXPRESSION IN THE BRAINS OF DOGS WITH CANINE LEISHMANIASIS *G.F. Machado* →

NEW METHODS, NEW TECHNOLOGY, TEACHING

- 80** A SURVEY OF THE ECVP MEMBERSHIP ON KNOWLEDGE, ATTITUDES, AND ACCESS TO NEW TECHNOLOGIES IN VETERINARY PATHOLOGY *J. Williams* →
- 82** IMPACT OF LONG AND SHORT TERM CRYOPRESERVATION ON INTACTNESS OF PRECISION CUT LUNG SLICES *J. Krüger* →
- 193** A BIO-INFORMATIC INVESTIGATION OF CATS' SUSCEPTIBILITY TO CORONAVIRUSES-DERIVING EPITOPES *D. De Biase* →
- 210** COMPARISON OF DIGITAL COUNTING METHODS FOR KI67 STAINED MAST CELL TUMORS *C. Krudewig* →



Poster Abstracts

Veterinary Pathology

TUMOUR PATHOLOGY

- 2** FATAL RHABDOMYOSARCOMA IN A ONE-YEAR-OLD DOG: A CASE REPORT *S. Turchetto* →
- 6** GENE EXPRESSION PROFILING ON FORMALIN-FIXED, PARAFFIN-EMBEDDED (FFPE) CANINE TUMOUR TISSUE - HOW DO LEXOGEN'S QUANTSEQ 3' AND NANOSTRING'S NCOUNTER COMPARE? *A.F.H. Haake* →
- 8** TOPOISOMERASE II ALPHA IMMUNOEXPRESSION AS A POTENTIAL PREDICTOR OF ANTHRACYCLINE CHEMOTHERAPY IN CATS WITH INJECTION-SITE SARCOMA *W. Topuszyński* →
- 13** INTERSPECIES SIMILARITIES BETWEEN CANINE AND HUMAN MAMMARY CANCER *M. Levkut* →
- 14** COMPARISON OF IMMUNOHISTOCHEMICAL EXPRESSION OF CYCLOOXYGENASE-2 (COX-2) BETWEEN CANINE AND EQUINE MELANOMAS *J. Prada* →
- 19** CLINICAL AND PATHOLOGICAL FEATURES AND OUTCOME OF A HOOF MELANOMA IN AN ANDALUSIAN BAY GELDING *F. Bulnes* →
- 21** DEVELOPMENT OF A RADIORESISTANT CANINE GLIOMA CELL LINE *R.F. Strefezzi* →
- 23** SIGNET-RING CARCINOMA IN AN ILE-DE-FRANCE EWE *N. Caliskan* →
- 25** EXPRESSION OF MATRIX METALLOPROTEINASES -2, -9, -13, -14 IN CANINE MAMMARY CARCINOMA *A.S. Pasca* →
- 33** RETROSPECTIVE EPIDEMIOLOGICAL ANALYSIS OF CANINE MAST CELL TUMOURS SUGGESTS AGE AND BREED AS RISK FACTORS *J. Catarino* →
- 38** AUTOPHAGY MARKERS IN CANINE MAST CELL TUMOURS *R.F. Strefezzi* →
- 52** DECORIN EXPRESSION IN INFLAMMATORY AND NON-INFLAMMATORY CANINE MAMMARY CARCINOMAS *B.A. Gouveia* →
- 54** A RARE CASE OF ILEOCECAL MALIGNANT PERIPHERAL NERVE SHEATH TUMOUR IN A CAT *H. Fattahian* →
- 55** POORLY DIFFERENTIATED CERVICAL RHABDOMYOSARCOMA IN AN ADULT DOG *H. Fattahian* →
- 61** DETECTION OF FELINE VIRAL LEUKAEMIA PROVIRUS DNA BY REAL-TIME PCR IN PARAFFIN EMBEDDED TISSUE OF FELINE LYMPHOMAS DIAGNOSED IN A REFERENCE LABORATORY IN MEXICO CITY, FROM 2006 TO 2018 *D. Rivera-colín* →
- 62** SYSTEMIC AMYLOIDOSIS SECONDARY TO SPINDLE CELL SARCOMA IN A PATIENT WITH NEPHROTIC SYNDROME *D. Rivera-colín*
- 63** COMPARATIVE ANALYSIS OF CANINE LYMPHOMAS DIAGNOSED AT THE DEPARTMENT OF VETERINARY PATHOLOGY, FACULTY OF VETERINARY MEDICINE, UNIVERSITY OF ZAGREB *M. Hohšteter* →
- 65** TWO ATYPICAL CASES OF FELINE RESTRICTIVE ORBITAL MYOFIBROBLASTIC SARCOMA (FROMS) INITIALLY PRESENTING AS ORAL MASSES *L. Nordio* →
- 77** UTERINE TORSION IN A RABBIT WITH UTERINE ADENOCARCINOMA *F. Seixas* →
- 84** HISTOLOGICAL CLASSIFICATION AND MOLECULAR CHARACTERIZATION OF FELINE HODGKIN-LIKE LYMPHOMAS (HLL) *S. Dell'aere* →
- 85** LIMITATIONS OF THE CURRENT EQUINE MELANOCYTIC TUMOUR CLASSIFICATION *A. Malá* →
- 88** EXPRESSION OF SOX-10 AND TYRP-1 IN FELINE MELANOMA *M. Orlandi* →
- 91** MIRNA PROFILES IN DOGS WITH SPLENIC ANGIOSARCOMA *C. Zamboni* →
- 99** A CASE OF FELINE GASTROINTESTINAL EOSINOPHILIC SCLEROSING FIBROPLASIA EXTENDING TO THE LIVER *M. Orlandi* →
- 113** TUMOUR IMMUNE MICROENVIRONMENT (TIME) IN BPV1-POSITIVE EQUINE SARCOIDS *L. de Paolis* →



Poster Abstracts

Veterinary Pathology

TUMOUR PATHOLOGY

- 114** EVALUATION OF CANINE AND FELINE TUMOURS IN MOROCCO: RESULTS OF A COUNTRY-WIDE EPIDEMIOLOGIC AND HISTOLOGIC STUDY *N. Laissaoui* →
- 118** TWO DIAGNOSTICALLY CHALLENGING HEMANGIOSARCOMAS IN DOGS GROWING INSIDE BLOOD VESSELS *S. Blatter* →
- 126** DISSEMINATED CUTANEOUS NON-EPIITHELITROPIC B CELL LYMPHOMA ASSOCIATED WITH A FRACTURE SITE IN A CAT *M. Saravia-Castro* →
- 130** INFLAMMATORY INFILTRATE IN THE FELINE MAMMARY GLAND: HEALTHY, NON-NEOPLASTIC, BENIGN AND MALIGNANT LESIONS *J. Rodrigues-Jesus* →
- 134** RETROSPECTIVE STUDY OF SPINDLE CELL TUMOURS IN THE FACE OF CATS *S. Soto* →
- 139** NORTHERN PORTUGUESE DOG LYMPHOMA IMMUNOPHENOTYPIC STUDY *N.R. Lima* →
- 159** CARTILAGE OLIGOMERIC MATRIX PROTEIN (COMP) EXPRESSION IN CANINE OSTEOSARCOMAS AND SPLENIC HAEMANGIOSARCOMAS *B. Passeri* →
- 169** TRANSCRIPOME EVALUATION OF EQUINE SARCOID INFECTED BY BOVINE PAPILLOMAVIRUS TYPE-1 *E. Razzuoli* →
- 172** CHARACTERIZATION OF B7-H3 IMMUNOHISTOCHEMICAL STAINING IN CANINE PRIMARY APPENDICULAR OSTEOSARCOMA *D. Seelig* →
- 173** SECONDARY MULTICENTRIC LARGE B CELL LYMPHOMA DEVELOPMENT AFTER INTESTINAL LARGE T CELL LYMPHOMA IN A DOG *C.C. Kuo* →
- 175** TRIGEMINAL NERVE DESTRUCTION DUE TO ATYPICAL MALIGNANT CHEMODUCTOMA METASTASIS IN A DOG *I. Stylianaki* →
- 176** ADRENAL CAVERNOUS HAEMANGIOMA IN A SHIH-TZU DOG: AN INCIDENTAL FINDING *H. Fattahian* →
- 181** CLINICOPATHOLOGICAL FEATURES OF CANINE "PAEDIATRIC" GLIOMAS *A. Oevermann* →
- 185** UNUSUAL METASTASIS SITE FOR DERMAL MELANOMATOSIS IN A LIPIZZANER MARE *A.A. Dobrin* →
- 188** A CASE OF EQUINE MULTICENTRIC LYMPHOMA: CLINICAL, MICROSCOPICAL AND MOLECULAR FINDINGS *M.C.P.Rocha* →
- 190** METHYLATION ANALYSIS OF LINE-1 ELEMENTS IN CANINE MAST CELL TUMOURS *J.G. Xavier* →
- 191** RELATIONSHIP BETWEEN HISTOLOGICAL PARAMETERS, PROLIFERATIVE INDEX AND THE EXPRESSION OF VIMENTIN AND FASCIN-1 IN PAPILLOMAS AND ORAL SQUAMOUS CELL CARCINOMAS IN DOGS *J.G. Xavier* →
- 194** CLINICAL, ULTRASONOGRAPHIC AND IMMUNOHISTOCHEMICAL STUDY OF DIFFUSE LARGE B CELL LYMPHOMAS IN DOGS *M.C.P.Rocha* →
- 198** RHABDOMYOMATOUS MESENCHYMAL HAMARTOMA IN A DOG *R. Marica* →
- 200** INCIDENCE OF THE MOST FREQUENT CANINE TUMOURS BASED ON THE SWISS CANINE REGISTRY DATA FROM 2008 TO 2020 *E.S. Dhein* →
- 205** INTER-INSTITUTIONAL STUDY REGARDING THE EPIDEMIOLOGY OF GASTROINTESTINAL TUMOURS IN DOGS AND CATS *A. Negoescu* →
- 216** CYTOLOGICAL AND PATHOLOGICAL FINDINGS IN A FELINE CHOROID PLEXUS CARCINOMA *A. Perez-Ecija* →
- 217** RARE AND UNCOMMON MALIGNANT MAMMARY TUMOURS IN DOGS AND CATS: PRELIMINARY RESULTS FROM A PORTUGUESE MULTICENTRIC STUDY *A. Gama* →
- 223** A RARE CASE OF GIANT CELL RICH EXTRASKELETAL OSTEOSARCOMA OF CARDIAC MUSCLE IN A DOG *C. de Meeûs* →

Poster Abstracts

Clinical Pathology



- 4** INCIDENCE OF GENETIC VARIANTS IN SELECTED CANINE CARDIOMYOPATHIES IN SEVERAL BREED *K. Törner* →
- 9** A CASE OF PERICARDIAL EFFUSION ASSOCIATED WITH CANINE LEISHMANIOSIS IN A SAINT BERNARD DOG *C. Rodríguez-Cariño* →
- 10** THE SIGNIFICANCE OF SERUM PROTEOME ANALYSIS IN DIAGNOSIS OF CANINE IDIOPATHIC EPILEPSY *R. Baka* →
- 11** AUTOMATED DIFFERENTIAL CELL COUNT IN BRONCHOALVEOLAR LAVAGE FLUID (BALF) OF WISTAR RATS WITH THE XN1000VET HEMATOLOGY ANALYZER *V. Strauss* →
- 13** REFERENCE INTERVALS AND INFLUENCE OF SAMPLING TECHNIQUE ON CANINE TEG VELOCITY CURVE VARIABLES AND DELTA *A. Gläsel* →
- 16** A STUDY OF TWO ACUTE PHASE PROTEINS IN CATS WITH GINGIVITIS *I. Oikonomidis* →
- 18** PERFORMANCE OF SYSMEX XT, SYSMEX XN-VET AND MANUAL METHODS ON CHICKEN BLOOD: A COMPARISON STUDY *D. Legroux* →
- 22** COMPARISON STUDY OF HEMOGLOBIN VALUES IN BLOOD FROM JUGULAR AND CEPHALIC VEINS IN HEALTHY CATS *R. Moreira* →
- 23** LEUKOCYTE COUNTS IN DOGS WITH ACUTE LEUKAEMIA (223 CASES) *M. Guzera* →
- 24** SUSPECTED PHENOBARBITAL INDUCED THROMBOCYTOPENIA IN A DACHSHUND *R. Mischke* →
- 26** THE VALUE OF CYTOLOGY IN THE DIAGNOSIS OF ENDOMETRITIS IN THE MARE - CORRELATION WITH MICROBIAL CULTURE *S. Branco* →
- 30** INTESTINAL METAPLASIA OF ESOPHAGEAL MUCOSA (BARRETT ESOPHAGUS) IN A CAT *M. Zanetti* →
- 31** VITAMIN D AND ACUTE PHASE PROTEIN EXPRESSION IN DOGS WITH DIFFUSE B-CELL LYMPHOMA: ASSOCIATION WITH CLINICOPATHOLOGICAL PARAMETERS *M. Do Carmo Pereira Rocha* →
- 33** FLOW CYTOMETRIC CD44 AND CD45 EXPRESSION IN NEOPLASTIC AND REACTIVE NON-HEMOPOIETIC CELLS IN CANINE EFFUSIONS *F. Sini* →
- 34** SEQUENCING OF THE SOUTHERN WHITE RHINOCEROS (CERATOTHERIUM SIMUM SIMUM) CARDIAC TROPONIN I GENE AND ANALYTICAL VALIDATION OF A POINT-OF-CARE CARDIAC TROPONIN I IMMUNOASSAY *Y. Rautenbach* →
- 35** URINARY PROTEIN-TO-CREATININE RATIO (UPC) IN THE EUROPEAN HEDGEHOG ERINACEUS EUROPAEUS: CLINICAL USE AND REFERENCE INTERVAL ESTABLISHMENT *E. Ramery* →
- 36** AVIAN MALARIA IN PENGUINS.TWO CASE REPORTS IN AFRICAN PENGUINS (SPHENISCUS DEMERSUS) *M. Attini* →
- 37** A COMPARISON STUDY BETWEEN THE SIEMENS ADVIA 120 AND THE MANUAL METHOD FOR THE DIFFERENTIAL WHITE BLOOD CELL COUNT IN GOATS *T. Tsouloufi* →
- 39** PRESUMED PSEUDO-PELGER-HUËT ANOMALY AND BASOPHILIA IN A DOG SECONDARY TO CHRONIC LYMPHOCYTIC LEUKAEMIA - CASE PRESENTATION *J. Martínez-Caro* →
- 41** GRANULOMATOUS INFLAMMATION IN A TURTLE (TRACHEMYS SCRIPTA ELEGANS) WITH THROMBOPHAGOCYTOSIS AND LEUKOPHAGY IN PERIPHERAL BLOOD *C. Meneses Nava* →
- 42** KI67 INDEXES IN PAIRED CYTOLOGICAL SMEARS AND CELL BLOCKS OF CANINE LYMPHOMA: PRELIMINARY RESULTS *F. Sampaio* →
- 43** INTRODUCTION OF NU.Q® VET CANCER TEST INTO A CLINICAL LABORATORY *S. Klenner-Gastreich* →
- 44** REFERENCE INTERVALS FOR SERUM BIOCHEMISTRY IN ADULT MIRANDA'S DONKEYS *G. Silva* →
- 46** INTRACYTOPLASMIC GRANULES IN BLOOD NEUTROPHILS OF FRENCH BULLDOG: FRIENDS OR FOES? *M. Giraldi* →



Poster Abstracts

Clinical Pathology

- 48** DELTA TOTAL NUCLEATED CELLS ASSESSED VIA SYSMEX XT-2000IV AND SYSMEX XN-1000V ON FELINE EFFUSIONS: COMPARABLE DIAGNOSTIC ACCURACY FOR FELINE INFECTIOUS PERITONITIS *S. Paltrinieri* →
- 50** CANINE MAST CELL TUMOURS: PROGNOSTIC VALUE OF CYTOLOGY GRADING PARAMETERS IN ROUTINE STAINING AND HAEMATOXYLIN-EOSIN RESTAINING *R. Marcos* →
- 51** STABILITY OF MIRANDA'S DONKEY RED BLOOD CELL PARAMETERS AT ROOM AND REFRIGERATED TEMPERATURE AND FIVE PERIODS OF STORAGE WITH A PROCYTE DX HAEMATOLOGY ANALYSER (IDEXX) *G. Silva* →
- 52** ABC BLOOD GROUP SYSTEM IN CATS FROM LUANDA (ANGOLA) - PRELIMINARY STUDY *G. Silva* →
- 54** RECYCLE AND REPURPOSE - USEFULNESS OF IMMUNOHISTOCHEMISTRY ON CELL BLOCKS PREPARED FROM CYTOLOGY SLIDES *R. Noiva* →
- 56** NORMAL CYTOLOGICAL BONE MARROW EXAMS ASSOCIATED TO ALTERED HEMOGRAMS IN CATS: A RETROSPECTIVE STUDY *V. Turinelli* →
- 57** SERIAL MEASUREMENT OF MYELOPEROXIDASE INDEX AND ITS ASSOCIATION WITH OUTCOME IN HOSPITALISED DOGS WITH PARVOVIRAL ENTERITIS: PRELIMINARY RESULTS *T. Tsouloufi* →
- 58** RICKETTSIA CONORII IN DOGS WITH HEMATOLOGICAL DISORDERS IN MARCHE REGION: PRELIMINARY STUDY *S. Mangiaterra* →
- 59** PERIPHERAL BLOOD CELL RATIOS AS PROGNOSTIC FACTORS IN FELINE ALIMENTARY LYMPHOMA - A PRELIMINARY STUDY *J. Fonseca* →
- 62** CYTOLOGICAL BONE MARROW CELL DIFFERENTIAL COUNTS AND MORPHOLOGICAL FINDINGS IN THE COMMON MARMOSET (CALLITHRIX JACCHUS) *M. Defontis* →
- 64** EFFECT OF CHRONIC DISEASES ON CORTISOL LEVELS IN HAIR OF DAIRY GOATS IN INTENSIVE SYSTEM *E. Candanosa-Aranda* →
- 67** RELATION OF DAIRY GOAT CHRONIC DISEASES AND HAIR CORTISOL IN AN INTENSIVE GRAZING PRODUCTION SYSTEM *J. Ortega Cortés* →
- 69** CYTOLOGICAL AND PATHOLOGICAL FINDINGS IN A HORSE WITH HEMOCHROMATOSIS DUE TO CHRONIC IRON OVERLOAD *A. Perez-Ecija* →

Speaker Abstracts Joint Stream

RESIDENT DAY

WEDNESDAY 30 AUGUST 2023 | 09.00-12.30

QUPATH WORKSHOP II - LEARN HOW TO USE OPEN SOURCE SOFTWARE FOR QUANTITATIVE PATHOLOGY & BIOIMAGE ANALYSIS - FOCUS ON AI

Z. Mikulski ¹, R. Klopfeisch ²

¹ *La Jolla Institute for Immunology, La Jolla, United States*

² *Institute of Veterinary Pathology, Freie Universität Berlin, Berlin, Germany*

Lecture Content

To prepare for this hands-on workshop you must visit the link tiny.cc/prepareQuPath to install the software, and download data to your computer. This workshop aims to give participants a better understanding of how to use QuPath for image analysis. We will cover the most common analysis tasks, and teach how to use convenient tools for manual counting and measurements of the length and area of different structures. We will use QuPath's commands for automated cell counts in H&E and immunohistochemistry slides. With the help of machine learning, we will teach the software how to perform object and pixel classification, which is very useful in complex and difficult samples. We will also perform measurements of IHC-stained areas in tissue sections and cytology images. All of these analyses can be easily adapted for immunofluorescence and multiplexed slides. We will teach how QuPath can be used to implement deep-learning workflows, and show can help to improve the reproducibility of image analysis. Attendees will go home with knowledge and workflows that they can adapt to analyze their own tissues and stains.

References

Bankhead P, Loughrey MB, Fernández JA, Dombrowski Y, McArt DG, Dunne PD, McQuaid S, Gray RT, Murray LJ, Coleman HG, James JA, Salto-Tellez M, Hamilton PW. QuPath: Open source software for digital pathology image analysis. *Sci Rep.* 2017 Dec 4;7(1):16878. doi: 10.1038/s41598-017-17204-5. PMID: 29203879; PMCID: PMC5715110.

E-mail zmikulski@lji.org

Speaker Abstracts Joint Stream

RESIDENT DAY

WEDNESDAY 30 AUGUST 2023 | 14.00-17.30

RESEARCH METHODOLOGY II - THE SCIENTIFIC METHOD.THE DESIGN OF CLINICAL STUDIES AND BASIC STATISTICS

L. Peña¹, A. Gama², G. Valdivia¹

¹ Complutense University of Madrid, Madrid, Spain

² CECAV. University of Tras-os-Montes e Alto Douro (UTAD), Vila Real, Portugal

Lecture Content

The Scientific Method (SM) is a problem-solving approach, used in several areas of scientific research, contributing with new information through an ethical study design, in an iterative process of observation and inquiry. Although researchers ask different questions and perform different tests, the same approach is used to find answers that are valid and supported by evidence. SM is characterized by several steps: 1. make an observation or observations; 2. form a hypothesis; 3. test the hypothesis and predictions in an experiment that can be reproduced; 4. analyze the data and draw conclusions, accepting or rejecting the hypothesis or modifying the hypothesis, if necessary; 5. reproduce the experiment until there are no discrepancies between observations and theory. Besides addressing the SM concept, objectives and characteristics, in this presentation the SM historical evolution will be briefly reviewed. Research can be classified in fundamental/basic research and applied research, using quantitative, qualitative or mixed methodological strategies. The scientific method is not completed if the results are not diffused. Ultimately, research results are submitted for publication, to diffuse knowledge in the scientific community. A rigorous peer-review process will ensure an independent assessment of the research by independent field experts, being an important form of quality control for research. In Veterinary Medicine, applied research is usually clinical research. The methodology used in clinical research involves epidemiological studies that are approaches used to study and analyze patterns of disease and health in populations. In this presentation, the different methods and how to design clinical studies will be reviewed. These methods are employed to investigate the distribution, determinants, and outcomes of diseases, as well as to identify and evaluate interventions for disease prevention and control. Epidemiological research often involves collecting and analyzing data from various sources, such as surveys, medical records, and public health databases. Some common epidemiological methods include: A) Observational Studies: These studies observe individuals in their natural settings and collect data on different characteristics, exposure and outcome variables. Examples include cohort studies, case-control studies, and cross-sectional studies. B) Experimental Studies: These studies involve the intervention of the researcher to determine its effect on the animal outcome. Randomized controlled trials are the gold standard for evaluating interventions, where participants are randomly assigned to either an experimental group receiving the intervention or a control group receiving a placebo or standard treatment. In clinical research, statistical methods are used to examine the relationship between patient variables (such as risk factors or interventions) and health outcomes, such as the occurrence of diseases or mortality rates. In the last part of the presentation, a wide array of vital statistical topics will be covered. Starting with the basics, concepts like mean, median, mode, standard deviation, and variance will be introduced, along with an explanation of the difference between discrete and continuous variables. This basis is fundamental for the application of statistical methods in biomedical research. Next, an exploration into probability distributions will be conducted, with an emphasis on the normal distribution. The statistical hypotheses, together with the significance level (p-value) and statistical power, concepts that are key in evaluating statistical evidence and making informed decisions in research, will be exposed. Several common statistical tests, such as the Student's t-test, chi-square test, and analysis of variance (ANOVA), will be introduced. An understanding of when and how to use each test, as well as how to interpret the results accurately, will be facilitated. One crucial aspect of any study, determining the sample size for different types of studies, will be addressed next with an emphasis on the influence of statistical power. Key concepts of survival analysis, such as the survival function and hazard risk, will be outlined and their use in clinical studies will be demonstrated. Common data modeling methods like linear and logistic regression will be covered and their application in clinical research will be discussed. Additionally, common mistakes in statistics will be highlighted and tips on how to avoid them will be provided. Advice on the accurate interpretation of statistical results and effective communication strategies will also be shared. Guidance for tackling the 'comprehensive pathology' section of the ECVF/ECVCP examination will also be provided. Strategies for answering exam questions that involve statistics will be shared. By the end of this presentation, it is expected that attendees will have integrated their pathology expertise with a solid understanding of applied statistics, boosting their confidence in facing the exam.

E-mail laurape@ucm.es

Speaker Abstracts Joint Stream

THURSDAY 31 AUGUST | 09.00-09.45

SAND FLY BORNE-DISEASES IN EUROPE - EPIDEMIOLOGICAL OVERVIEW AND POTENTIAL TRIGGERS FOR THEIR EMERGENCE AND RE-EMERGENCE

C. Maia

Instituto de Higiene e Medicina Tropical, Universidade NOVA de Lisboa, Lisbon, Portugal

Lecture Content

Phlebotomine sand flies are vectors of human and animal pathogens, including the parasites *Leishmania* and phleboviruses, some of which cause deadly diseases when left untreated. In Europe, visceral zoonotic leishmaniasis caused by *L. infantum*, is endemic in southern countries, with dogs as reservoir hosts while anthroponotic cutaneous leishmaniasis, caused by *L. tropica*, occurs sporadically in Greece. In addition, autochthonous visceral and cutaneous leishmaniasis caused by *L. donovani* were recently reported in Cyprus. Most phleboviruses cause asymptomatic infections or flu-like syndromes in humans, although *Toscana phlebovirus* can cause meningitis and encephalitis.

These neglected pathogens are likely to (re)-emerge due to ongoing climate changes and other aspects of globalization posing a growing threat to public and animal health.

This talk will give an overview of the main epidemiological characteristics of the pathogens transmitted by sand flies in Europe and the potential triggers involved in their emergence and re-emergence.

Reference

- Ayhan N, Charrel R. *Sandfly-Borne Viruses of Demonstrated/Relevant Medical Importance*. In: Vectors and Vector-Borne Zoonotic Diseases. S. Savić (Ed.), IntechOpen. 2018; 1: 22.
- Berriatua E, Jumakanova Z, Muñoz C, Ortuño M, Pérez-Cutillas P, Conceição C, Maia C, Pereira A, Rocha R, Özbel Y, Töz S, Baneth G, Gasimov E, Van der Stede Y, Torres G, Gossner C. *Surveillance, prevention and control of leishmaniasis in the European Union and its neighbouring countries*. Stockholm: European Centre for Disease Prevention and Control; 2022.
- Berriatua E, Maia C, Conceição C, Özbel Y, Seray Töz S, Baneth G, Pérez-Cutillas P, Ortuño M, Muñoz C, Jumakanova Z, Pereira A, Rocha R, Monge-Maillo B, Gasimov E, Stede Y, Torres G, Gossner C. *Leishmaniasis in European Union and neighboring countries*. Emerging Infectious Diseases; 2021. 27; 1723-1727.
- Dvorak V, Shaw J, Volf P. *Parasite biology: the vectors*. In: *Leishmaniasis: Old Neglected Tropical Diseases*. F. Bruschi, L. Gradoni (Eds.), Springer Verlag. Viena, Austria. 2018; 31–77.
- Gradoni L. *A brief introduction to leishmaniasis epidemiology*. In: *Leishmaniasis: Old Neglected Tropical Diseases*. F. Bruschi, L. Gradoni (Eds.), Springer Verlag. Viena, Austria. 2018; 1–14.
- Maia C, Dantas-Torres F, Campino L. *Parasite biology: the reservoir hosts*. In: *Leishmaniasis: Old Neglected Tropical Diseases*. F. Bruschi, L. Gradoni (Eds.), Springer Verlag. Viena, Austria. 2018; 79–106.
- Maia C, Depaquit J. *Can Sergentomyia (Diptera, Psychodidae) play a role in the transmission of mammal-infecting Leishmania?* Parasite. 2016; 23: 55.
- Maroli M, Feliciangeli M, Bichaud L, Charrel R, Gradoni L. *Phlebotomine sand flies and the spreading of leishmaniasis and other diseases of public health concern*. Med Vet Entomol. 2013; 27: 123-147.
- Moriconi M, Rugna G, Calzolari M, Bellini R, Albieri A, Angelini P, Cagarelli R, Landini M, Charrel R, Varani S. *Phlebotomine sand fly-borne pathogens in the Mediterranean Basin: human leishmaniasis and phlebovirus infections*. PLoS Negl Trop Dis. 2017; 11: e0005660.
- Pereira A, Maia C. *Leishmania infection in cats and feline leishmaniosis: an updated review with a proposal of a diagnosis algorithm and prevention guidelines*. Current Research in Parasitology & Vector-Borne Diseases. 2021; 1: 100035.

E-mail carlamaia@ihmt.unl.pt

Speaker Abstracts Joint Stream

THURSDAY 31 AUGUST | 09.00-10.30

SCIENTIFIC POSTER. HOW DO I DO IT? VISUAL COMMUNICATION STRATEGIES FOR SCIENTIFIC POSTERS

D. Vieira-da-Silva

ID+/University of Porto, Porto, Portugal

Introduction: This document presents the contents of the workshop "Scientific Poster. How do I do it?" highlighting the importance of scientific posters and the engaging and interactive learning opportunities created for the participants. Regardless of being a powerful tool to communicate science through different audiences, recent literature shows the need to improve conference poster presentations to maintain relevance and impact (Rowe & Ilic). Based on our practice, crossing with the literature on the best practices (Barker & Phillips; Carneiro; Johns), we defined a workflow to produce scientific posters and pointed out a set of Design Principles for better visual communication.

Workflow to Produce a Scientific Poster

- Initial planning: defining a key message and contributors.
- Searching for additional information: Studying/defining constraints, such as the organiser's requirements.
- Defining the content: Gathering all the material - text and media - necessary to convey the information. IMRAD format influences most conference posters to structure information by sections (Faulkes). However, other efficient formats are emerging from different scientific areas (Alvelos et al.; Atherton et al.; Morrison).
- Text preparation: Refining and editing the text to be simple and concise, with maximum impact for viewers, avoiding large blocks of solid text.
- Layout planning: Sketching a small-scale plan before creating it on a computer, previewing the area needed for each element and the position of images and text.
- Production: The choice of colours, paper type, and printing formats should consider the budget and technical constraints for printing the final poster; prototypes (test prints in small sizes) are recommended during the preparation of the final poster.

Design Principles for better visual communication

- Understanding the audience: Tailoring content and design to appeal to diverse age groups, educational backgrounds, and scientific literacy levels is vital to effective communication. Visual elements can enhance the overall impact.
- Format: Consider the overall format and orientation of the poster, such as portrait or landscape, to ensure it complements the content and fits the intended display space. Design the poster at its final size and high resolution.
- Grid: Implement a grid system to create visual harmony and organise the elements of the poster.
- Typography: Choose suitable, legible fonts that improve readability. Use hierarchy to highlight key points, headings and subheadings. Make sure font styles and sizes are consistent throughout the poster.
- Colour: Select a colour palette that is in keeping with the research theme and evokes the desired emotions. Use colours strategically to differentiate sections, highlight important information and create visual interest. Maintain a balanced colour scheme to avoid overwhelming the viewer.
- Photography: Incorporate high-quality images and photographs that support and enhance the content. Use visual elements that are relevant and visually appealing. Ensure images are appropriately sized and optimised for print or digital presentation.
- Infographics: Use infographics, such as graphs, charts, diagrams or illustrations when needed, to visually represent complex data and concepts. Simplify information to improve understanding and engagement.

Conclusion

Poster presentations at conferences are among the most common forms of scientific communication. The workshop aims to empower researchers and science communicators to recognise the importance of designing an accurate and communicable scientific poster by adopting a hands-on methodology that combines theoretical knowledge, collaborative exercises, and practical applications.

Speaker Abstracts Joint Stream

THURSDAY 31 AUGUST | 09.45-10.30

EXPLORING THE POTENTIAL OF NATURAL LANGUAGE PROCESSING IN VETERINARY PATHOLOGY: APPLICATIONS AND INSIGHTS FROM CHATGPT AND BING AI

L. Stimmer

Paris Brain Institute, Paris, France

Lecture Content

Natural language processing (NLP) models, such as ChatGPT and Bing AI, are powerful tools that can generate and understand natural language texts. In this talk, we discuss the use of these models in veterinary pathology, and how they can enhance medical education, histopathological diagnosis, and biomedical research.

We present several use cases based on the ECVF exam questions, testing the models' ability to work with different texts related to veterinary pathology, to reason about histopathological descriptions and diagnoses, and to interpret data from short research studies. We show that ChatGPT and Bing AI can perform remarkably well on some parts of the ECVF examination, including Veterinary and General pathology as well as Comprehensive pathology, which requires complex and specific reasoning skills. We also demonstrate that they can provide accurate and detailed histopathology reports and suggest relevant literature for further investigation.

However, would an AI algorithm be a good veterinary pathologist? The recent development of generative technologies raises important ethical questions about the responsibility of the pathologist using these tools for education, diagnostic or scientific writing, especially considering their limitations in terms of validity, reliability, and transparency.

We conclude that NLP models have the potential to transform veterinary pathology and the way the pathologist work, but it is important for users to understand their limitations and critically evaluate the information they provide.

Reference

Dave, T., Athaluri, S.A., Singh, S., *ChatGPT in medicine: an overview of its applications, advantages, limitations, future prospects, and ethical considerations*. Front Artif Intell 6, 2023.1169595.

Huang, J., Tan, M., *The role of ChatGPT in scientific communication: writing better scientific review articles*. Am J Cancer Res 13, 2023. 1148-1154.

van Dis EAM, Bollen J, Zuidema W, van Rooij R, Bockting CL. *ChatGPT: five priorities for research*. Nature. 2023 Feb;614(7947):224-226.

Stokel-Walker C. *ChatGPT listed as author on research papers: many scientists disapprove*. Nature. 2023 Jan;613(7945):620-621.

E-mail lev.stimmer@inserm.fr

Speaker Abstracts Joint Stream

THURSDAY 31 AUGUST | 11.00-12.30

THE VISUAL ABSTRACT. WHAT IS IT AND HOW DO I DO IT?

A. Baptista

Ana Rita Baptista, Lisbon, Portugal

Lecture Content

What are Visual Abstracts?

Why are they crucial when publishing scientific papers?

The Visual Abstract is a visual summary of a research article's question, methods, and major findings. The goal of a visual abstract is to simplify complex methodologies and summarize key outcomes of a study to allow rapid visualization, interpretation, retention, and sharing.

The Visual Abstract filters out nuances and details to let the broad strokes of a study emerge.¹

First introduced in 2016 by Dr. Andrew Ibrahim, the Creative Director of Annals of Surgery, a Visual Abstract transforms scientific information into a graphic format. It is a visual summary of information contained in the abstract of a manuscript.¹

Visual abstracts capitalize on humans' inherent ability to rapidly process and retain visual as opposed to textual information. In a digital age, in which consumers of information are faced with an exponentially growing body of scientific research, the main role of visual abstracts is to help the reader preview the study to decide whether or not to pursue the full article.²

The Visual Abstract is similar to the "trailer" of a movie. It does not substitute the reading of the article and does not contain all the details. Its goal is to inform the potential reader of the key findings in an article to help them decide if they want to proceed in reading the entire article.

Although they have a number of uses, visual abstracts can also be used to promote research articles on social media.³

Summary of the lecture content

Why are Visual Abstracts crucial to publish scientific papers?

Components of an effective Visual Abstract

Creating a Visual Abstract

Where to find the right images? Copyright issues.

Design Guidelines for a strong and effective Visual Abstract

Common Visual Abstracts Mistakes and How to avoid them

Journals implementation of the Visual Abstract

Disseminating your Visual Abstract on social media

The future of Visual Abstracts

Reference

- Ramos E, Concepcion B. *Visual Abstracts: Redesigning the Landscape of Research Dissemination*. *Visual abstracts*. 2020, 40(3), 291–297
- Oska S, Lerma E, Topf J. *A Picture Is Worth a Thousand Views: A Triple Crossover Trial of Visual Abstracts to Examine Their Impact on Research Dissemination*. *J Med Internet Res*. 2020, 22(12): e22327.
- Ibrahim, AM. *Seeing is believing: Using visual abstracts to disseminate scientific research*. *The American Journal of Gastroenterology*. 2018, 113(4), 459–461.

E-mail arbaptista@gmail.com

Speaker Abstracts Joint Stream

THURSDAY 31 AUGUST | 14.00-14.45

DIGITAL GROSS PHOTOGRAPHY IN ANATOMIC PATHOLOGY

L Luján

University of Zaragoza, Zaragoza, Spain

Lecture Content

Gross photography represents an enormous challenge for everyone working in veterinary pathology, as we very often need to present macroscopic images in different scenarios. To convince our audiences, these images need to be not just correct, they need to be excellent. This is a two-step process: capturing the image in the best possible way and editing it to achieve an excellent result. For capturing images, you don't need to be an expert on photography or to have a deep knowledge on how cameras work, you only need to have a decent photographic equipment, an interesting lesion and patience: it will take time but the final product will have been worth it. Keep your final product always in mind, how do you want it to be. During this first phase, you will prepare the piece: cleaning, removing non-interesting tissues, placing it in an appropriate background (almost invariably black) and use a scale that do not overlap the specimen. Then, the best possible illumination needs to be selected, either natural light, a flash or using a source of constant light together with a tripod. Light reflected on the surface of the tissue must be avoided as much as possible. The piece must be centered in the picture, and its borders must be as close as possible to the frame, without trespassing it: zoom in as far as possible. Orient the specimen and take pictures of the tissue and its sections. Focus the tissue with care; in the case of two pieces in the same image that do not focus together, elevate one piece with paper. Alternatively, take two pictures focusing each one in one of the pieces and combine them using the photo editor. Make several images of the same topic, to select the best once at the computer. Use over and underexposure, you never know which will be the best option and certainly one never have time to check images at the postmortem floor. Some people believe this is it: you have your image; end of path. This could be right when we used photographic slides during the last century. However, all images to be presented today need photo editing and this is precisely the second phase of this process. Computer software edition is an extremely useful tool that will transform your (already good) image into an excellent, sometimes breath-taking, image. Photo editors have almost infinite tools and resources but they are also very complex to use. Luckily, this is of no importance for the veterinary anatomic pathologist: only a few steps are needed to improve an (already good) image and they are basically always the same; you only need to put them to work. First one is background subtraction. Even if you have prepared the tissue thoroughly, your background will be plenty of small imperfections that will be very visible when on a screen. The only solution is to remove the original background and place a homogenous, non-distracting color. Second, your scale must be substituted for a simple box and what size it represents in cm. Third, the tonal range of your tissue must be adjusted with the "levels" option in the photo editor. This will allow to correct the tonal range and color balance of your image. This step is crucial in gross pathology but it is more than essential if you are working with microscopic slides. At this stage, your gross tissue will be isolated in the image and you will be free of moving it up and down, centering it or making it bigger or smaller. Finally, you can use the sharpening tool and adjust brightness and contrast, to improve the real colors of your image. At this stage you should compare your original picture with your final product: you will not believe your eyes. Of course, this two-step process has ethic rules: you can only change the presentation of your tissue without modifying colors, tissue surfaces or cheating in any way by using tools from the photo editor. Excellent review publications on gross veterinary pathology photography and ethics we all need to follow can be found in references 1, 2 and 3.

Reference

¹ Crome, *Avoiding Twisted Pixels: Ethical Guidelines for the Appropriate Use and Manipulation of Scientific Digital Images*, *Sci. Eng. Ethics*, 2010, 16;639-667.

² Song, *Lights, Camera, CANCER: Principles of Macroscopic (Gross) Photography for Pathology Specimens*, *AJSP: Reviews & Reports*, 2020, 25;181-183.

³ Rampy, Eric F. Glassy E. F., *Pathology Gross Photography: The Beginning of Digital Pathology*, *Clin. Lab. Med.*, 2016, 36;67-87.

E-mail lluis.lujan@unizar.es

Speaker Abstracts Veterinary Pathology

THURSDAY 31 AUGUST | 14.00-15.30

PARASITIC DISEASES OF RELEVANCE IN AQUACULTURE AND WILD FISH IN EUROPE AND THE IMPACT OF GLOBAL WARMING

H. Schmidt-Posthaus, R. Bermudez Pose

Institute for Fish and Wildlife Health, University of Bern, Bern, Switzerland

Lecture Content

Water temperature, among the most important abiotic parameters controlling the life of aquatic species, is predicted to continuously rise as the impact of climate change. Increases in temperature may induce stress in aquaculture and wild fish species, negatively affecting growth and health status. On the other hand, aquaculture and sustainable extractive fishing are key to respond to the growing global demand for healthy and nutritious aquatic products (Global production of aquatic animals was estimated at 178 million tons in 2020), especially in the view of continuously declining wild fish populations worldwide. However, the intensification and expansion of aquaculture practices have led to the emergence and spread of various diseases, causing significant economic losses. In addition, global warming and climate change have significant impact on water quality, fish physiology, and disease dynamics of aquatic organisms. Besides, alterations in water parameters can create more favourable conditions for proliferation of pathogens and increase host susceptibility to diseases.

The aim of the keynote is to introduce some examples of temperature sensitive parasitic diseases of relevance for aquaculture and wild fish.

Proliferative Kidney Disease (PKD) in wild and farmed salmonids is an emerging disease, discussed as one of the critical factors responsible for declining wild salmonid populations across Europe. The disease is caused by the myxozoan endoparasite *Tetracapsuloides bryosalmonae*, showing a complex life cycle between a vertebrate and an invertebrate host. In fish, the parasite induces necrosis and granulomatous inflammation in renal hematopoietic tissue, leading to anaemia, immune suppression and finally death. Higher water temperature promotes disease severity and mortality in fish and accelerate parasite development and excretion in both, the fish and the invertebrate host, increasing the speed of the parasite life cycle. In addition, the immune system of the salmonid host is impacted by temperature stress, further exacerbating the disease outcome.

Since the mid-nineties, a new myxosporean parasite named *Enteromyxum scophthalmi* caused heavy losses in European marine aquaculture with morbidity and mortality rates around 100%. Although the existence of a hypothetical alternate cycle of the parasite in invertebrate hosts cannot be ruled out, the disease can be directly transmitted from fish to fish. Infected turbot suffer a progressive destruction of the gut due to severe catarrhal enteritis that leads to a cachectic syndrome and finally to death. Seasonal fluctuations have been observed, with maximum disease incidence in spring/summer, indicating a temperature dependence of the disease.

Nodular gill disease (NGD) in freshwater salmonids constitutes an ectoparasitic condition provoked by different amoeba species. In fish suffering the disease, gills reveal a marked hypertrophy, dysplasia and hyperplasia of the lining epithelium with lamellar fusion, leading to respiratory distress. Different outbreaks of NGD have been reported in several European countries, including Spain and Switzerland. Probably related to increasing water temperature, prevalence and mortality associated to NGD in both countries increased significantly in recent years, a phenomenon also observed in other European countries, like France or Italy.

Aquaculture systems must adapt to these changing environmental conditions, implementing sustainable practices, and exploring innovative solutions, such as careful site selection, genetic selection for resilience, and improved disease surveillance.

E-mail roberto.bermudez@usc.es

Speaker Abstracts Clinical Pathology

THURSDAY 31 AUGUST | 09.00-10.30

Reference

- Alvelos, Heitor et al. *Posters of a Doctorate - Phd Design 2016_2023+*. ID+, University of Porto Faculty of Fine Arts, 2023.
- Atherton, S. et al. "Use of a Mobile Device App: A Potential New Tool for Poster Presentations and Surgical Education." *Journal of Visual Communication in Medicine*, vol. 36, no. 1-2, 2013, pp. 6-10, doi:10.3109/17453054.2013.790794.
- Barker, Eleanor and Veronica Phillips. "Creating Conference Posters: Structure, Form and Content." *Journal of Perioperative Practice*, vol. 31, no. 7-8, 2021, pp. 296-99, doi:10.1177/1750458921996254.
- Carneiro, José. "Cartaz Científico." *Projecto, Mestrado em Design da Imagem*, Powerpoint Presentation, 2020, p. 14.
- Faulkes, Zen. "The "Wall of Text" Visual Structure of Academic Conference Posters." *Frontiers in Communication*, vol. 8, 2023, doi:10.3389/fcomm.2023.1063345.
- Johns, Martin. "Planning and Producing Scientific Posters." *Journal of Audiovisual Media in Medicine*, vol. 21, no. 1, 1998, pp. 13-17, doi:10.3109/17453059609063116.
- Morrison, Mike. "How to Create a Better Research Poster in Less Time (#Betterposter Generation 1)." 2019. www.youtube.com/watch?v=1RwJbhcCA58.
- Rowe, N. and D. Ilic. "What Impact Do Posters Have on Academic Knowledge Transfer? A Pilot Survey on Author Attitudes and Experiences." *BMC Med Educ*, vol. 9, 2009, p. 71, doi:10.1186/1472-6920-9-71.

E-mail dianamanuela.vieira@gmail.com

Speaker Abstracts Clinical Pathology

THURSDAY 31 AUGUST | 11.00-11.45

PATHOPHYSIOLOGY AND CLINICAL PATHOLOGY OF BONE AND JOINT DISEASES

S. Neumann

Institute of Veterinary Medicine, Göttingen, Germany

Lecture Content

Pathophysiology and clinical pathology of bone and joint diseases. The focus of this lecture is on the physiological and pathophysiological significance of bone as an endocrine organ, as well as the laboratory diagnostic possibilities for the diagnosis of degenerative joint diseases. Hormones synthesised in bone are: Osteocalcin osteopontin and fibroblast growth factor 23. Hormone production influences energy balance, muscle metabolism, phosphate balance, as well as inflammatory reaction and wound healing.

One of the most well-known hormones secreted by bones is called osteocalcin. Osteocalcin's function as an endocrine hormone is diverse and extends beyond its traditional role in bone formation. Here are some of its key functions:

Regulation of glucose metabolism: Osteocalcin acts as a hormone that influences glucose metabolism. It enhances insulin secretion from the pancreas, improving pancreatic beta-cell function. Osteocalcin also increases insulin sensitivity in target tissues such as muscle and fat. Osteopontin (OPN) is a glycoprotein that is abundantly expressed in bones and plays a significant role in bone biochemistry and the function of bones as endocrine organs. It is produced by various cell types, including osteoblasts, osteoclasts, and osteocytes, as well as other tissues outside the skeletal system. Osteopontin is involved in the regulation of bone mineralization. It can bind to hydroxyapatite, a mineral component of bone, and plays a role in promoting the nucleation and growth of hydroxyapatite crystals. Osteopontin is a cytokine-like molecule that contributes to the regulation of immune responses and inflammation. RANKL (receptor activator of nuclear factor kappa-B ligand) is a key molecule involved in the biochemistry and function of bones as endocrine organs. It is primarily produced by osteoblasts, bone marrow stromal cells, and T lymphocytes. RANKL acts as a cytokine and plays a crucial role in regulating bone remodelling, skeletal development, and immune responses. The main biochemical function of RANKL in bones as endocrine organs is its involvement in the regulation of osteoclast activity and bone resorption. Fibroblast growth factor 23 (FGF23) is a hormone that plays a crucial role in the regulation of phosphate and vitamin D metabolism in the body. It is primarily produced by osteocytes, which are cells found in bone tissue, although smaller amounts can also be produced by other cell types such as cardiac myocytes and chondrocytes. The primary role of FGF23 is to regulate phosphate homeostasis.

The pathogenesis of osteoarthritis is a complex process involving the following processes: Chondrocyte degeneration - Joint capsule fibrosis - osteophyte formation - Intra- and periarticular inflammation - Regeneration processes

The path from the triggering insult to arthrosis has not been clarified in every single step. Presumably, the damaged chondrocyte plays a central role in the pathogenesis. Stimulated chondrocytes can secrete cytokines which, as proinflammatory cytokines, cause inflammatory reactions. These include interleukin-1, -6 (IL-1, IL-6) and tumour necrosis factor (TNF). Induced by these cytokines, inflammatory proteins such as metalloproteases are formed and inflammatory cells migrate into the damaged tissue. At the same time, regenerative processes are suppressed. An imbalance develops in the joint in the ratio of regeneration to destruction. The result is changes in the cartilage matrix with disturbances in the balance of the basic substance, consisting of glucosaminoglycans, chondroitin sulphates and water. In addition to these changes, the formation of osteophytes is a characteristic of arthritic joints. In terms of structure, they are bone substance surrounded by hyaline cartilage. Why such structures form is not fully understood. It is possible that the increased release of vascular endothelial growth factor (VEGF) in the inflamed tissue plays a role. The capsular fibrosis that develops in arthrosis is probably a consequence of the chronic inflammation in the joint. As in other localisations in the organism, there is an immigration of fibroblasts and the formation of connective tissue in the form of collagens in chronically inflamed tissue. This is a sign of a lack of regeneration and thus the formation of replacement tissue in the sense of a scar. Accordingly, biochemical arthrosis markers can be mediators of inflammation, dissipated matrix components or mediators of osteoarthritic remodelling. Markers that have shown correlations to destruction in the joint include tenascin-C, interleukin-8, matrix metalloprotease 1-3, chondroitin sulphate and hyaluronic acid.

Some new markers follow the hypothesis that osteoarthritis follows a similar course as a healing bone. After the fracture, the bone undergoes a callus phase and remodelling. Accordingly, molecules that are involved in bone healing could be elevated in the serum in osteoarthritis and serve as markers for osteoarthritis. These include RANKL and osteocalcin.

E-mail sneuman@gwdg.de

Speaker Abstracts Clinical Pathology

THURSDAY 31 AUGUST | 14.00-14.45

IMMATURE PLATELET FRACTION (IPF) IN THE DIFFERENTIAL DIAGNOSIS OF CANINE AND FELINE THROMBOCYTOPENIA

A. Perez-Ecija

University of Cordoba, Cordoba, Spain

Introduction. Thrombocytopenia (TP) is one of the most common laboratory abnormalities found in small animals. Differentiating central (bone marrow failure, myelophthisis, etc.) from peripheral TP (any pathology causing elevated consumption, destruction or sequester of platelets, such as immune-mediated thrombocytopenia, DIC, splenopathy, etc.) usually requires a myriad of tests and even invasive procedures such as bone marrow analysis. Pseudothrombocytopenia due to platelet aggregates further complicates this diagnosis. The Sysmex XN-V analyzer has a specific optic-fluorescent channel for platelets (PLT-F), where an oxazine-based fluorescent dye is used to recognize RNA content and provide the immature platelet fraction (IPF). Immature platelets (previously known as reticulated platelets) are those recently released from the bone marrow. Thus, IPF could serve as a surrogate measurement of active thrombopoiesis. While IPF is widely used in the differential diagnosis of thrombocytopenia in human medicine, its application to small animals is currently unreported.

Objectives. To establish reference ranges for IPF (%) in healthy dogs and cats and to study its variations between patients with different subtypes of thrombocytopenia.

Materials and methods. Animals were retrospectively selected from those referred to the Veterinary Teaching Hospital of the University of Cordoba between January 2021 and May 2023 with complete medical records and a CBC analysis using the Sysmex XN-V analyzer. Patients were included in the healthy groups based on normal clinical history, normal complete physical examination, and hematology results within reference ranges in our institution (platelets $>200 \times 10^3/\mu\text{L}$ in dogs; $>250 \times 10^3/\mu\text{L}$ in cats). Thrombocytopenic animals were selected amongst those with platelet counts below reference ranges. A blood smear from each case was used to obtain the estimated platelet concentration and evaluate platelet aggregation. Only cases where both automatic and estimated platelet counts were below ranges and with a final diagnosis related to a pathology known to cause central or peripheral TP were considered as true thrombocytopenia. The subclassification of the type of TP was based on all available diagnostic information (e.g., history, clinical signs, CBC, blood smear, serum biochemistry, bone marrow examination, blood PCR for infectious diseases, radiographs and ultrasound, treatment responses, etc.). No repeated analyses from the same patient were included. All blood samples were collected by cephalic or jugular venipuncture in an EDTA-containing tube and analyzed within 30 min using the Sysmex XN-V analyzer.

Results and discussion. A total of 803 dogs and 66 cats were included in the healthy groups. Reference ranges for IPF (%) were between 0.5-8 in dogs and 0-35 % in cats. No significant differences were observed in any species related to sex or age group. 31 dog breeds and 5 cat breeds were included in the study, without significant differences between them concerning these parameters. Neither Cavalier King Charles Spaniel nor greyhounds were included in the study. Although immature platelets are measured using different dyes and techniques in different analyzers, our ranges are similar (but wider) to those previously reported with other analyzers. IPF (%) was significantly different between TP groups, with patients with peripheral TP showing higher values compared to pseudoTP and both groups showing higher percentages to central TP. Despite these statistical differences, there was overlapping of pseudoTP values with other groups. Nonetheless, once pseudoTP was discarded, a highly sensitive and specific cutoff value could be established to differentiate peripheral from central TP ($>6,9\%$ in dogs, with 6.90, with 95% sensitivity and 94% specificity; $>13,6\%$ in cats, with 94% sensitivity and 85% specificity).

Conclusions. The use of IPF(%) in the Sysmex XN-V analyzer can help in the differential diagnosis of thrombocytopenia and guide further clinical tests and procedures (e.g., avoiding unnecessary bone marrow sampling), being an inexpensive, quick and reliable tool in these patients. A blood smear examination should always be performed in order to detect platelet aggregates.

Reference

- Briggs C. et al. Assessment of an immature platelet fraction (IPF) in peripheral thrombocytopenia. *Br J Haematol.* 2004;126(1):93-9.
- Brooks M.B., Harr K.E., Seelig D.M., Wardrop K.J., Weiss D.J., Schalm's Veterinary hematology, Hoboken, USA.: Wiley Blackwell; 2022, 78; 675-686.
- Grebert M. et al. Validation of the Sysmex XN-V hematology analyzer for canine specimens. *Vet Clin Pathol.* 2021;50:184-197.
- Friedrichs, K.R. et al. ASVCP reference interval guidelines: determination of de novo reference intervals in veterinary species and other related topics. *Vet Clin Pathol.* 2012;41:441-453.
- Kuhn A. Evaluation of a novel moving threshold gating strategy for assessment of reticulated platelets in dogs using the ADVIA 2120 analyzer. *Vet Clin Pathol.* 2023;52:11-21.

E-mail alejandro.perez.ecija@uco.es

Speaker Abstracts Clinical Pathology

THURSDAY 31 AUGUST | 16.00-16.45

EVOLUTION OF ERYTHROCYTES IN VERTEBRATES

J. Harvey

University of Florida, Gainesville, United States

Lecture Content

Variations in Erythrocyte Size. Fish were the first vertebrates to evolve. Their erythrocytes are nucleated and oval or elliptical in shape, as are the erythrocytes of amphibians, reptiles, and birds. Jawless lampreys and hagfish are the most primitive fish alive today. They have large erythrocytes (MCV 400-1500 fL) that vary by species. Cartilaginous fish (sharks, rays) have similarly large erythrocytes (MCV 600-1100 fL). Erythrocytes are generally smaller in bony fish (MCV 100-300 fL), except for primitive lobe-finned fish (coelacanths and lungfish). Lungfish have by far the largest erythrocytes (MCV 4,300 to 6950 fL) of fish species. With the exception of lungfish, amphibians generally have the largest erythrocytes in vertebrates. They are generally larger in salamanders and newts (MCV 1,600-14,000 fL), with the largest in *Amphiuma* species and mud puppies, than in frogs and toads (most MCVs are between 200 and 1,400 fL). Erythrocytes in reptiles are generally smaller than amphibians (MCV 200 to 700 fL), and erythrocytes in birds are smaller yet (MCVs 100-160 fL). Mammalian erythrocytes are not only smaller than the other vertebrate classes (generally MCVs 20-150 fL), but their erythrocytes lack nuclei and most have a variable biconcave shape. The smallest erythrocytes occur in mouse deer with MCVs about 6 fL.

Variations in Erythrocyte Morphology. A number of variations in erythrocyte morphology are present in vertebrates. Although nearly all nonmammals have oval/elliptical nucleated erythrocytes, enucleated erythrocytes are exclusively found in three deep-sea Gonostomatidae (bristlemouth) fish species, and enucleated erythrocytes account for more than 90% of erythrocytes in some *Batrachoseps* salamander species. Remarkably, 16 species of icefish have evolved without erythrocytes or blood hemoglobin. Although most mammals have biconcave erythrocytes, camelid erythrocytes are small, wafer thin, and elliptical in shape. In addition, drepanocyte formation (sickling) occurs in vitro in some deer species, a variety of irregularly shaped erythrocytes may be present in clinically normal goats and young cattle, and spiculated echinocytes are a consistent artifact observed in stained blood films from pigs.

Genome and Erythrocyte Size. There is a generally a positive correlation between genome size (pg DNA/nucleus), nuclear size, and erythrocyte size in nonmammalian vertebrates. This raises the question, "How can some salamanders have genomes about 35 times that of humans?" The answer is that, only a small fraction of nuclear DNA (less than 2% in human cells) codes for proteins, and cells from less evolved animals (with much larger genomes) contain much larger amounts of noncoding DNA. Some noncoding DNAs have recognized functions, including regulation of gene expression; however most noncoding DNA consists of transposable elements and other repetitive sequences whose function (if any) is largely unknown. The genome size in mammals is generally about twice that of birds; however, the expulsion of the nucleus allows for the production of smaller erythrocytes in mammals than in birds. Various theories have been proposed to explain the relationship between genome size and cell size. Cells with larger genomes have longer cell cycles which might allow for more time to increase cell volume.

Capillary and Erythrocyte Size. There is a positive correlation between capillary diameter and erythrocyte size in vertebrates, indicating that erythrocyte size has been an important part of the evolutionary development of the circulatory system. Erythrocytes are generally larger (25% or more) than their smallest respective capillaries. Consequently, they must deform to pass through these small vessels. Nucleated nonmammalian erythrocytes are less deformable than enucleated mammalian erythrocytes, and it appears that capillary diameter is matched to both size and deformability of erythrocytes.

Metabolic Rate, Hemoglobin Oxygen Affinity, and Erythrocyte Size. Animals with higher metabolic rates generally have smaller erythrocytes and smaller capillaries with higher capillary densities in various tissues. More numerous, smaller capillaries decrease the distance that gases must diffuse between blood and tissue cells. In addition to decreased diffusion distance, smaller mammals have lower whole blood hemoglobin oxygen affinities, which promote release of oxygen at higher oxygen tensions, creating a larger oxygen gradient between erythrocytes and tissue cells where oxygen is utilized. Capillary density is generally higher in homeothermic birds and mammals, compared to poikilothermic vertebrates. Smaller vessel dimensions result in increased resistance to blood flow, resulting in increased blood pressure. This need for increased blood pressure required the development of separate pulmonary and systemic circulatory systems with four chambered hearts in birds and mammals to provide arterial blood from the lungs to the systemic circulation under high pressure and blood to the pulmonary circulation under lower pressure.

E-mail jwharvey@ufl.edu

Speaker Abstracts Clinical Pathology

THURSDAY 31 AUGUST | 16.45-17.30

EQUINE HAEMATOLOGY: FOAL TO ADULT

A. Draper

Idexx Laboratories, Lower Stondon, United Kingdom

Lecture Content

Many of the studies published evaluating foal, sex and breed differences are performed across different laboratories, on differing instrumentation. Therefore, direct comparison to patient data should be made with caution. Ideally age- and breed-matched reference intervals devised by the laboratory that analyses your samples should be used to evaluate the patient's data. However, this is often not possible due to regional difficulties in generating reference intervals. Establishing a trend will always be important, with serial haematology analyses where applicable.

Summary of haematology differences between foals and adults (and sexes and breeds where applicable):

NB: Cold blooded breeds include Draught and Pony breeds, and Hot blooded breeds are TB and Arabians. Crosses of the two are warm-blooded.

Reference

- Barton MH 2015 AAEP Proceedings Vol 61 P125-129.
- Benson C, Overmann J and Sharkey L 2015 Chapter 24-25 Alterations in the erythron and leukogram P377-385 In: Large Animal Internal Medicine, 5th Edition edited by Smith B.
- Faramarzi B and Rich L 2019 Vet Rec doi: 10.1136/vr.104461
- Grondin TM and Dewitt SF 2010 Chapter 106 Normal haematology of the horse and donkey, P821-828 In: Scharm's Veterinary Haematology, 6th Edition edited by Weiss DJ and Wardrop KJ.
- Munoz A et al. 2012 Research in Vet Sci 93 943-949

E-mail acedf1@icloud.com

Speaker Abstracts Joint Stream

FRIDAY 1 SEPTEMBER | 13.30-14.10

CLOSING THE CIRCLE: BRIDGING THE ADVANCES IN CANCER UNDERSTANDING WITH ADVANCES IN THERAPEUTICS AND DIAGNOSIS

D. Argyle

University of Edinburgh, Edinburgh, United Kingdom

Lecture Content

The Challenges of Veterinary Oncology | Veterinary Oncology has developed significantly over the past 30 years. We have seen the development of new diagnostics and therapeutics which have been progressed into clinical practice. However, we are still far from making a step change in improving outcomes, not least of which is quality of life. The grand challenges of oncology remain including early detection, non-invasive diagnosis, effective and non-toxic treatments and ensuring a good quality of life. Despite this, our understanding of cancer is exponentially increasing, and with it, the realization of its complexity.

Understanding Biology is Key | For many years we have taken a reductionist view of oncology in trying to understand single oncogenic drivers. In fact, the situation is far more complex. Recently, we have identified that cancer per se resembles an organ system, in that maintenance of the cancer in situ may be being driven by true tumour stem cells that have the characteristics of resistance to treatment and promoting metastatic spread. More recently, extra-chromosomal DNA fragments have been identified that also confer resistance to radiation and chemotherapy. It is also apparent that the tumour micro-environment is fundamental to cancer survival and supporting the metastatic niche. Complicating this, is the constant and rapid evolution of the tumour under the selection pressures imposed by the immune system as well as drug or radiation treatments. The complexity can seem overwhelming, but our ability to detect cancer earlier, understand the malignant drivers and mechanism of resistance development are a pre-requisite to improving patient outcomes.

Improving Diagnosis | We have expanded the diagnostic repertoire for cancer significantly beyond cytology and histopathology. We now have a suite of reagents for immunohistochemistry and Flow cytometry that have allowed us to improve our stratification of patients and improve diagnosis. In parallel, we now have techniques that allow us to dissect genome, proteome and even microbiome. The challenge now, is to harness these techniques to improve both the stratification of cancer for precision oncology and the earlier detection of cancer where therapies have the greatest opportunity for success. Genetic and proteomic analysis have allowed an exponential expansion of data around cancer, but (at the moment) this amount of data currently out-strips our ability to build algorithms to implement strategies for cancer control. However, in parallel, the development of liquid biopsy techniques for early diagnosis is now moving into a clinical phase. Liquid biopsy refers to utilizing blood or other fluids to identify the presence of cancer through circulating tumour cells, fragments of cancer derived nucleic acids or other markers of malignancy. This is revolutionising diagnosis as it allows early detection, minimal invasion and continuous monitoring of therapy. However, there is still some way to go to ensure clinical validation in large populations of patients, and also how we can integrate this into precision oncology for stratified therapeutics.

Improving Therapy | Earlier detection and our ability to stratify tumours will have major ramifications for future therapy. This may also allow us to better understand the immune response to tumours and how better this may be harnessed for therapy. The revolution of liquid biopsy, coupled with accessible molecular diagnostics is a major step forward. However, there is still some way to go to develop robust clinical protocols.

Horizon Scanning | Clinical cancer research is at an incredibly exciting period where we are bridging molecular biology with earlier and less invasive diagnosis. In this lecture I will explore the current state of the art in human and veterinary diagnostics and how we bridge this to our current understanding of the molecular evolution of cancer, cancer stem cells and continuous monitoring of cancer treatments.

E-mail david.argyle@roslin.ed.ac.uk

Speaker Abstracts Joint Stream

FRIDAY 1 SEPTEMBER | 14.10-14.50

CLINICAL LABORATORY EXPERIENCE WITH A NEXT-GENERATION SEQUENCING-BASED LIQUID BIOPSY TEST FOR CANCER DETECTION IN DOGS

A. Flory

PetDx, La Jolla, United States

Lecture Content

What is liquid biopsy?

Liquid biopsy broadly refers to the sampling and analysis of analytes from various biological fluids.¹ Cell-free DNA ("cfDNA") is composed of fragments of DNA that are circulating in the bloodstream which are released into circulation when cell death occurs. cfDNA fragments are rapidly degraded by normal processes, with a very short half-life of minutes to hours.^{2,3} Next-generation sequencing (NGS) is an advanced technology currently employed in human cancer screening^{4,5} that enables interrogation of multiple classes of genomic alterations known to be associated with cancer. Detection of such genomic alterations in the cfDNA of a patient is indicative of the presence of tumor cells in the body, providing the rationale for "liquid biopsy" testing approaches,¹ and allows cancer detection across a range of clinical scenarios, or "use cases": (1) screening in asymptomatic high-risk patients, (2) aid-in-diagnosis for patients in which there is a clinical suspicion of cancer, (3) targeted treatment selection, (4) detection of minimal residual disease following surgery, (5) treatment response monitoring, and (6) recurrence monitoring after cancer therapy.¹

Clinical validation

The clinical validation of a novel next-generation sequencing-based liquid biopsy test for dogs, the CANCER Detection in Dogs (CANDiD) study⁶, included a total of 1,100 prospectively collected whole blood samples from client-owned dogs with and without cancer. In total, 30 distinct cancer types were detected by the test. The overall specificity of the test was 98.5% (false-positive rate of 1.5%), with 85% detection rate in three of the most aggressive canine cancers (lymphoma, hemangiosarcoma, and osteosarcoma), and 55% in the all-comers group.

Real-world clinical experience with liquid biopsy

Once a test is clinically validated and available commercially, it is important for the laboratory to periodically report utilization and performance metrics regarding the test. To evaluate the clinical performance of NGS-based liquid biopsy testing, a retrospective observational study was conducted, in which test result data from 1,500 consecutive clinical samples along with corresponding patient outcome data from referring veterinary clinics were analyzed.⁸ In summary, the majority (64%) of samples were submitted for cancer screening, followed by 26% for aid-in-diagnosis, and 10% for other indications. The test positivity rate was 25.4% in aid-in-diagnosis patients, and 4.5% in screening. Outcome data were available for 33% of patients. The relative observed sensitivity and specificity (61.5% and 97.5%, respectively) were within or above the confidence intervals for expected test performance established in the clinical validation study. The relative observed positive predictive value was 75% for screening and 98% for aid-in-diagnosis, and time to diagnostic resolution following a positive result was less than two weeks.

Conclusion

Blood-based liquid biopsy testing using next-generation sequencing is an exciting new tool for the detection of cancer in dogs. The test's performance metrics were established in a large clinical validation study and supported in a real-world study involving 1,500 clinical samples. Liquid biopsy provides an opportunity for early cancer detection and provides veterinarians with a noninvasive tool to help aid in the diagnosis and monitoring of cancer.

Speaker Abstracts Joint Stream

FRIDAY 1 SEPTEMBER | 14.10-14.50

Reference

- Chibuk J, Flory A, Kruglyak KM, Leibman N, Nahama A, Dharajiya N, et al. Horizons in Veterinary Precision Oncology: Fundamentals of Cancer Genomics and Applications of Liquid Biopsy for the Detection, Characterization, and Management of Cancer in Dogs. *Frontiers Vet Sci.* 2021;8.
- Kustanovich A, Schwartz R, Peretz T, Grinshpun A. Life and death of circulating cell-free DNA. *Cancer Biol Ther.* 2019;1-11.
- Wilson IJ, Burchell RK, Worth AJ, Burton SE, Gedye KR, Clark KJ, et al. Kinetics of Plasma Cell-Free DNA and Creatine Kinase in a Canine Model of Tissue Injury. *J Vet Intern Med.* 2018;32(1):157-64.
- Klein EA, Richards D, Cohn A, Tummala M, Lapham R, Cosgrove D, et al. Clinical validation of a targeted methylation-based multi-cancer early detection test using an independent validation set. *Ann Oncol.* 2021;32(9):1167-77.
- Early Cancer Detection Test | Galleri® for HCPs [Internet]. [cited 2023 Feb]. Available: <https://www.galleri.com/hcp/the-galleri-test>
- Flory A, Kruglyak KM, Tynan JA, McLennan LM, Rafalko JM, Fiaux PC, et al. Clinical validation of a next-generation sequencing-based multi-cancer early detection “liquid biopsy” blood test in over 1,000 dogs using an independent testing set: The CANcer Detection in Dogs (CANDiD) study. *Plos One.* 2022;17(4).
- Biller B, Berg J, Garrett L, Ruslander D, Wearing R, Abbott B, et al. 2016 AAHA Oncology Guidelines for Dogs and Cats. *J Am Anim Hosp Assoc.* 2016;52(4):181-204.
- O’Kell AL, Lytle KM, Cohen TA, Wong LK, Sandford E, Rafalko JM, et al. Clinical experience with next-generation sequencing-based liquid biopsy testing for cancer detection in dogs: a review of 1,500 consecutive clinical cases. *J Am Vet Med Assoc.* 2023;261(6).

E-mail aflory@petdx.com

Speaker Abstracts Joint Stream

FRIDAY 1 SEPTEMBER | 14.50-15.30

IS HISTOPATHOLOGY OF TUMORS OUTDATED? ADVANCES AND POTENTIALS OF OLD-FASHIONED TECHNIQUES IN THE -OMICS ERA

G. Avallone

University of Bologna, Ozzano dell'Emilia, Italy

Lecture Content

Anatomical pathology, the discipline studying the macroscopic and microscopic alterations of organs and tissues in diseases, was born in the 18th century. One-hundred years later the terms anaplasia and dedifferentiation were introduced, and it was suggested that the behavior of tumors could be predicted from their microscopic appearance, leading, in 1920, to the first histological grading system. Since then, the histological evaluation has been central in the management of oncologic patients: diagnosis, classification, grading, and prognostic parameters have been developed, discovered and refined. In the last decades, the development of biomolecular technologies achieved great importance in human oncology, increasing the knowledge of tumor biology, from diagnosis, to prognosis, to the identification of targets for therapy and opening the doors of the so called "personalized" medicine. In this context, while maintaining the "classical" purpose of providing a diagnosis based on the cell of origin, histopathology also began to provide a framework within which to interpret immunohistochemical and biomolecular tests. Examples of this approach are the classification of soft tissue sarcomas in translocation-related and complex-karyotype ones, and the "layered" neuropathology diagnosis of the 2021 WHO classification of tumors of the CNS. These progresses also involve veterinary pathology and veterinary oncology, even if the knowledge of the molecular alterations of tumors of domestic animals is so far limited. Currently, veterinary histopathology provides prognostic parameters such as the grade, the Ki67 labeling index, the histological status of surgical margins, and many others. Nevertheless, the imprecisions in the evaluation of these parameters have been recently evidenced and are related to the subjectivity of their assessment. The awareness of this led to the development of initiatives and projects aimed to provide guidelines, SOP and tools supporting the pathologists in providing data as precise and objective as possible. These includes, but are not limited to, the Veterinary Cancer Guidelines and Protocols (VCGP), aiming to improve care for pets with cancer through standardization of tumor evaluation and reporting, the Global Initiative for Veterinary Cancer Surveillance (GIVCS), that aims to create a consensus on and foster the establishment of standardized methods for animal cancer reporting, and the Oncology-Pathology Working Group (OPWG) promoting an integrated working relationship between veterinary oncologists and pathologists to facilitate and ensure the highest standard of pathology support and reporting for the advancement of veterinary clinical oncology and cancer research. The result is a series of SOP, guidelines, consensus documents and the system for coding canine neoplasms based on the human ICD-O-3.2 (Vet-ICD-O-Canine-1), allowing pathologists to provide and collect more accurate and comparable data to be used for multi-institutional studies. Furthermore, the combined exponential growth of tissue scanning technology, image analysis, bioinformatics and artificial intelligence, are initiating a completely new area of research. With these new tools, the variability due to the subjective interpretation of histologic specimens is going to be largely reduced in the next future, and new types of data are likely to be collected and analyzed, hopefully providing more and more accurate prognostic and predictive information to clinicians. Despite old, histopathology seems to still keep a central role in the study of tumors, providing the basis for more recent and technologically advanced analysis which hopefully will lead to a more comprehensive knowledge of neoplastic diseases.

Reference

- Avallone G, et al. Review of Histological Grading Systems in Veterinary Medicine. *Vet Pathol.* 2021 Sep;58(5):809-828.
- Berlato D, et al. Value, Limitations, and Recommendations for Grading of Canine Cutaneous Mast Cell Tumors: A Consensus of the Oncology-Pathology Working Group. *Vet Pathol.* 2021 Sep;58(5):858-863.
- Choi JH, Ro JY. The 2020 WHO Classification of Tumors of Soft Tissue: Selected Changes and New Entities. *Adv Anat Pathol.* 2021 Jan;28(1):44-58.
- Meuten DJ, et al. International Guidelines for Veterinary Tumor Pathology: A Call to Action. *Vet Pathol.* 2021 Sep;58(5):766-794.
- Osborn AG, et al. The 2021 World Health Organization Classification of Tumors of the Central Nervous System: What Neuroradiologists Need to Know. *AJNR Am J Neuroradiol.* 2022 Jul;43(7):928-937.
- Pinello K, et al. Vet-ICD-O-Canine-1, a System for Coding Canine Neoplasms Based on the Human ICD-O-3.2. *Cancers (Basel).* 2022 Mar 16;14(6):1529.
- Pinello KC, et al. The Global Initiative for Veterinary Cancer Surveillance (GIVCS): Report of the first meeting and future perspectives. *Vet Comp Oncol.* 2020 Jun;18(2):141-142.
- Puri M, et al. Automated Computational Detection, Quantitation, and Mapping of Mitosis in Whole-Slide Images for Clinically Actionable Surgical Pathology Decision Support. *J Pathol Inform.* 2019 Feb 7;10:4.
- Smedley RC, et al. Diagnosis and histopathologic prognostication of canine melanocytic neoplasms: A consensus of the Oncology-Pathology Working Group. *Vet Comp Oncol.* 2022 Dec;20(4):739-751.

E-mail giancarlo.avallone@unibo.it

Speaker Abstracts Veterinary Pathology

FRIDAY 1 SEPTEMBER | 08.45-09.30

UPDATE ON AVIAN INFLUENZA VIRUS INFECTION IN EUROPE

N. Majó Masferrer

Universitat Autònoma de Barcelona (UAB), Bellaterra (Barcelona), Spain

Lecture Content

Since 2020, Europe is facing the worst epidemics of highly pathogenic avian influenza (HPAI) of the last century. This disease has become the main threat to the European poultry industry, but also a big concern for biodiversity, due to the expanded tropism of the current circulating viral strains to new wild bird species. In the last three years, more than 13,000 HPAI viral detections in almost 40 different European countries have been described, and the epidemics is still on going. Moreover, the high circulation of the virus in farms and in the wild, increases the possibility of emergence of a viral strain with pandemic potential for humans (1).

Current HPAI outbreaks in Europe and other parts of the world are associated to H5 viruses that have a common ancestor, the A/goose/Guandong/1/96 H5N1 strain, that caused the first zoonotic outbreak in 1997 in Hong Kong. Since then, this strain has largely diversified into different genetic clades, being the clade 2.3.4.4.b the most prevalent nowadays in Europe, and the rest of the world. As regards to HPAI A (H5) outbreaks in European poultry farms since 2020, domestic ducks are the most severely affected type of production, followed by chicken and turkey farms. Many domestic goose farms have also been found positive in countries where this type of production is important, such as France and Hungary. Moreover, an unprecedented number of wild birds are becoming also affected by this virus across Europe. Waterfowl (swans, wild geese and mallards), but also colony-breeding seabirds, and more specifically, Laridae species, were hit by the virus from spring 2022 until now (1). Mass mortalities of Black-headed gulls and European herring gulls have been reported in France, Belgium, the Netherlands, and Italy from January 2023. In these outbreaks, numerous birds with neurological signs or found death have been confirmed to be infected with HPAI A (H5N1) by molecular techniques. Apart from birds, the current HPAI A (H5N1) strain has infected many wild terrestrial and aquatic mammals. Foxes, racoons, bears and seals are the most commonly affected, probably by feeding on infected bird carcasses. These infections in mammals are associated to severe neurological disease and death, with extensive viral replication in the brain of infected animals, and limited or no replication in other organs. Although genetic analysis demonstrated some mutations that might indicate mammalian adaption of the virus, most of these infections are considered "dead-end", and no transmission among wild mammals has been reported in Europe until now (2). However, in October 2022, mink in a fur farm in Galicia (Spain) started to show high mortalities and neurological signs and tested positive for HPAI A (H5N1). The most likely source of infection was close contact with infected wild birds, although transmission among minks was also suspected (3). This, together with a couple of outbreaks with high mortalities in marine mammals of the Caspian Sea and along the Pacific coast of South America, raises the concern of the HPAI A (H5N1) being able to adapt and spread efficiently among mammals.

In the present talk, a brief introduction of the main characteristics of avian influenza virus, followed by a discussion of the infection dynamics in different birds species, as well as an update of the current epidemiological situation will be presented.

Reference

- Avian influenza overview December 2022 - March 2023. European Food Safety Authority; European Centre for Disease Prevention and Control; European Union Reference Laboratory for Avian Influenza; Adlhoch C, Fusaro A, Gonzales JL, Kuiken T, Marangon S, Mirinaviciute G, Niqueux É, Stahl K, Staubach C, Terregino C, Broglia A, Baldinelli F. EFSA J. 2023 Mar 20;21(3):e07917. doi: 10.2903/j.efsa.2023.7917.
- Highly Pathogenic Avian Influenza H5N1 Virus Infections in Wild Red Foxes (*Vulpes vulpes*) Show Neurotropism and Adaptive Virus Mutations. Bordes L, Vreman S, Heutink R, Roose M, Venema S, Pritz-Verschuren SBE, Rijks JM, Gonzales JL, Germeraad EA, Engelsma M, Beerens N. Microbiol Spectr. 2023 Feb 14;11(1):e0286722. doi: 10.1128/spectrum.02867-22.
- Highly pathogenic avian influenza A(H5N1) virus infection in farmed minks, Spain, October 2022. Agüero M, Monne I, Sánchez A, Zecchin B, Fusaro A, Ruano MJ, Del Valle Arrojo M, Fernández-Antonio R, Souto AM, Tordable P, Cañás J, Bonfante F, Giussani E, Terregino C, Orejas JJ. Euro Surveill. 2023 Jan;28(3):2300001. doi: 10.2807/1560-7917.ES.2023.28.3.2300001.

E-mail natalia.majo@uab.cat

Speaker Abstracts Veterinary Pathology

FRIDAY 1 SEPTEMBER | 09.30-10.15

EMERGING PROBLEMS IN POULTRY: WHAT ARE THE POULTRY DIAGNOSTICIANS FACING?

À. Cobos ¹, N. Majó ¹, M. Biarnés ², I. Torres ², I. Fabra ²

¹ IRTA - CReSA / UAB, Bellaterra, Spain

² Centre de Sanitat Avícola de Catalunya i Aragó (CESAC), Reus, Spain

Lecture Content

When managing poultry flocks, clinicians often require precise and rapid diagnosis. Post-mortem examination at the farm is often part of routine diagnostic procedures, but pathological evaluation requires additional laboratorial determinations and its interpretation to reach a definitive diagnosis. For this reason, avian pathologists may also be called diagnosticians, reinforcing the idea that lesions must be correlated with knowledge on avian health and poultry production system. Moreover, avian pathology is a unique discipline itself due to birds having unique anatomic and histologic features, and different tissular responses to injuries when compared to mammals (Abdul-Aziz, T. et al, 2016). All this is considered in a systematized workflow which enables rapid confirmation or ruling-out usual and known conditions. However, facing emerging or reemerging problems is far more challenging.

Several endemic bacterial agents repeatedly threaten poultry flocks, with several of them deserving special attention. Overall decreased use of antibiotics, emergence of strains with antimicrobial resistance, enhanced biosecurity, and changes in legislation in housing of the laying hens appear to be significant factors that benefit specific emerging bacterial pathogens (Swayne, D.E. et al., 2020). Among these, we have seen a significant increase in isolation of *E. cecorum*, linked to septicaemic processes and osteomyelitis. Despite often considered to mainly affect turkeys, *E. rhusiopathiae* has been diagnosed increasingly in laying hens. Overall systemic bacterial infections in broilers appear as polyserositis or hepatitis. In the latter, *C. hepaticus* has gained a lot of relevance lately and is being isolated in a constant number of cases, also linked to changes in productive systems (Phung C. et al., 2019). Although control of viral diseases by vaccination has greatly improve the prevalence of this diseases in the poultry flocks, classical viral infections such as infectious bronchitis, Marek's disease or inclusion body hepatitis are still diagnosed quite frequently.

Other causes of morbidity are gaining relevance, especially multifactorial conditions with important genetic background. For instance, diagnostic requests regarding locomotor problems of non-infectious origin have increased dramatically in the last years. Additionally, a condition named intestinal dilation syndrome, which affects brown parents of laying hens has gained much local attention lately due to the productive impact and lack of treatment options.

We revisited our diagnostic database in order to detect the main and emerging concerns and evolution of the poultry industry, as well as to assess the pitfalls that poultry diagnosticians may face in the context of modern poultry production.

Reference

- Abdul-Aziz, T., *Avian Histopathology*, Madison, USA, : Omnipress, 2016.
- Swayne, D.E., *Diseases of Poultry*, Hoboken, USA, : John Wiley & Sons, INC, 2020; 1010-1018.
- Phung C., *Campylobacter hepaticus, the Cause of Spotty Liver Disease in Chickens: Transmission and routes of Infection*, Front Vet Sci., 2019.

E-mail alex.cobos@irta.cat

Speaker Abstracts Clinical Pathology

FRIDAY 1 SEPTEMBER | 08.45-09.30

REPEAT PATIENT TESTING FOR VETERINARY HAEMATOLOGY ANALYSERS

S. Daly

Veterinary Pathology Group (VPG), Cork, Ireland

Lecture Content

Commercial veterinary laboratories are faced with a difficult challenge when it comes to species-specific quality control material (QCM) which is not currently commercially available. The QCM available for veterinary medicine is typically derived from human blood and artificial/synthetic components which do not represent a commutable matrix for veterinary specimens. A commutable matrix would be from animal origin and, represent the species most comparable to the laboratory throughput as this would provide assurances on performance of the haematology analyser relating to the veterinary specimens. An alternative to commercial quality control material is to use retained patient samples, known as repeat patient testing quality control (RPT-QC) ¹. Patient samples, under defined time intervals and storage conditions, deteriorate in a predictable manner between the baseline measurement and the repeated measurement ². The difference between these measurements can be collated and used to generate RPT-QC limits where any RPT-QC measurements outside these limits deem the analyser out-of-control. The literature recommends collection of a pilot data set of 20 samples to generate the limits and once the initial limit derivation phase is complete, a fresh RPT-QC is measured on day one and measured again within a defined time interval, the recommendation is to collect an additional 20 RPT-QC measurements for this validation phase ³. The difference between the measurements is calculated and plotted on a Levey-Jennings chart, like other QC procedure, to identify outliers. Implementation of RPT-QC for haematology in our network of laboratories occurred in stages. Education was the initial and crucial step of the process. A working group consisting of haematology technicians and clinical pathologists were given several presentations to promote the sound statistical basis of RPT-QC, and to meet any skepticism or discomfort with thorough discussions and reassurances surrounding the use of the retained samples as a preferred species-specific matrix with canine samples being the specimen of choice as it represents the main type of haematology specimen submitted to the laboratory. The data generation stage for RPT-QC included 4 Sysmex haematology analysers within a network of veterinary laboratories. An automated spreadsheet was designed for data entry, generation of Levey-Jennings charts and calculation of SDs and CVs. Our data showed that more often 40 datapoints were required to generate RPT-QC limits that would validate with a further 20 datapoints ⁴, which differed from the literature, this allowed for a better distribution of the data that adequately filled the range. Quality control validation based on the RPT-QC data for each analyser and for each time interval was undertaken to ensure that a high probability of error detection and a low probability of false rejection could be achieved. Sigma metrics were calculated to monitor performance across the time intervals for the haematology measurands with >5.5 sigma strategy as the benchmark for excellent performance. The RPT-QC limits were challenged to ensure analytical instability could be detected. These challenges were created by manipulating samples to create intentional abnormalities such as haemodiluted and haemoconcentrated specimens and the addition of lipid creating a lipaemic sample. Further challenges included creating substandard sample integrity by freezing the specimen and storing past 4 days and underfilling the sample to create a high EDTA: blood ratio. The challenges were successful and flagged on the QC spreadsheet as out-of-control by RPT-QC ⁴. Comparison of the commercial QCM and RPT-QC used in parallel was undertaken using one analyser within the network. This process was used to assess if unified RPT-QC limits could be applied to a network of analysers and if performance of RPT-QC could be compared to commercial QCM. This stage demonstrated that individual RPT-QC limits are required based on the observed analyser performance. In conclusion, RPT-QC could be successfully validated and implemented within a network of haematology analysers. It could detect unstable analytical performance and provide assurances that quality control for the haematology analysers is being monitored based on the correct species-specific matrix and that performance issues can be identified.

Reference

- Dutra FR. Monitoring the Quality of Blood Cell Counts with Replicate Determinations on Routine Samples. *American Journal of Clinical Pathology*. 1966;46(2_ts):286-288. Flatland B, Freeman KP. Repeat patient testing shows promise as a quality control method for veterinary hematology testing. *Vet Clin Pathol*. 2018;47(2):252-266. Westgard J. *Implementing repeat patient test controls*. In: *Basic QC Practices: Training in Statistical Quality Control for Medical Laboratories*. 4th ed. Madison, WI: Westgard QC; 2016. Daly S, Graham PA, Freeman KP. Repeat patient testing-quality control with canine samples shows promise as an alternative to commercial quality control material for a network of four Sysmex XT-2000iV hematology analyzers. *Veterinary Clinical Pathology*. n/a(n/a).

E-mail susan.daly@thevpg.ie

Speaker Abstracts Clinical Pathology

FRIDAY 1 SEPTEMBER | 09.30-10.15

A PRACTICAL APPROACH TO TESTING FOR COMMON EQUINE ENDOCRINOPATHIES

A. Draper

Idexx Laboratories, Lower Stondon, United Kingdom

Lecture Content

With all endocrinology testing it is important to remember that hormone concentrations obtained should not be considered interchangeable between different methodologies. Laboratory derived reference intervals are important e.g. Immulite 2000XPI CLA produces lower ACTH results compared to older Immulite machines. Commonly equine hormones are assessed with chemiluminescent or radioimmunoassays. ELISA are less commonly utilised.

Diagnosis of Pituitary Pars Intermedia Dysfunction

PPID is caused by slow, progressive neurodegeneration of the hypothalamic dopaminergic neurons that typically provide inhibitory control of the pituitary pars intermedia melanotropes. This leads to hyperplasia and adenoma formation of the PI. Increased amounts of the pro-hormone pro-opiomelanocortin (POMC) are produced, which are cleaved into smaller peptides such as ACTH.

Clinical signs: Typically seen in older horses and ponies (>15yo). ~20% of >15yo and ~30% of >30yo equids are affected.

Clinical Pathology:

High glucose, TG, insulin. Increased WEC.

Increased endogenous ACTH (high pre-test probability) or exaggerated response to a TRH stimulation test (recommended in horses displaying early CS or if young). TRH may not be readily available in all countries (e.g. currently unavailable within the UK).

(Overnight dexamethasone suppression test) (Laminitis risk?).

Imaging: Advanced imaging of the pituitary gland to investigate the presence of enlargement (hyperplasia/adenoma).

As there is no definitive antemortem test for PPID, it is important to assimilate all data available to make the clinical diagnosis of disease.

Seasonality is very important when assessing endogenous ACTH, as POMCs in equids with PPID increase to a greater degree than normal equids, in the Autumn in Europe (time has the greatest specificity and sensitivity). Reference intervals for endogenous ACTH also typically contain an equivocal zone/grey zone where up to 30% of horses may fall into this zone with non-PPID causes e.g. stress, or breed.

Diagnosis of Equine Metabolic Syndrome:

EMS is a group of risk factors that are associated with development of hyperinsulinaemic-associated laminitis (HAL). Insulin dysregulation (ID) is one of the main risk factors, along with regional or generalised adiposity. Certain breeds are at higher risks than others including, ponies, Spanish breeds, gaited breeds, Morgans, WBs, & Minis. It is a complex disease or syndrome whereby genetic and environmental (e.g. exposure to diets high in NSCs) risk factors interplay to influence the risk of laminitis development in each individual.

Historical or clinical signs of EMS: resistance to weight loss, clinical laminitis, divergent hoof rings, cresty neck/SQ fat deposits, preputial or MG enlargement. May be historical or current problems. EMS can affect obese equids (Obese-EMS) and non-obese equids (Non-Obese EMS). In equids >10years old with ID, PPID status should be assessed (30% of equids with PPID have ID and HAL).

ID is defined as any combination of:

Resting hyperinsulinaemia, Postprandial hyperinsulinaemia (assessed with an oral sugar test etc.), Tissue insulin resistance (assessed by insulin tolerance test).

Resting insulin concentrations have a low diagnostic sensitivity for ID. Withhold grain for 4 hours, forage is fine. ID is typically diagnosed:

Speaker Abstracts Clinical Pathology

FRIDAY 1 SEPTEMBER | 09.30-10.15

>50uM/ml (RIA and Immulite 1000)

>75uM/ml (Immulite 2000XPI)

If clinical signs of EMS are present, and ID is not identified then dynamic testing should be performed. Resting insulin can be utilised to assess for hyperinsulinaemia associated with re-introduction or changing grazing by allowing grazing for 1-2 hours, and then measuring resting insulin to assess the insulinaemic effect of the grass.

Recommended dynamic testing:

1) Oral sugar test: needs to be performed on a starved patient, administration of 0.15 or 0.45ml/kg corn syrup PO, collect blood for insulin and glucose at 60 or 90 mins.

ID result: >63uU/ml for 0.45ml/kg test using Immulite 2000XPI

>65uU/ml for 0.45ml/kg test using RIA,

>45uU/ml for 0.15ml/kg test using RIA.

An OST can be performed to assess for ID prior to introduction or changing grazing arrangements.

Reference

- Equine Endocrinology Group 2022 Recommendations for PPID and EMS: <https://sites.tufts.edu/equineendogroup/>
- Bamford NJ, et al.. Vet J. 2023 Jun-Jul;296-297:105995. doi: 10.1016/j.tvjl.2023.105995. Epub 2023 May 18. PMID: 37207985.
- Meyer JC, et al. Equine Vet J. 2022 May;54(3):457-466. doi: 10.1111/evj.13500. Epub 2021 Sep 24. PMID: 34428330.
- McFarlane D. Vet Clin North Am Equine Pract. 2019 Aug;35(2):327-338. doi: 10.1016/j.cveq.2019.03.005. Epub 2019 May 7. PMID: 31076223.

E-mail acedf1@icloud.com

Speaker Abstracts Clinical Pathology

FRIDAY 1 SEPTEMBER | 10.45-11.30

BONE MARROW BIOPSIES: ASPIRATES VERSUS CORES

J. Harvey

University of Florida, Gainesville, United States

Lecture Content

Reasons for Bone Marrow Biopsies | Sample submissions should include results of a CBC (preferable from the same day) and reason(s) a biopsy was done. Bone marrow evaluation is indicated when peripheral blood abnormalities are detected. These include unexplained persistent neutropenia, thrombocytopenia, and poorly regenerative anemia, or a combination thereof. Bone marrow examination may also be warranted when proliferative abnormalities, including abnormal blood cell morphology or the unexplained presence of immature cells (e.g., nucleated erythroid cells in the absence of polychromasia or a neutrophilic left shift in the absence of inflammation), are present in blood. Bone marrow is sometimes examined to stage neoplastic conditions (lymphomas and mast cell tumors); to estimate the adequacy of body iron stores; to evaluate lytic bone lesions; and in determining the cause of a hyperproteinemia that may occur secondarily to multiple myeloma, lymphoma, leishmaniasis, and systemic fungal diseases. Bone marrow examination may also reveal the cause of a hypercalcemia when associated with lymphoid neoplasms, multiple myeloma, or metastatic neoplasms to bone. Benefits of Aspirate versus Core Biopsies | Aspirate biopsies are easier, faster, and less expensive to perform than are core biopsies. The identification of specific cell types is more reliably performed in aspirate smears, stained with Romanowsky-type blood stains, than in core biopsies, stained with H&E. Estimates of bone marrow cellularity require the presence of multiple, large particles in aspirate smears. Likewise, reasonable estimates of megakaryocyte numbers and iron stores require high-quality particles. The presence of myelofibrosis generally results in low cellular, blood-contaminated aspirates or acellular "dry taps." When aspiration biopsy is unsuccessful, a roll of a core biopsy specimen across a glass slide can be stained using a Romanowsky stain. This provides some information concerning the morphology of cells present. Core biopsy sections provide a more accurate way of evaluating marrow cellularity, documenting myelofibrosis and/or osteosclerosis, and examining for focal metastatic neoplasia than do aspirate smears. Although more mature nucleated erythrocytes and leukocytes can be identified with confidence, the identification of immature cell types can be difficult or impossible in core biopsies. The use of a Giemsa stain and/or a PAS stain, in addition to H&E stains, may help with cell identification. Bone Marrow Examination at Necropsy | Bone marrow aspirate preparations from dead animals are usually of poor quality, even when collected soon after death. Once clots have formed, cells will be lysed during aspiration and smear preparation. If marrow is to be collected from an animal that is to be euthanized, it is recommended that the animal is anesthetized for marrow collection, followed by the administration of the euthanasia solution. Bone marrow samples need to be collected from areas of active hematopoiesis. In adult domestic mammals, this includes sternum, ribs, and proximal ends of humerus and femur. Exfoliative cytology specimens deteriorate rapidly after death; consequently, they should be obtained as quickly as possible. Smear quality is improved by using a paintbrush to collect marrow material from a cadaver and mixing it with a bovine serum albumin solution before smear preparation. Examination and Interpretation of Biopsies | Smears and core biopsy sections should be scanned with low-power objectives to gain an appreciation of the overall cellularity and to determine the adequacy of megakaryocyte numbers. The cellularity of bone marrow is estimated by examining the proportion of cells versus fat present. Normal cellularity varies between 25% and 75% cells, with higher amounts of fat expected in older animals. As a general rule, erythroid precursors are smaller and have more nearly spherical nuclei with more condensed nuclear chromatin than granulocyte precursors at similar maturation stages. Total nucleated erythrocytic cells are differentiated from total granulocytic cells to determine M:E ratio, and comments are made regarding whether maturation is orderly or shifted towards immaturity in erythrocytic and granulocytic cell lines. Knowledge of a recent CBC is essential in interpreting M:E ratios, as is degree of marrow cellularity. The presence of normal or increased numbers of lymphocytes, plasma cells, and macrophages are reported. Cells not normally present in bone marrow including neoplastic cells and mast cells are also reported, and the amount of hemosiderin (measured as stainable iron) is described. It should be recognized that bone marrow lacks stainable iron in normal cats. The final step in evaluating a bone marrow is to provide an interpretation of the cytologic findings in light of the history, clinical findings, CBC, and results from other diagnostic tests and procedures.

Reference

Harvey, J. W. (2012). *Veterinary Hematology. A Diagnostic Guide and Color Atlas*. Elsevier Saunders.

E-mail jwharvey@ufl.edu

Speaker Abstracts Clinical Pathology

FRIDAY 1 SEPTEMBER | 11.30-12.15

CYTOLOGY GRADING SCHEMES - WHAT CAN AND CANNOT BE SAID

P. Monti

VCO lab, Hünenberg, Switzerland

Lecture Content

The importance of tumor grading is now well established, but it took a little over a century to reach this point, since it was first recognized that certain microscopic features of a tumor were associated with its biological behavior.

Tumor grading, also known as scoring, involves categorizing a specific neoplasm into different categories based on its biological behavior. During the development of a grading scheme, the association should be made with the outcome measure of interest, such as time-to-recurrence, time-to-metastasis, survival, etc..

Once developed, the grading system should assign patients to a risk category, enabling the selection of appropriate investigations and therapeutic interventions, as well as providing an accurate prognosis.

In veterinary medicine, histopathology tumor grading has been successfully applied to various tumor types for many years. However, it is still in the early stages in cytology. This presentation will describe the currently available grading systems in veterinary cytology, discuss their strengths and limitations, and provide suggestions on how to develop new grading systems in the future.

E-mail info@vcolab.ch

Speaker Abstracts Clinical Pathology

FRIDAY 1 SEPTEMBER | 16.00-17.30

CYTOLOGY MYSTERY SLIDES

C. Masserdotti

Idexx Laboratories, Brescia, Italy

Lecture Content

Introduction

Through the direct examination of cytology slides at the microscope, we would encourage the attendees to exchange opinions on interesting or unusual cytology cases and stimulate a discussion.

The session

The microscopes provided by the congress organization will allow the attendees to autonomously evaluate ten cytological smears/cases, for the entire duration of the congress, from Thursday morning to Friday afternoon. These cytology cases will then be discussed all together on Saturday morning during the main session where all the participants will be warmly invited to actively participate by asking questions, commenting the cases and, if appropriate, even criticizing the main interpretation.

All the slides will be available for examination until the end of the meeting, in order to give participants the opportunity to re-check the slides after the discussion and to compare your own interpretation with the one provided.

Enjoy your investigation!

E-mail carlo.masserdotti@gmail.com

Speaker Abstracts Joint Stream

SATURDAY 2 SEPTEMBER | 09.00-10.30

CLINICAL CASES THROUGH THE EYES OF CLINICAL AND ANATOMICAL PATHOLOGISTS

D. Gouveia Wasques ¹, F. Ferreira ²

¹ Axiom/Finn Pathologists, Newton Abbot, United Kingdom

² Axiom, Newton Abbot, United Kingdom

Lecture Content

Cytological examination is commonly deployed in small animals for the investigation of suspected neoplastic lesions, with fine-needle aspiration (FNA) being the most popular technique. This is often an easy-to-perform and rewarding approach that helps with decision-making on case management. That is especially the case for common lesions, such as mast cell tumours, histiocytomas, perivascular wall tumours, among others.

Histopathology is often seen as the "gold-standard" of diagnosis of such lesions, although realistically it might be more reasonable to interpret histopathology and cytopathology as being complementary diagnostic tools. In this context, the systematic study of cytological:histological correlation cases is a useful quality-control measure that can be employed to assess possible explanations for discrepancies, as well as possible modifications of diagnostic "rules" so as to correct and improve the predictive power of these tests.

The aim of this presentation is to steer away from common and non-problematic lesions, and instead focus on more challenging lesions, with the use of cytological:histological correlation analysis as a tool to better understand the spectrum of morphological appearance of these lesions. This will include unusual lesions as well as lesions in which the cytological interpretation is particularly challenging due to a variety of factors (e.g. equivocal malignancy, suboptimal sample yield, unusual clinical history). All cases will be open to discussion, and any input from the audience will be welcome and encouraged.

E-mail danilo.waques@axiomvetlab.co.uk

Speaker Abstracts Veterinary Pathology

SATURDAY 2 SEPTEMBER | 11.00-12.30

ANATOMIC PATHOLOGY MYSTERY SLIDE SESSION - SECOND OPINION ROUND

D. Psalla², **E. Riccardi**¹

¹ *IDEXX Laboratories Ltd, Wetherby, United Kingdom*

² *Aristotle University, School of Veterinary Medicine, Thessaloniki, Greece*

Lecture Content

This year, the Anatomic Pathology Mystery Slide Session scheduled on Saturday September 2nd at the Joint Congress of the ESVP/ECVP/ESVCP/ECVCP in Lisbon, is organized as a "second opinion round". The topic of the session is open. Participants are welcome to submit diagnostic challenges; unresolved/cold cases; cases that occur "once in a lifetime"; or things people wouldn't believe in, and they want to share with friends and colleagues.

The Mystery Slide session would like to be an informal "ring", where an open discussion on difficult or unusual cases occurs and colleagues can be inspired by. Selected cases will be presented in 8 minutes. A 4-minute discussion will follow.

The organizers and chairs of the session are Dr. Elena Riccardi (IDEXX Laboratories, Wetherby, UK) and Prof. Dimitra Psalla (Aristotle University of Thessaloniki).

A brief history and the scanned slides of each case will be available to Congress attendees for review before the session.

E-mail elena-riccardi@idexx.com

Oral Abstracts Veterinary Pathology

SESSION 1: MISCELLANEOUS
THURSDAY 31 AUGUST | 11.00-11.15

PATHOLOGICAL FEATURES OF AN OUTBREAK OF A NON-VIRAL PANCYTOPAENIA IN CATS

J. Williams, K. O'Brien, D. Yaffy, J. Irving, T. Dolensek, Z. Miller, C. Dubeau, E. Holmes and A.K. Jasensky
Pathobiology and Population Science, Royal Veterinary College, London, GB

Introduction

In spring 2021 there was a sudden rise in feline pancytopenia in the UK causing death of several hundred cats that was epidemiologically linked to diet. Here we communicate detailed diagnostic findings of this pancytopenia from the anatomic and clinical pathology groups at the RVC.

Materials and Methods

Cases submitted between April and August 2021 were included if cats showed bicytopenia/pancytopenia during presentation or hospitalisation on a sample submitted to our lab or based on an external report when submitted for post-mortem examination only. Cases with confirmed infectious or neoplastic causes were excluded.

Results

Haematology (n=31), biochemistry (n=30), bone marrow aspirates (n=16), core biopsies (n=9) and post-mortems (n=18) of 36 cats were included. Cats often came from multi-cat households with five sibling pairs represented. Cats exhibited profound bicytopenia/pancytopenia with severely hypocellular bone marrow. Necropsy findings included pale mucous membranes, variable jaundice, widespread petechial and ecchymotic haemorrhages, melena, lymphoid depletion, tonsillar haemorrhage/necrosis, laryngeal oedema/necrosis, extra-medullary haematopoiesis, centrilobular degeneration and bile stasis of the liver, and variable biliary hyperplasia. Differentials considered included viral, idiopathic and toxic causes. However, many cats had been tested negative for FeLV, FIV, and parvovirus. The bone marrow changes and other pathological features were therefore suggestive of a toxic aetiology such as mycotoxins.

Conclusions

Further investigations by others showed mycotoxin concentrations greater than the European Commission guidance for dry cat foods in the diet. Despite high production standards for animal feed, this incident highlights the need for food surveillance, and multidisciplinary team-based investigation upon unusual pathological findings.

Oral Abstracts Veterinary Pathology

SESSION 1: MISCELLANEOUS
THURSDAY 31 AUGUST | 11.15-11.30

DIAGNOSTIC PITFALLS IN CLINICAL MEDICAL DEVICE STUDIES: A CASE STUDY ANALYSIS

O.K. Richard, R. de Miguel, R. Vallejo, K. Kegler, P. Ortega, N. Warfving and K. Weber

AnaPath Services GmbH, Liestal, CH

Introduction

Medical devices undergo numerous evaluations to obtain market registration. One of them is the ISO 10993, which describes a histopathological scoring system for the evaluation of degradable materials. It considers inflammatory cells, necrosis, fibrosis, neovascularization and fatty infiltrates. The purpose of this work was to demonstrate how pathologists apply this scoring differently and that careful interpretation of histopathological findings is important.

Materials and

Histologically, the biopsies from six human patients with the same spine-stabilizing implant but different implantation durations, were analyzed. The tissue biopsies were cut to obtain four sectional planes, embedded in paraffin, sectioned and stained with H&E and Masson Trichrome. The biopsies were evaluated by three different pathologists following the ISO 10993-6 guideline scoring scheme.

Results

The study pathologist interpreted the basophilic edges of the biopsies with loss of cellular detail and tissue architecture as necrosis and the dense fibrous connective tissue as fibrosis. Peer review by two other pathologists led to the conclusion that the fibrous connective tissue originated from ligaments and did not represent fibrosis while the tissue basophilia was an extraction artefact caused by electro-cautery.

Conclusions

Histological lesions that are straightforward to one pathologist may be interpreted differently by another pathologist. For a comprehensive evaluation of clinical samples, it is important to obtain all clinical data, such as precise localization, information on sample collection and macroscopic findings. Additionally, advanced knowledge of the histology of various tissues and practice in medical device evaluation are essential.

Oral Abstracts Veterinary Pathology

SESSION 1: MISCELLANEOUS
THURSDAY 31 AUGUST | 11.30-11.45

EFFECT OF AGE ON THE OCCURRENCE OF ENDOMETRIAL ADENOCARCINOMA, PYOMETRA AND ENDOMETRIAL CYSTIC HYPERPLASIA IN CATS: A DESCRIPTIVE STUDY

A. Jordão*, **H. Vilhena*†**, **R. Payan-Carreira‡** and **M. dos Anjos Pires***

**Animal and Veterinary Investigation Centre (CECAV) AL4Animals, ECAV, University of Trás-os-Montes e Alto Douro, Vila Real, PT, †Departamento de Medicina Veterinária, Escola Universitária Vasco da Gama, Coimbra, PT and ‡Departamento de Medicina Veterinária, Comprehensive Health Research Centre, Escola de Ciências e Tecnologia, Universidade de Évora, Évora, PT*

Introduction

Feline endometrial adenocarcinoma (FEA) is a malignant epithelial neoplasia traditionally considered rare in domestic animals, except in rabbit and cow. Nevertheless, recent studies in cats consider this neoplasm as more frequent than it was reported, which suggests that it has been underdiagnosed. Several FEA cases were described as associated with pyometra, and the hormones associated with the development of endometrium cystic hyperplasia (ECH) may also influence carcinogenesis and tumour progression of the endometrium. This study aimed to correlate FEA and concomitant diseases (pyometra and ECH) with age.

Materials and Methods

In a period of 9 years, 182 genitals obtained by elective or clinically driven ovariohysterectomy were submitted to histopathological analysis, and classified as normal, with ECH, pyometra, and/or FEA.

Results

We observed that 38% of the animals did not present disease and 62% had one or more uterine diseases. The most prevalent was pyometra (52%), followed by FEA (39%), and finally ECH (9%). 51% of cases of FEA occurred between 3 and 9 years of age, the same age range was observed for the pyometra. In contrast, ECH mostly occurred in cats aged over 10 years. In 60% of cases of FEA, other uterine diseases were observed, with pyometra being the most common (in 43% of cases).

Conclusions

FEA is a disease with the highest incidence in middle-aged to geriatric females as the pyometra, and ECH is most common in older cats.

Acknowledgements: This work was supported by the projects UIDP/CVT/00772/2020 and LA/P/0059/2020 funded by the Portuguese Foundation for Science and Technology (FCT).

Oral Abstracts Veterinary Pathology

SESSION 2: EXOTICS, ZOO AND WILD ANIMALS

THURSDAY 31 AUGUST | 11.00-11.15

CETACEAN NEUROBRUCELLOSIS: PATHOLOGICAL AND IMMUNOLOGICAL COMPARATIVE ASPECTS WITH HUMANS AND ANIMAL MODELS

A. Rebollada-Merino^{*,†}, F. Giorda[‡], M. Pumarola[§], L. Martino[¶], A. Gómez-Buendía^{*,*}, U. Romani-Cremaschi^Δ, L. Domínguez^{*,*}, M. Domingo[¶], C. Grattarola[‡] and A. Rodríguez-Bertos^{*,*}

^{*}VISAVET Health Surveillance Centre and [†]Department of Internal Medicine and Animal Surgery, Faculty of Veterinary Medicine, Complutense University of Madrid, Madrid, ES, [‡]OIE Collaborating Centre for the Health of Marine Mammals, Istituto Zooprofilattico Sperimentale del Piemonte, Liguria e Valle d'Aosta, IT and [§]Unitat de Patologia Murina i Comparada, Departament de Medicina i Cirurgia Animals, [¶]Departament de Sanitat i Anatomia Animals and ^{*,*}VISAVET Health Surveillance Centre, ^ΔDepartment of Animal Health, ^ΔVeterinary Department, Mundomar, Department of Pharmacology and Toxicology, Faculty of Veterinary Medicine and Unitat Mixta d'investigació IRTA-UAB en Sanitat Animal, Centre de Recerca en Sanitat Animal (CReSA), Universitat Autònoma de Barcelona and Department of Internal Medicine and Animal Surgery, Faculty of Veterinary Medicine, Complutense University of Madrid, ES

Introduction

Brucellosis (*Brucella* spp.) is a zoonosis that causes multisystemic disease in humans. Brucella infection of the central nervous system (CNS), or neurobrucellosis, occurs in up to 25% of human patients. *Brucella ceti* causes brucellosis in mysticete and odontocete cetaceans worldwide. Interestingly, CNS involvement by *B. ceti* has been reported in particular in the striped dolphin (*Stenella coeruleoalba*). Thus, neurobrucellosis appears to be a condition shared by cetaceans and humans. However, the common aspects of the immune response in neurobrucellosis in both species, and animal models of brucellosis have not been studied.

Materials and Methods

Twenty-one cases of neurobrucellosis (*Brucella ceti*) in striped dolphins diagnosed over a ten-year period (2012-2022) at two diagnostic laboratories were retrospectively evaluated. *Brucella* infection was confirmed by bacterial culture and PCR. For each case, histological lesions were assessed evaluating 19 parameters. In addition, the immunohistochemical expression of *Brucella* antigen, and of a selection of inflammatory cell markers (Iba-1, CD3, CD20) and cytokines (TNF- α , IFN- γ , IL-1 β , IL-2, IL-6) were investigated.

Results

All animals exhibited mononuclear inflammatory infiltration of leptomeninges, ependyma and/or choroid plexus, comprised of macrophages/microglia (Iba-1+), T cells and B cells in equal proportions. Increased TNF- α , IFN- γ and IL-2 expression was observed, indicating a proinflammatory response stimulating macrophages and T cells.

Conclusions

Cetacean and human neurobrucellosis are pathologically and immunologically similar. Disease surveillance in cetaceans is valuable for diagnosing threats to several endangered species but can also serve to increase the knowledge of the immunology of infectious diseases, particularly brucellosis, under a One Health approach.

Oral Abstracts Veterinary Pathology

SESSION 2: EXOTICS, ZOO AND WILD ANIMALS

THURSDAY 31 AUGUST | 11.15-11.30

ERYSIPELAS IN A DOLPHIN WITH UNUSUAL CENTRAL NERVOUS SYSTEM INVOLVEMENT. WHAT DO PIGS AND DOLPHINS HAVE IN COMMON?

L. Martino*, **B. Serrano***, **A. Cobos†**, **J. Alomar***, **L. Perez‡**, **M.L. Abarca*‡** and **M. Domingo***

**Departament de Sanitat i Anatomia Animals and †Unitat Mixta d'Investigació IRTA-UAB en Sanitat Animal, Centre de Recerca en Sanitat Animal (CReSA), Campus de la Universitat Autònoma de Barcelona (UAB) and ‡Facultat de Veterinària de Barcelona, Universitat Autònoma de Barcelona (UAB), Bellaterra, ES*

Introduction

Erysipelas, caused by *Erysipelothrix rhusiopathiae*, is considered a re-emerging disease in pigs and is increasingly reported in free-ranging cetaceans. We describe a case of erysipelas in a common bottlenose dolphin and comparatively review the pathological features in free-ranging cetaceans and pigs.

Materials and Methods

In October 2022, a common bottlenose dolphin (*Tursiops truncatus*) stranded in Vilassar de Mar (Catalonia) showing skin lesions consistent with "diamond skin disease", a shared condition of swine and cetaceans. The dolphin was necropsied in the Veterinary School of UAB. Thorough bacteriology and histopathology were conducted. A bibliographic search regarding pathological findings in cetaceans and pigs was performed.

Results

In our case, relevant gross lesions included multifocal generalised rhomboidal, raised cutaneous lesions corresponding to a suppurative dermatitis. The meninges showed diffuse intense reddening. Histology revealed severe neutrophilic vasculitis affecting exclusively the leptomeningeal arteries and veins associated with abundant Gram-positive intramural bacteria and haemorrhage. *E. rhusiopathiae* was isolated from many organs. In cetaceans, common reported lesions include cavitory effusions, lymphadenomegaly, generalized congestion, thrombosis and haemorrhages, and bacterial emboli. Vasculitis and haemorrhages in the brain have not been reported, while in pigs they are described. Rhomboidal skin lesions are only seen in some cetacean species. Vegetative endocarditis and fibrinous arthritis, well-known in pigs, have not been reported in cetaceans so far.

Conclusions

This is the first description of erysipelas with severe involvement of leptomeningeal vessels in a free-ranging cetacean. As in swine, cutaneous lesions are characteristic and useful for diagnosis in some species.

Oral Abstracts Veterinary Pathology

SESSION 2: EXOTICS, ZOO AND WILD ANIMALS

THURSDAY 31 AUGUST | 11.30-11.45

SPONTANEOUS OUTBREAK OF MYCOBACTERIUM TUBERCULOSIS COMPLEX IN LABORATORY CYNOMOLGUS MONKEYS (*MACACA FASCICULARIS*)

K. Kegler*, **F.J. Mayoral†**, **C. Vallejo†**, **R. Sanchez†**, **R. de Miguel***, **P. Ortega***, **O.K. Richard***, **R. Vallejo***, **K. Weber***

*AnaPath Services GmbH, Switzerland, and †AnaPath Research S.AU, Spain

Introduction

Despite efforts to control the incidence of tuberculosis in nonhuman primates (NHPs), outbreaks continue to occur resulting in human exposure, animal losses, disruption of research, and costs related to control the disease. Mycobacteria tuberculosis complex (MTBC) infected monkeys usually lack clinical signs and the disease becomes evident during necropsies. This highlights the frequency of false-negative results of standardized tuberculosis tests. Here we describe an outbreak of MTBC in Cynomolgus monkeys (*Macaca fascicularis*) in a test facility.

Materials and Methods

Fourty monkeys from two different studies were necropsied in May 2023. Samples from animals with suspected tuberculosis were collected and processed for histopathology, culture, qPCR, next generation sequencing (NGS).

Results

All monkeys were tuberculin skin test (TST) negative during quarantine. At the test facility, animals were clinically healthy except for one male monkey that presented with a fistulizing abscess on the right inguinal area. Necropsy revealed that 5 out of 40 animals (12%, one male and 4 female) had multifocal, different sized granulomas in lungs, tracheobronchial lymph nodes, liver, spleen, and kidneys. The right inguinal abscess of the male monkey was continuous to the superficial inguinal lymph node. Samples from the lungs and the inguinal abscess were qPCR-positive for MTBC.

Conclusions

Although Cynomolgus monkeys usually do not present with evident clinical signs and show a more chronic course, the presence of an abscess in the inguinal region should raise the suspicion of MTBC infection. Five TST-negative animals had tuberculosis, underscoring the importance of developing improved diagnostic tests for surveillance.

Oral Abstracts Veterinary Pathology

SESSION 3: POSTER FLASH
THURSDAY 31 AUGUST | 11.45-11.50

DIFFERENTIAL DIAGNOSIS FOR HEPATIC DISEASE AS THE CAUSE OF SERUM ALAT INCREASE; MYOPATHY OF THE SCHAPENDOES BREED DOG

P. Syrjä*, **T. Jokinen†**, **M. Kaukonen†,§** and **H. Lohi§,†**

**Department of Veterinary Biosciences, Faculty of Veterinary Medicine, University of Helsinki, Helsinki, FI and †Department of Equine and Small Animal Medicine, Faculty of Veterinary Medicine, University of Helsinki, ‡Department of Clinical and Medical Genetics, Faculty of Medicine, University of Helsinki and §Folkhälsan Research Center, Helsinki, FI*

Introduction

Dogs of the Schapendoes breed were presented with progressive exercise and heat intolerance. Serum ALAT was markedly elevated. Therefore, the dogs were subjected to liver biopsy. Liver lesions explaining the enzyme elevation were not found, thus the dogs were further investigated. The present study determined the clinical and histopathological phenotype of this disease and investigated its genetic background.

Materials and Methods

Four symptomatic Schapendoes dogs were clinically examined, euthanized, and necropsied with owner's consent. Clinical investigations included neurological examination, CBC, blood biochemistry, electromyography and motor nerve conduction velocity studies. Postmortem examinations included myofiber typing by IHC, Kongo red stain of vascular lesions, and Rubeinic acid stain for copper of the liver. DNA samples from 20 cases and 16 controls were genotyped with 220,853 markers. A genome-wide association study (GWAS) and whole genome sequencing (WGS) were performed.

Results

Progressive exercise and heat intolerance, fatigue and markedly elevated CK, ALAT, ASAT enzyme levels were the main clinical findings in all four dogs. Electrodiagnostic findings indicated a myopathy. Postmortem examination revealed chronic polyphasic myopathy, predominantly affecting type I myofibers. Three dogs showed mild vascular amyloidosis, two had mild copper-associated chronic hepatitis. Pedigree analysis suggested autosomal recessive (AR) inheritance. GWAS and filtered WGS data identified a causal candidate variant in a known myopathy gene.

Conclusions

A chronic progressive myopathy affects the Schapendoes breed, causing exercise and heat intolerance, increased serum ALAT, ASAT and CK enzymes. Genetic investigations support AR inheritance. Segregation analysis to validate the identified candidate variant is the next step.

Oral Abstracts Veterinary Pathology

SESSION 3: POSTER FLASH
THURSDAY 31 AUGUST | 11.50-11.55

BEYOND ANGIOGENESIS: UNVEILING VESSEL CO-OPTION AND VASCULOGENIC MIMICRY IN HIGHLY MALIGNANT CANINE CANCER

G. Valdivia, C. Colomina, L. Barreno, Á. Alonso-Diez and L. Peña

Dept. of Animal Medicine, Surgery and Pathology; Mammary Oncology Unit, Veterinary Teaching Hospital, Veterinary Medicine School, Complutense University of Madrid, Madrid, ES

Introduction

Angiogenesis (Ag) is crucial for tumour progression and metastasis. Lesser-known forms of tumour nutrition, such as vasculogenic mimicry (VM) and vessel co-option (VCO), are associated with poorer prognosis and resistance to anti-angiogenic treatments in human oncology. In VM, highly malignant cancer cells line newly formed vascular-like channels. Conversely, in VCO, tumour cells survive by hijacking pre-existing blood vessels of the invaded tissue. Despite its significance, VCO has not been previously documented in veterinary medicine.

Materials and Methods

We retrospectively analyzed 98 necropsied dogs with metastatic cancer (metastases in lung, 33; liver, 7; brain, 2). VM and VCO were histologically assessed using HE stained sections, following previously established criteria. PAS, Masson's trichrome, reticulin stains, and CD31 immunohistochemistry were used to evaluate VCO in the primary tumour or metastases.

Results

Of the 98 cases, 19 (19.4%) and 11 (11.2%) exhibited VM and VCO, respectively. VM was detected irrespective of primary vs metastatic location. VCO was identified in pulmonary (9/33, 27.3%), hepatic (1/7, 14.3%), and brain (1/2, 50.0%) metastases, but not in primary tumours. In the lungs, three VCO patterns were found: alveolar (7/9), lepidic (1/9), and interstitial (1/9). VCO in liver and brain metastases exhibited a perivascular pattern. VM and VCO co-existed only in two cases.

Conclusions

This study, for the first time in veterinary medicine, documents the existence of VCO and its coexistence with VM. Due to their implication in malignancy and prognosis, the identification of VM and VCO should be included in pathology reports.

Oral Abstracts Veterinary Pathology

SESSION 3: POSTER FLASH
THURSDAY 31 AUGUST | 11.55-12.00

A ONE PATHOLOGY, MULTICENTRE PORTUGUESE APPROACH TO THYROID TUMOURS OF DOGS AND CATS

T.B. Gaspar^{*†}, I. Borges[‡], S. Canberk^{*§}, A. Monteiro^{*¶}, J. Catarino^{*‡}, M. Pinto^{*}, E. Teixeira^{*Δ}, A. Canadas-Sousa^A, S. Branco^B, D. Silva^C, H. Lima de Carvalho[‡], P. Faísca^{*‡}, M. Peleteiro^{D,E}, K. Pinello^F, J. Niza-Ribeiro^F, M. Sobrinho-Simões^{*G}, I. Pires^{H,I}, P. Soares^{*J}, and C. Tavares^{*K}

**Institute of Molecular Pathology and Immunology of the University of Porto (Ipatimup), Instituto de Investigação e Inovação em Saúde (i3S), University of Porto, Porto, PT; †Vasco da Gama Research Center (CIVG), Vasco da Gama University School (EUVG), Coimbra, PT; ‡Cedivet, Laboratório Clínico Veterinário, Porto, PT; §School of Medicine and Biomedical Sciences (ICBAS), University of Porto, Porto, PT; ¶Universidade de Trás-os-Montes e Alto Douro (UTAD), Vila Real, PT; ΔDNAtech, Veterinary Laboratory, Lisbon, PT; AFaculdade de Medicina Veterinária, Universidade Lusófona, Centro Universitário de Lisboa, Lisbon, PT; ΔFaculty of Medicine of the University of Porto (FMUP), PT; ΔDepartment of Pathology and Molecular Immunology, Porto, PT; BMED-Mediterranean Institute for Agriculture, Environment and Development & CHANGE-Global Change and Sustainability Institute & Departamento de Medicina Veterinária, Escola de Ciências e Tecnologia, Évora University, Évora, PT; CSegalab, Laboratório de Sanidade Animal e Segurança Alimentar, Póvoa de Varzim, PT; DCentre for Interdisciplinary Research in Animal Health (CIISA-AL4Animals), Faculty of Veterinary Medicine, University of Lisbon, Lisbon, PT; EVETPATLAB, Lisbon, PT; FVet-OncoNet, Population Studies Department, School of Medicine and Biomedical Sciences (ICBAS), University of Porto, Porto, PT; GDepartment of Pathology, Centro Hospitalar Universitário de São João (CHUSJ), Porto, PT; HDepartamento de Ciências Veterinárias, Universidade Trás-os-Montes e Alto Douro (UTAD), Vila Real, PT; ICECAV-Centro de Ciência Animal e Veterinária, Universidade Trás-os-Montes e Alto Douro (UTAD), Vila Real, PT; IDepartment of Pathology, Faculty of Medicine of the University of Porto (FMUP), Porto, PT; KTOXRUN-Toxicology Research Unit, University Institute of Health Sciences, CESPU, CRL, Gandra, PT*

Introduction

Thyroid tumours are the most common endocrine tumours of dogs and cats. Feline thyroid tumours are essentially functional adenomas curable with thyroidectomy, whereas most canine thyroid tumours are non-functional carcinomas either unresectable or recurrent within two years in up to 50%. The oncobiology of these tumours remains unclear, but investigating this aspect could contribute to the development of targeted therapies. We aimed to characterise a series of thyroid tumours of dogs and cats, focusing on correlating histopathological findings with molecular alterations.

Materials and Methods

Sixty-five canine and fourteen feline thyroid tumours from seven diagnostic centres were re-evaluated using HE stained slides by a team of veterinary and human pathologists following the most recent WHO criteria. The MAPK/ERK activation status was assessed through phospho-ERK immune expression analysis.

Results

In dogs, 60 (92%) were carcinomas; most from pure-breeds and of compact-cellular (48%), follicular (23%), and mixed compact-follicular (17%) type. In cats, 11 (79%) were adenomas; all from European shorthairs and mostly follicular (64%). We found a lack of a clear threshold that could distinguish between mixed and non-mixed histotypes. In canine carcinomas, the compact pattern was significantly associated with a higher mitotic count (MC); higher MC and larger tumours tended to be correlated with a lower phospho-ERK expression.

Conclusions

Non-mixed histotypes represented more than half of the cases of our series. MAPK/ERK activation was not associated with more aggressive phenotypes. We propose the use of MC for stratifying well-differentiated histotypes. Unveiling the PI3K/AKT activation status is the next crucial step.

Oral Abstracts Veterinary Pathology

SESSION 3: POSTER FLASH
THURSDAY 31 AUGUST | 12.00-12.05

NUCLEAR MORPHOMETRY AND EXPRESSION OF CK20, P53 AND KI-67 IN THE DIAGNOSIS OF BLADDER TRANSITIONAL CELL CARCINOMAS IN DOGS

P. Ferreira de Oliveira, H. Almeida de Souza Cruz, S.R. Kleeb and J.G. Xavier

Patologia Ambiental e Experimental, Universidade Paulista, São Paulo, BR

Introduction

Canine transitional cell carcinomas (TCC) share many characteristics with human invasive urinary bladder TCC in terms of incidence, histopathology and biological behaviour. In humans, several markers have been proposed to monitor this disease, including oncogene products, proliferation markers and cell-cycle-related proteins. However, there are only few studies on this subject in canine urothelial lesions. This study aimed to assess the relationship of morphometric features and immunohistochemical markers with the histological diagnosis in canine bladder tissue.

Materials and Methods

In this retrospective study, 25 samples of canine urinary bladder previously diagnosed as normal (n=5), cystitis (n=5), transitional cell carcinoma (TCC) (n=15), were subjected to a morphometric analysis, using a digital computerized analysis system (Metamorph®), evaluating urothelial nuclear area and perimeter. In addition, cytokeratin 20 (CK20), p53 and Ki-67 expression were examined by immunohistochemistry.

Results

There was a statistically significant difference regarding the nuclear area and perimeter of urothelial cells between non-neoplastic and neoplastic samples (Student's T test, $p < 0.0001$). Immunoeexpression of CK20 was scarce in TCC (1/10). In contrast, p53 expression was observed only in neoplastic cells. In TCCs, there was a qualitative and quantitative change in the proliferative profile evidenced by the more frequent and topographically wide immunoeexpression of Ki-67. There was no relationship between histological parameters, such as muscle invasion and tumour embolization with immunohistological findings.

Conclusions

Nuclear morphometry and immunohistochemical parameters, as p53 and Ki-67 expression, can contribute to the characterization of canine transitional cell carcinomas.

Oral Abstracts Veterinary Pathology

SESSION 3: POSTER FLASH
THURSDAY 31 AUGUST | 12.05-12.10

DETECTION OF PD-L1, PD-1, AND CTLA-4 BY RNA IN SITU HYBRIDIZATION IN CANINE ORAL MELANOCYTIC NEOPLASMS AND THEIR MICROENVIRONMENT

G. Foiani*, **E. Melchiotti***, **S. Iussich†**, **I. Porcellato‡**, **C. Brachelente‡**, **K. Capello***, **D. Giacobino†**, **E. Morello†**, **M. Martano§** and **M. Vascellari***

**Istituto Zooprofilattico Sperimentale delle Venezie, Padua, IT, †University of Turin, Grugliasco, IT, ‡University of Perugia, Perugia, IT and §University of Parma, Parma, IT*

Introduction

The programmed death-1 (PD-1)/programmed death ligand-1 (PD-L1) and cytotoxic T-lymphocyte antigen-4 (CTLA-4) are recognized as clinically important immune checkpoints in human cutaneous melanoma. This study assessed the expression of PD-L1, PD-1, and CTLA-4 in canine oral melanocytic neoplasms, to gain insight into their role and establish their potential prognostic value.

Materials and Methods

Automated RNAscope® in situ hybridization was performed on 24 melanomas and 5 melanocytomas using anti-canine PD-L1, PD-1, CTLA-4 probes. Positive signals in tumour cells were scored (0-4) according to a semiquantitative system and assessed by image analysis (QuPath). Collected clinico-pathological features include the mitotic count, nuclear atypia, Ki67 index, CD3+/CD20+ tumour-infiltrating lymphocytes (TILs) grade, and outcome.

Results

PD-L1 was expressed in all melanocytic neoplasms (score 1-3), especially at the host-tumour interface. PD-1 signals were detected in 13/24 melanomas (score 1-2), and CTLA-4 in 18/24 melanomas and 2/4 melanocytomas (score 1). The semi-quantitative score and automated analysis were correlated. All three immune checkpoints were expressed by TILs and PD-L1 / PD-1 scores tended to increase with higher TILs grade. There was no association among RNAscope® scores and the overall survival or disease free interval. However, scores of PD-L1 ≥ 2 and PD-1 ≥ 1 were often associated with mitotic count ≥ 4 and nuclear atypia ≥ 30 .

Conclusions

PD-L1/PD-1 and CTLA-4 are expressed by canine melanocytic tumour cells and their microenvironment, suggesting them as key players in immune evasion of these neoplasms. Our study represents a first step for the possible development of immunotherapy strategies in dogs, also as a potential preclinical model for humans.

Oral Abstracts Veterinary Pathology

SESSION 3: POSTER FLASH
THURSDAY 31 AUGUST | 12.10-12.15

METHYLATION ANALYSIS OF LINE-1 ELEMENTS AND MORPHOLOGICAL NUCLEAR PARAMETERS IN THE DIFFERENTIAL DIAGNOSIS OF CUTANEOUS MELANOCYTIC TUMORS IN DOGS

V. Marques de Oliveira, C. Cellerio Rufino, N. Piotto de Aquino, C. Sabauda Alves, R.A. da Silva and J.G. Xavier
Patologia Ambiental e Experimental, Universidade Paulista-UNIP, São Paulo, BR

Introduction

Recently, epigenetic changes have been proposed as biomarkers for cancer detection, tumour prognosis, and prediction to treatment response. LINE-1 (L1) retrotransposons are widespread repetitive elements in the human genome. These L1 source elements are usually transcriptionally repressed, but epigenetic changes that occur in tumours may promote their expression and allow them to retrotranspose. There are few reports regarding DNA methylation in canine malignant melanoma. Melanocytic neoplasms account for 4-20% of all cutaneous neoplasms in dogs. The borderline between malignant melanomas and melanocytomas may be broad, and the cytologic characteristics contain a degree of uncertainty. The aim of this retrospective study was to evaluate nuclear morphological parameters and epigenetic alterations in order to distinguish between the benign and malignant neoplastic populations.

Materials and Methods

Eighteen canine cutaneous samples, previously diagnosed as melanocytomas and malignant melanomas were selected. Morphological nuclear parameters were evaluated. DNA extractions were performed and LINE-1 methylation patterns were quantified by qPCR after previous treatment with T4-BGT, MspI and HpaII enzymes.

Results

Nucleolar frequency, nuclear score and nuclear perimeter showed a statistically significant difference between benign and malignant tumours ($p < 0,004$, Student T test). There was a significant difference between the groups with the 5-meC/5-hmeC ratio, with hypermethylation in melanomas.

Conclusions

The results indicate that increase in nucleolar frequency, nuclear score, nuclear perimeter and LINE-1 hypermethylation are associated with a malignant behaviour in canine cutaneous melanocytic neoplasms.

Oral Abstracts Veterinary Pathology

SESSION 3: POSTER FLASH
THURSDAY 31 AUGUST | 12.15-12.20

IMMUNO-ONCOLOGICAL CHARACTERIZATION OF CANINE CUTANEOUS HISTIOCYTOMA BY GENE EXPRESSION PROFILING UTILIZING NANOSTRING NCOUNTER® RNA HYBRIDIZATION TECHNIQUE

A.K. Langenhagen, A.F.H. Haake and A.D. Gruber

Institute of Veterinary Pathology, Freie Universität Berlin, Berlin, DE

Introduction

The stereotypic regression of canine cutaneous histiocytoma (CCH) is a unique phenomenon of broader oncomechanistic interest. However, its mechanisms have only partially been investigated. In this study, we asked which specific immuno-oncological dynamics may underlie regression of CCH on mRNA level. In addition to general pathways such as apoptosis, proliferation and hypoxia, spatiotemporal dynamics of expression of co-stimulatory CD80 and CD86 molecules were investigated.

Materials and Methods

HE-stained FFPE sections from 35 CCH were staged and RNA isolated for nCounter® Analysis System, an RNA hybridisation assay which allows 800 genes to be analysed. 46 immuno-oncologically relevant pathways were compared between stages 1, 2 and 3. Expression of CD80 and CD86 was measured by in situ hybridization followed by quantitation of positive tumour cells, and finally compared to 3 canine histiocytic sarcomas (HS) samples.

Results

Surprisingly, no significant differences were found for any of the pathways tested between the three stages. Over time, CD80 displayed an increase in expression from bottom to top, while CD86 remained unchanged (average: 95.1% expressing tumour cells). Overall, expression of CD80 in CCH (73.3%) was similar to HS (62.1%), while CD86 was significantly less expressed in HS (57.6%) compared to CCH.

Conclusions

Our data reveal that major immuno-oncological pathways are seemingly not regulated at mRNA level during the course of CCH. We speculate that key processes leading to tumour regression may occur at an earlier time point than examined here. Our data further support a role of co-stimulatory molecules in CCH regression involving cytotoxic lymphocytes.

Oral Abstracts Veterinary Pathology

SESSION 3: POSTER FLASH
THURSDAY 31 AUGUST | 12.20-12.25

STREAMLINING MICROSCOPE-BASED KI-67 INDEX ESTIMATION: LET'S MAKE IT SIMPLE!

S. Valente^{*}, J. Matias[†], S. Carvalho[‡], H. Pissarra[‡], P. Faísca^{§,¶} and M.C. Peleteiro^{‡,*}

^{}URANOLABPT, Sintra, PT, [†]Faculty of Sciences, University of Lisbon, [‡]Centre for Interdisciplinary Research in Animal Health (CIISA - AL4Animals), Faculty of Veterinary Medicine, University of Lisbon, and [§]Faculty of Veterinary Medicine, Lusófona University, Lisbon, PT and [¶]Instituto Gulbenkian de Ciência, Oeiras, PT*

Introduction

Pathologists are requested to provide an accurate mast cell tumour (MCT) proliferation index (PI) based on Ki67 immunohistochemistry. This presentation proposes a straightforward and microscope-based method for Ki67 index estimation in MCTs that requires no supplementary equipment.

Materials and Methods

Ten high-power field (HPF) photographs of twenty MCTs were taken with a mobile phone camera and mast cells counted with Image J. Mast cell counts underwent equal-width binning, resulting in the establishment of three classes according to cell concentration. PI was then estimated counting Ki67 positive cells (Mib1, DAKO) in ten HPF. This system was applied to 132 MCTs. Moreover, the QuPath software was employed to validate the Ki67 index in five randomly selected MCTs. The Wilcoxon Signed Rank Test assessed statistical discrepancies between measurements.

Results

The mast cell counts in ten HPF of compact, median compact and disperse MCTs were submitted to frequency analysis and the mean value in each group was rounded to practical values, which were, respectively, 8000, 4000 and 2500. These values were used to determine the percentage of Ki67 positive cells. The PI values for the 132 MCTs were then categorised in three classes: low (0-3.9), median (4-7.9) and high (>8). Within the highest PI cases (N=6), two showed PI-mitotic index disparities (33.3%). The QuPath analysis aligned with our measurements, showing no significant discrepancies ($p = 0.23$).

Conclusions

The system for PI determination suggested, requiring little more than a microscope, is reliable and not associated with additional costs.

Oral Abstracts Veterinary Pathology

SESSION 3: POSTER FLASH
THURSDAY 31 AUGUST | 12.25-12.30

ARTIFICIAL INTELLIGENCE PREDICTS THE C-KIT-11 MUTATIONAL STATUS OF CANINE CUTANEOUS MAST CELL TUMOURS THROUGH THEIR PHENOTYPE IN HE STAINED HISTOLOGICAL SLIDES

C. Puget^{*}, J. Ganz[†], J. Ostermaier[†], T. Konrad^{*}, E. Parlak[‡], C.A. Bertram[‡], K. Breininger[§], M. Kiupel[¶], M. Aubreville[†] and R. Klopfleisch^{*}

^{}Institute of Veterinary Pathology, Free University Berlin, Berlin, DE, [†]Fakultät Informatik, Technische Hochschule Ingolstadt, Ingolstadt, DE, [‡]Department of Pathobiology, University of Veterinary Medicine, Vienna, AT, [§]Department Artificial Intelligence in Biomedical Engineering, Friedrich-Alexander-University, Erlangen-Nuremberg, DE and [¶]College of Veterinary Medicine, Michigan State University, Michigan, US*

Introduction

Cutaneous mast cell tumours (MCT) account for 7-21% of skin tumours in dogs. Numerous prognostic factors are assessed through the histopathological examination of biopsy samples. PCR analysis of the c-Kit exon 11 mutational status is often performed to evaluate the prospect of success of a tyrosine kinase inhibitor therapy. This project aimed to train a deep learning algorithm (DLA) to identify the c-Kit-11 mutational status of MCTs solely based on histological morphology.

Materials and Methods

HE slides of 196 c-Kit-11 mutated and 189 non-mutated cutaneous and subcutaneous MCTs were scanned with an Aperio scanner and used as training database. The sample was then scanned with a 3DHitech Panoramic scanner to assess the DLA performance with a domain shift.

Results

The DLA correctly classified the HE slides after their c-Kit 11 mutational status in 83% of the cases. Chi² tests excluded an association between the DLA classification and the tumour grades (Patnaik and Kiupel) as well as the location of the MCTs in the skin. A strong association existed between c-Kit-11 mutated classification and ulcerated epidermis. The DLA reached a classification accuracy of 0.80 on the 3DHitech database.

Conclusions

DLA assisted morphological examination of MCTs can rapidly predict the c-Kit-11 mutational status of MCTs with a good precision, potentially saving the time and costs of a PCR analysis. Increasing the number of images as well as including scans originating from different scanners in the training dataset might improve the classification accuracy and robustness of this DLA.

Oral Abstracts Veterinary Pathology

SESSION 4: FISH PATHOLOGY
THURSDAY 31 AUGUST | 16.00-16.15

AN OUTBREAK OF CRYPTOCARYON IRRITANS DURING QUARANTINE-NEW VARIATIONS OF AN OLD THEME

D. Denk*, **S. Boylan*†**, **F.T. Just‡** and **E. Clarke***

**Zoological, SeaWorld Abu Dhabi, Abu Dhabi, AE, †Veterinary, Georgia Sea Turtle Center, Jekyll Island, US and ‡Pathology, Parasitology and Bee Diseases, Bavarian Health and Food Safety Authority, Oberschleissheim, DE*

Introduction

Cryptocaryon irritans (CI) is an obligate parasite of marine fish. Its widespread distribution, indiscriminate host specificity, short life cycle, and high virulence facilitate significant mortality rates (MRs). Quarantine of >8000 tropical fish presented an opportunity to diagnose, treat and review Cryptocaryonosis and highlight differing species susceptibilities, presentations, and treatment responses.

Materials and Methods

Clinical (gill endoscopy, GE) and postmortem examinations (PMEs) were performed between 19/09/2022 and 17/11/2022. GE highlighted numbers, location, size, tissue response and treatment success. PME included skin scrapes, gill presses, visceral squash preparations, faecal examination as well as histology and PCR testing on a subset of cases. Clinical findings, species affected, infection and mortality rates, lesion distribution and treatment response were reviewed using pivot tables.

Results

PME identified 457 affected animals, derived from 16 species of seven families/three orders. Butterflyfish dominated Perciformes fatalities (n=223) with MRs ranging from 4-100%. *Acanthurus mata* and *A. sohal* represented Acanthuriformes with 55-100% MRs. Labriformes comprised three species with MRs between 1.2-100%. Lesion distribution and severity amongst species varied significantly with CI affecting skin, gills, or a combination thereof. Secondary sepsis was observed in Acanthuriformes with severe skin changes. Species specific treatment protocols were established, accounting for observed drug sensitivities of fish and CI. Backwashes from affected systems resulted in infection spread.

Conclusions

GE reliably identifies CI and guides treatment. Though CI is commonly encountered during aquarium fish quarantine, investigations of outbreaks can provide valuable information on differing species susceptibility, biological behaviour of the parasite and treatment success.

Oral Abstracts Veterinary Pathology

SESSION 4: FISH PATHOLOGY
THURSDAY 31 AUGUST | 16.15-16.30

SYSTEMIC GRANULOMATOSIS IN MEAGRE (*ARGYROSOMUS REGIUS*): A LINK WITH ATYPICAL MYCOBACTERIA

M. Polinas*, **C. Murgia***, **T. Cubeddu***, **M.A. Sanna***, **S. Dei Giudici†**, **D. Schleicherová‡**, **A. Zanoli‡**, **G.P. Burrari***, **G. Barbera§**, **M. Prearo‡** and **E. Antuofermo***

**Department of Veterinary Medicine, University of Sassari and †Department of Animal Health, Istituto Zooprofilattico Sperimentale della Sardegna, Sassari, IT, ‡Istituto Zooprofilattico Sperimentale del Piemonte, Liguria e Valle d'Aosta, Torino, IT and §Gruppo Riservazzurra S.r.l., Oristano, IT*

Introduction

Systemic granulomatosis (SG) in farmed meagre (*Argyrosomus regius*) is a challenging disease characterized by the development of multiple granulomas in organs. Although infectious (*Mycobacterium* spp., *Nocardia* spp.) and non-infectious (nutritional) origins have been proposed, the aetiology of SG remains unknown. This study investigated the presence of bacteria associated with systemic granulomatosis in cultured meagre by a multidisciplinary approach.

Materials and Methods

Fifty-four (24 juveniles and 30 adults) farmed meagres were submitted for diagnostic purposes. After necropsies, tissue samples were processed for histology (H&E, Ziehl-Neelsen staining), microbiology in non-selective and selective culture media, PCR targeting the heat shock protein gene (*hsp65*), and Sanger sequencing. Healthy meagres were included as negative controls.

Results

Granulomas were multifocally detected in the organs of 30/30 adults and 4/24 juveniles. The Ziehl-Neelsen stain failed to detect mycobacteria. Colonies of *Mycobacterium* spp. grew from samples of 20/30 adult and 4/24 juvenile meagres. The results of *hsp65* PCR and the sequences showed 100% identity with *Mycobacterium chelonae* in adult (18/20) and juvenile (4/24) samples, whereas 2/20 adults showed high similarity with *Mycobacterium immunogenum*.

Conclusions

The gross pathology and histopathology, microbiology, PCR, and sequencing of the *hsp65* gene results indicated that *M. chelonae* is associated with systemic granulomatosis of farmed meagre. Demonstration of mycobacteria within granulomas by in situ hybridization with specific probes or antibodies is needed to assess their role as causative agents of systemic granulomatosis in farmed meagre.

Oral Abstracts Veterinary Pathology

SESSION 4: FISH PATHOLOGY

THURSDAY 31 AUGUST | 16.30-16.45

RECURRENT FISH KILLS IN A SMALL WARM RESERVOIR: LIFE ON THE VERGE OF DEATH

P. Ramos*, **C. Churro***, **A. Gonçalves*** and **F. Godinho†**

*1. Instituto Português do Mar e da Atmosfera, IPMA. Av. Doutor Alfredo Magalhães Ramalho, 6., 1495-165 Algés, PT and †2. Conselho Nacional da Água. Rua de O Século, n.º 51, 4.º Dto., Lisboa, PT

Introduction

Fish kills in surface water bodies are becoming more frequent in Portugal and are expected to increase due to climate change. The Patudos reservoir in the Alpiarça municipality regularly hosts angling competitions but has recurrently recorded fish mortality events, the last of which occurred in 2014 and 2022. This study identified the causes underlying fish mortality events to revert them in the future.

Materials and Methods

Available information regarding chemical and biological parameters indicative of trophic functioning of the aquatic system, as well as the results of post-mortem analyses carried out on fish specimens collected during the recent mortality events were scrutinized.

Results

Pathological examinations carried out on several goldfish (*Carassius auratus*) collected during the mortality events revealed hypersecretion of mucus in the skin and gills and gill hyperplasia and congestion, as well as the presence of cyanobacteria. The chemical and biological data analysed highlighted a eutrophic water body, with cyanobacteria accounting for more than 97% of the sampled phytoplankton. Specific phytoplanktonic samplings performed following the 2022 mortality event revealed the abundant presence of cyanobacteria, including several potentially toxic taxa.

Conclusions

The high trophy of the Patudos reservoir likely promoted the fish kills, either through phytoplankton toxicity during the occurrence of cyanobacterial blooms or through the rapid and drastic reduction of dissolved oxygen levels, frequent in eutrophic reservoirs. Separately or together, these stress factors resulted in the recorded mortalities, especially since the studied reservoir has a set of hydromorphological and biological characteristics that likely stimulate such mass mortality events.

Acknowledgements: This work was supported by SANAQUA project MAR-02.05.01-FEAMP-0004.

Thanks also are due to FCT/MCTES for the financial support to CIIMAR (UIDB/04423/2020 and UIDP/04423/2020).

Oral Abstracts Veterinary Pathology

SESSION 5: NEW METHODS, NEW TECHNOLOGY, TEACHING
THURSDAY 31 AUGUST | 16.00-16.15

PROCESSING METHODOLOGY FOR HISTOPATHOLOGICAL ASSESSMENT OF BLACK SOLDIER FLY (HERMETIA ILLUCENS) LARVAE GUT

A. Alvarado- Muñoz^{*†}, **J. Catarino**^{‡§}, **I. Lopes**[¶], **D. Murta**^{¶*} and **P. Faísca**^{‡*}

^{*}Veterinary Medicine, University of Évora and [†]Centre for Research and Technology of Agro-Environmental and Biological Sciences, CITAB-UTAD, Vila Real, PT, [‡]Faculty of Veterinary Medicine and [§]Comprehensive Health Research Centre (CHRC), Évora University, Évora, PT, [¶]Ingredient Odyssey SA, Entogreen, Santarém, PT, ^{*}Egas Moniz Center for Interdisciplinary Research (CiiEM), Egas Moniz School of Health & Science, Almada, PT and ^{*}CBIOS - Research Center for Biosciences & Health Technologies, Lusófona University, Lisbon, PT

Introduction

Insects have acquired zootechnic interest when they started to be used as an alternative protein source. Pathological evaluation of these specimens will become more common, but histopathological processing poses several challenges, mainly due to the chitinous content of the external cuticle and their small size. The objective of this work was to establish a dissection and processing method for histopathological evaluation of the black soldier fly larvae (BSFL) gut.

Materials and Methods

BSFL were sacrificed by submersion in a 70° water bath and 3 methods were tested: whole mount; Swiss-roll; and intestinal 3-part dissection. The latter technique included dissecting the cuticle to expose the gut, which was then sampled and stretched under a magnifying glass. The intestinal tract was divided into three anatomic recognizable portions and each was positioned longitudinally in histology cassettes between 2 sponges. After fixation with 10% buffered formaldehyde for 2 days, samples were routinely paraffin embedded, 3 µm sections were stained with haematoxylin-eosin.

Results

The Whole mount yielded poor results as the external cuticle made microtome sectioning very difficult. With the Swiss-roll technique, the full length of the intestine was never achieved in the same slide as the gut was very thin. The 3-part dissection allowed proper full-length evaluation of the different gut compartments, with the sponges allowing easier handling before paraffin embedding. The fixation and processing allowed optimal preservation of cellular structures.

Conclusions

This standardized protocol provides a solid basis for future studies that involve the histopathological analysis of BSFL gut.

Acknowledgements: This project was funded by the grant: NETA: New Strategies for Waste Water Treatment, POCI-01-0247-FEDER-046959 (Portugal2020)

Oral Abstracts Veterinary Pathology

SESSION 5: NEW METHODS, NEW TECHNOLOGY, TEACHING
THURSDAY 31 AUGUST | 16.15-16.30

CANINE MAMMARY TUMORS DATASET (CMTD): AN OPEN HISTOPATHOLOGY RESOURCE FOR COMPUTER-AIDED PATHOLOGY

G.P. Burrari*, **M. Polinas***, **A. Gabrieli***, **C. Murgia***, **M.P. Becchere†**, **P. Demontis‡** and **E. Antuofermo***

**Department of Veterinary Medicine and †Independent Researcher and ‡Department of Chemical, Physical, Mathematical and Natural Sciences, University of Sassari, Sassari, IT*

Introduction

Digital pathology (DP) and Computer-aided diagnosis (CAD) are gradually becoming the standard approach for the histological classification of human breast cancer. Although canine mammary tumours (CMTs) represent a major concern in veterinary medicine, the scarcity of available digital histopathological datasets has greatly hindered the employment of CAD in the diagnosis of CMTs. This work aimed to provide an open-access dataset of histopathological images of CMTs, namely CMTD, comprising the CMTs most frequently encountered in veterinary practice, and to test its suitability for DP use by three CAD systems.

Materials and Methods

Images from 44 CMTs were selected from a pool of frames obtained from video recorded for each slide. The three CAD systems were obtained by the combination of a feature extractor and a classifier (VGG16/SVM, Inception v3/SVM, and EfficientNet/SVM).

Results

A total of 1056 hematoxylin and eosin high-resolution JPEG images were obtained from 20 benign and 24 malignant cases of CMTs, 16 of which were of the simple type and 28 of the complex type. The couple EfficientNet framework/SVM resulted in the best performances across all tested architectures with accuracy from 0.82 to 0.85.

Conclusions

To the best of our knowledge, CMTD represents the larger canine mammary tumour dataset for DP use. However, its implementation with a larger number of cases and histopathological images is advisable to improve the overall accuracy of CAD systems and its reliability in the binary classification of CMTs.

Oral Abstracts Veterinary Pathology

SESSION 5: NEW METHODS, NEW TECHNOLOGY, TEACHING
THURSDAY 31 AUGUST | 16.30-16.45

COMPARATIVE SPATIAL PROTEOMICS BETWEEN SARS-COV-2 INFECTED LUNGS OF ROBOROVSKI DWARF HAMSTERS AND SYRIAN HAMSTERS

S. Kunder*, **A. Voß***, **B.F. Hempel†**, **J. Trimpert‡**, **K. Dieter†** and **A.D. Gruber§**

**School of Veterinary Medicine, Institute of Veterinary Pathology, †School of Veterinary Medicine, Veterinary Centre for Resistance Research (TZR), ‡School of Veterinary Medicine, Institute of Virology and §School of Veterinary Medicine, Institute of Veterinary Pathology, Freie Universität Berlin, Berlin, DE*

Introduction

Of various COVID-19 models, two hamster species are of particular interest. Specifically, the Roborovski dwarf hamster mimics a severe, rapidly lethal pneumonia as seen in highly susceptible patients, whereas the Syrian hamster presents with a moderate, self-limiting disease. Here, we aim to identify relevant mechanisms responsible for the striking differences from a spatial proteomics perspective.

Materials and Methods

Hamsters (n = 6) were sacrificed two days after intranasal infection with SARS-CoV-2. FFPE lung sections were processed for histology and matrix-assisted laser desorption/ionization mass spectrometry imaging (MALDI-MSI). Spatial proteomics data were analyzed with SCiLS™ Lab and Enrichr. Molecular signatures were considered discriminatory with area under curve (AUC) values of < 0.3 or > 0.7, respectively.

Results

In the Roborovski hamster, 15 proteins were of a higher and 6 of a lower relative abundance when compared to the Syrian hamster. The former included proteins involved in blood coagulation (annexin A2, fibrinogen alpha chain, myosin-9), cell morphology (plectin isoform X16), and wound healing (heat shock protein beta-1). Strikingly, the latter influence extracellular matrix morphology (fibronectin isoform X1), leucocyte tethering (vimentin), and respiratory burst (40S ribosomal protein S19). Additionally, some proteins (e.g., higher albumin) directly correlated with histomorphology (i.e., more severe, protein-rich alveolar oedema).

Conclusions

Spatial proteomics enabled the detection of several discriminating proteins, some of which reflected histomorphological findings. However, the data call for future in-depth proteome studies to allow for a more detailed understanding of distinctive pathways or pathogenetic discrepancies that would explain the stark species differences in disease progression.

Acknowledgements: This study was partially funded by the German Research Foundation Grant SFB-TR84 Z01b to ADG and JT and Berlin Einstein Foundation (EC3R EZ-2020-597-2) to ADG

Oral Abstracts Veterinary Pathology

SESSION 5: NEW METHODS, NEW TECHNOLOGY, TEACHING
THURSDAY 31 AUGUST | 16.45-17.00

TRAINING ON HEALTHY TO LEARN PATHOLOGY: AN ALTERNATIVE APPROACH FOR A.I. SUPERVISED LEARNING IN NEOPLASTIC TISSUES

L. Ressel

Department of Veterinary Anatomy Physiology and Pathology, University of Liverpool, Neston, GB

Introduction

Convolutional Neural Networks (CNN) are used in image classification. They are trained using large numbers of examples of defined categories (supervised learning). The pathologist's brain, when categorising the phenotype of a neoplasm, uses a similar approach, but also compares mentally the features of the neoplastic cells with those of the supposed normal tissue of origin, deducing the phenotype by similarity. The present study aimed to explore the potential of training a CNN (PhenoNet) to recognise carcinomas and sarcomas based on examples from normal epithelial and mesenchymal tissues.

Materials and Methods

Histological slides of canine cutaneous carcinomas and sarcomas (n=10) were digitalised. For the training set, examples of epithelial and mesenchymal normal tissues surrounding the tumours were annotated (PhenoNet), or areas of carcinoma and sarcoma (TumourNet: control network). Both networks were based on DSNET10x and UNET20x architecture. The test set consisted of 10 randomly selected areas of different cutaneous carcinomas and sarcomas. A binary mask was created representative of the prediction of carcinoma or sarcoma classes. Percentage of pixel area correctly classified was recorded. A score >50% in one class determined the final diagnosis.

Results

Lower resolution DSNET10x performed better. PhenoNet diagnosed correctly 80% of carcinomas and 70% of sarcomas compared to TumourNet scoring only 50% in each category.

Conclusions

The network trained on normal tissues performed better than the traditionally trained one, suggesting a higher degree of generalisation. This preliminary study suggests a possible alternative approach to AI training for networks involved in diagnosing tumour phenotypes.

Acknowledgements: NVIDIA (GPU hardware); Silcock Veterinary Pathology Endowment (DiMo Lab support)

Oral Abstracts Veterinary Pathology

SESSION 5: NEW METHODS, NEW TECHNOLOGY, TEACHING
THURSDAY 31 AUGUST | 17.00-17.15

THE VIRTUAL POST MORTEM ROOM: IMMERSIVE GROSS PATHOLOGY EXPERIENCE IN THE METAVERSE

E. Ricci*, **A. Hulme_Beaman*** and **L. Ressel†**

**Department of Veterinary Anatomy Physiology and Pathology, University of Liverpool, Neston, GB and †Department of Veterinary Anatomy Physiology and Pathology, University of Liverpool, individual, GB*

Introduction

Rapid advancements in technology have revolutionised various aspects of our lives, and the field of education is no exception. One such emerging concept that holds tremendous potential for education is the metaverse, a virtual reality (VR) space where people can interact with each other and with digital objects in a three-dimensional environment. In medical education, the metaverse offers a transformative platform for learning and understanding complex subjects such as organ morbid conditions. Moreover, the metaverse provides a collaborative environment where experts from different global locations can come together, transcending physical boundaries. We developed a veterinary pathology post-mortem room VR environment to test the potentials of this technology.

Materials and Methods

Using an established photogrammetry workflow, we digitised the post mortem room of the VAPP Department. Models were created using structures from motion photogrammetry. 3D models of the room and gross specimens were imported and edited in the metaverse (Spatial.io). The virtual room was accessed by VR visors, transporting the viewer physically in the room with ability to interact with objects and with other users connected via different routes.

Results

Reconstruction of room and organs was successful and engaging with the models in the virtual room within the metaverse was judged successful and life-like by expert pathologists, residents and students.

Conclusions

The metaverse presents a promising platform for veterinary pathology education and collaboration. By offering engaging, immersive and accessible learning experiences, these technologies have the potential to revolutionize the way veterinary professionals are trained.

Acknowledgements: NVIDIA (GPU hardware); Epic Games (Photogrammetry software) Silcock Veterinary Pathology Endowment (DiMo Lab equipment)

Oral Abstracts Veterinary Pathology

SESSION 6: LIVESTOCK

FRIDAY 1 SEPTEMBER | 10.45-10.58

RE-EMERGENCE OF OVINE SHEEPPOX INFECTION IN SPAIN AFTER 54 YEARS

D. Lacasta*†, J.M. Bello‡, Á. Gómez*, E. Pérez*, L.M. Ferrer*†, R. Lechuga‡, A.A. Benito§, H. Esmaeili¶, N. Calvo-Sánchez*, A. Rodríguez-Largo*, J. Martínez‡ and L. Luján*

**Department of Animal Pathology, University of Zaragoza and †SCRUM, University of Zaragoza, Zaragoza, ES, ‡Nanta S.A.U., Tres Cantos, ES, §Exopol S.L., San Mateo de Gállego, ES, ¶University of Tehran, Tehran, IR and ‡Autonomous University of Barcelona, Barcelona, ES*

Introduction

Sheeppox virus (SPPV) infection causes an economically important and notifiable disease in sheep. SPPV infection has caused several re-emerging episodes in European countries. Spain has been free of sheeppox infection since 1968, however, on 19th September 2022 an outbreak was declared in the Granada province. Our objective was to describe the main pathologic and epidemiological features of the re-emergence of SPPV infection in Spain.

Materials and Methods

Skin and lung samples from the first suspected flock were submitted for histopathologic and PCR analysis. Transmission electron microscopy (TEM) examination was also undertaken.

Results

Affected animals showed fever, nasal and ocular discharge and dyspnoea. Hairless areas of skin exhibited multifocal erythematous macules that evolved into papules and vesicles, progressing to erosion of the epithelium and ulceration. Gross lesions also included multifocal superficial, 1-3 cm, whitish firm lung nodules. In the skin, there was severe histiocytic and neutrophilic dermatitis. Key histopathologic finding was the presence of numerous eosinophilic intracytoplasmic inclusion bodies in dermal macrophages and fibroblasts. In lungs, microscopic lesions consisted of mononuclear interstitial pneumonia, peribronchiolitis and type II pneumocyte hyperplasia. TEM revealed the presence of brick-shape virions in the cytoplasm of dermal epithelial cells and fibroblasts. PCR confirmed the presence of SPPV genome. A total of 30 outbreaks have been declared until 24th May 2023 in flocks related to this first case.

Conclusions

These are the first sheeppox cases observed in Spain since 1968. Eradication measures were immediately established and it is hoped that Spain will soon regain SPPV free status.

Oral Abstracts Veterinary Pathology

SESSION 6: LIVESTOCK

FRIDAY 1 SEPTEMBER | 10.58-11.11

A SEVERE OUTBREAK OF COLIBACILLOSIS IN BROILERS

S. Kromann*, **S. Baig†**, **R. Heidemann Olsen***, **S. Marie Edslev†**, **I. Thøfner***, **A. Miki Bojesen***, **H. Elvang Jensen*** and **M. Stegger†**

*Department of Veterinary and Animal Sciences, Faculty of Health and Medical Sciences, University of Copenhagen, DK and †Statens Serum Institut, Department of Bacteria, Parasites and Fungi, DK

Introduction

In poultry, infections caused by *Escherichia coli* constitute a significant disease challenge even during times considered low in colibacillosis prevalence, causing mortality, condemnations, antibiotic usage, and animal welfare concerns. Furthermore, colibacillosis can, at times, manifest as regular disease outbreaks enhancing the consequences considerably and creating almost unmanageable situations for the affected farms as well as vast economic losses for the industry. In 2019-2020, the Danish broiler population was rattled by such an outbreak situation. Here we describe the disease manifestations and determine the cause.

Materials and Methods

A total number of 1039 birds from outbreak-affected and healthy flocks were subjected to necropsy with subsequent comparison of lesions, flock performance, and pathogen characterisation.

Results

Outbreak-related flocks exhibited condemnations of $5.04\% \pm 3.67$ compared to $1.02\% \pm 0.4$ in unaffected flocks, with condemnations mainly being attributed to skin lesions. Particularly, fibrinopurulent cellulitis (46.8%), respiratory changes (84.39%), polyserositis (30.06%), arthritis (49.13%), and femoral head necrosis with physeal/metaphyseal and/or diaphyseal involvement (49.13%) were major findings during necropsy of birds from outbreak-related flocks. In broilers from non-outbreak-related flocks, these manifestations were present in 4.46%, 43.31%, 3.82%, 6.37%, and 8.28%, respectively.

Conclusions

A marked increase in colibacillosis was caused by specific *E. coli* clones, resulting in a vast elevation in slaughter condemnations. Especially cellulitis and lesions due to septicaemia were the leading causes of condemnation.

Oral Abstracts Veterinary Pathology

SESSION 6: LIVESTOCK

FRIDAY 1 SEPTEMBER | 11.11-11.24

UNRAVELLING THE PROTEIN SIGNATURE OF BOVINE AND PORCINE GRANULOMAS IN ANIMALS WITH A MYCOBACTERIUM TUBERCULOSIS COMPLEX FIELD INFECTION BY MALDI-MSI

F. Larenas-Muñoz*, J.M. Sánchez-Carvajal*, I. Ruedas-Torres*, C. Álvarez-Delgado*, K. Fristikova*, F.J. Pallarés*, L. Carrasco*, E. Chicano-Gálvez†, I.M. Rodríguez-Gómez* and J. Gómez Laguna*

*Anatomy and Comparative Pathology and Toxicology, University of Córdoba and †IMIBIC/UCO/HURS, Córdoba, ES

Introduction

Matrix-assisted laser desorption/ionization-mass spectrometry imaging (MALDI-MSI) enables the simultaneous identification of molecules based on their molecular weight along with their spatial distribution. The methodology is of special interest for studies on diseases with a complex host-pathogen interaction, such as animal tuberculosis. This study compares the protein signature in granulomas of cattle and pigs naturally infected with Mycobacterium tuberculosis complex (MTC), identifying biological and immunological signaling pathways activated throughout the disease.

Materials and Methods

Lymph nodes from each 4 pigs and cattle positive for MTC by bacteriological culture and/or real-time PCR were used. From the masses identified by MALDI-MSI, a protein-protein interaction network was constructed using the STRING protein database, and the biological and immunological signaling pathways in which these proteins could participate were delineated through the ClueGO and CluePedia plugins (Cytoscape software).

Results

There was a clear separation between bovine and porcine granulomas, evidencing differences in the proteomes. However, common proteins were also identified, which were related to complement activation, antigen processing and presentation, and cellular response to IL-4 and IL-17. On the other hand, in the bovine proteome, the terms NK cell degranulation and regulation of endosome transport stood out, while platelet activation and neutrophil-mediated elimination of bacteria were evidenced in pigs.

Conclusions

This study provides new insights into the immunopathogenesis of tuberculosis in cattle and pigs, opening up new areas of research and highlighting the importance, among others, of the complement activation pathway and the regulation of NK cell and neutrophil mediated immunity in this disease.

Acknowledgements: Funding: "New measures and techniques to control Bovine Tuberculosis in Andalusia" (EIP-AGRI) (GOP2I-CO-16-0010).

Fernanda Larenas-Muñoz: ANID (National Research and Development Agency) (Chile/2019/72200324)

Oral Abstracts Veterinary Pathology

SESSION 6: LIVESTOCK

FRIDAY 1 SEPTEMBER | 11.24-11.37

DISCOVERY OF THE AVIAN RECEPTOR IN THE PORCINE NASAL MUCOSA REVEALS NEW INSIGHT INTO INFLUENZA A VIRUS HOST TROPSIM

C. Kristensen*, **L.E. Larsen***, **R. Trebbien†** and **H.E. Jensen***

**Department of Veterinary and Animal Sciences, University of Copenhagen, Frederiksberg C, DK and †Department for Virus and Microbiological Special Diagnostics, Statens Serum Institut, Copenhagen S, DK*

Introduction

Influenza A virus (IAV) has a receptor preference for sialic acids (SA) linked to galactose in an $\alpha 2,3$ or $\alpha 2,6$ manner. IAVs isolated from avian origin have a preference for the SA- $\alpha 2,3$ -galactose linkage while IAVs isolated from pigs and humans prefer the SA- $\alpha 2,6$ -galactose linkage. There are two major forms of SAs: N-Acetylneuraminic acid (Neu5Ac) and N-Glycolylneuraminic acid (Neu5Gc). Neu5Gc is described in the porcine respiratory tract, however, the tissue distribution of Neu5Gc- $\alpha 2,6$ -galactose is so far unknown.

Materials and Methods

The distribution of SA- $\alpha 2,3$ -galactose and SA- $\alpha 2,6$ -galactose was evaluated in porcine nasal, tracheal, and lung tissues by lectin histochemistry. The Sambucus Nigra Lectin (SNA) was used to detect the SA- $\alpha 2,6$ -galactose linkage. Maackia Amurensis Lectin (MAA-1) and Maackia Amurensis Lectin II (MAA-II) detected the SA- $\alpha 2,3$ -galactose linkage. The SNA lectin binds to both Neu5Gc and Neu5Ac and to detect the Neu5Ac- $\alpha 2,6$ -galactose distribution, the tissues were pretreated with an anti-Neu5Gc-antibody before adding the SNA.

Results

SA- $\alpha 2,6$ -galactose was present throughout the porcine respiratory tract, while SA- $\alpha 2,3$ -galactose was only present in nasal mucosa, bronchioles, and alveoli. Neu5Gc- $\alpha 2,6$ -galactose was dominating in the tracheal glands, while Neu5Ac- $\alpha 2,6$ -galactose dominated the surface of the ciliated epithelium.

Conclusions

The results show that SA- $\alpha 2,3$ -galactose (the avian-IAV receptor) is also present in the porcine nasal mucosa, which strengthens the hypothesis that pigs act as an IAV mixing vessel. Furthermore, these results suggest that Neu5Gc- $\alpha 2,6$ -galactose is not the primary IAV receptor in pigs due to the lack of staining on the surface of the ciliated epithelium which is the primary IAV target.

Acknowledgements: This work was supported by the Novo Nordic foundation (FluZooMark: NNF19OC0056326).

Oral Abstracts Veterinary Pathology

SESSION 6: LIVESTOCK

FRIDAY 1 SEPTEMBER | 11.37-11.50

PORCINE CIRCOVIRUS 3 (PCV-3) EXPERIMENTAL INOCULATION IN PREGNANT GILTS

A. Cobos*, **M. Sibila†**, **E. Huerta†**, **A. Llorens†**, **A. Ruiz‡**, **M. Pérez†**, **A. Barceló†**, **R. Lohse§**, **M. Balasch¶** and **J. Segalés***

**Pathology, Unitat Mixta d'Investigació IRTA-UAB en Sanitat Animal, Centre de Recerca i Sanitat Animal (CRESA, IRTA-UAB) and †Unitat Mixta d'Investigació IRTA-UAB en Sanitat Animal, Centre de Recerca i Sanitat Animal (CRESA, IRTA-UAB), Bellaterra, ES, ‡IRTA-ZOETIS, ES, §Zoetis Inc., Kalamazoo, US and ¶Zoetis Manufacturing & Research, Vall de Bianya, ES and *Sanitat i Anatomia Animals, Universitat Autònoma de Barcelona, Bellaterra, ES*

Introduction

PCV-3 is associated with reproductive and postnatal disease. However, reproductive disease has not been experimentally studied so far. In the present study, we inoculated pregnant gilts at two different gestational stages and reproduced PCV-3 associated lesions mimicking naturally occurring disease.

Materials and Methods

PCV-2 and PCV-3 negative gilts were inoculated with a PCV-3 isolate either at ~45 (T1, n=6) or ~80 (T2, n=5) days of gestation or mock inoculated (T3, n=2). Gilts were bled weekly throughout the study. Piglets were euthanized and sampled either at farrowing or weaning. Serum and pools of fresh tissue were processed for PCV-3 qPCR and histological assessment and in situ hybridization (ISH) for PCV-3 was performed on formalin fixed tissue sections.

Results

Inoculated gilts were viraemic from the second week post-inoculation onwards. Overall, T1 piglets had higher viral loads. Systemic periarteritis/arteritis, myocarditis, encephalitis, and pneumonia were found mainly in T1 (weaning>farrowing) and to a lesser extent in T2 piglets at weaning. Positive ISH signals were associated with lesions and found in unaltered lymphoid tissues.

Conclusions

PCV-3 experimental inoculation of pregnant gilts caused transplacental infection of piglets, resulting in high viral loads and characteristic histological lesions, which eventually worsen at weaning age. Severity was higher when infection occurred earlier in gestation, suggesting that fetuses are more susceptible at earlier timepoints. The observed lesions in piglets at weaning suggest that postnatal disease can be caused by intrauterine infections (associated with sustained viraemia in piglets) and blurs the line between reproductive and postnatal disease.

Acknowledgements: This research was funded by Zoetis by means of an industrial doctorate from Catalan Government (DI2019-083).

Oral Abstracts Veterinary Pathology

SESSION 6: LIVESTOCK

FRIDAY 1 SEPTEMBER | 11.50-12.03

EFFICIENCY OF DIFFERENT ORF VIRUS INFECTION ROUTES FOR THE EXPERIMENTAL REPRODUCTION OF CONTAGIOUS ECTHYMA IN LAMBS

Á. Gómez*, M. Cuadra*, M. Ríos*, T. Tejedor†, A. Rodríguez Largo*, E. Pérez*, N. Calvo-Sánchez*, S. Villanueva-Saz*, P. Quílez*, P. Windsor‡, R. Reina§, A. Benito¶, A. Orfín*, L. Luján* and D. Lacasta*

*Department of Animal Pathology and †Department of Anatomy, Embryology and Animal Genetics, University of Zaragoza, ‡Livestock Health and Production, University of Sydney, Sydney, AU, §Institute of Agrobiotechnology, CSIC-Government of Navarra, Navarra, ES and ¶Molecular biology, Exopol, Zaragoza, ES

Introduction

Orf virus (ORFV) is the causative agent of Contagious Ecthyma (CE), responsible of severe economic losses worldwide. CE mainly affects lambs and kids, causing proliferative lesions on mouth, lips, oral mucosa, udder and hooves, evolving into vesicles, pustules, and scabs. New vaccines are needed to control CE, and to properly assess vaccine global performance, experimental reproduction of CE is required. Since the most efficient ORFV experimental infection route is not yet known, this study evaluated the clinicopathological features of CE after experimental ORFV infection via three different infection routes.

Materials and Methods

Three groups of 9 lambs were inoculated in the lips with wildtype ORFV. Group 1: intradermally; group 2: subcutaneously; group 3: by scarification. A daily clinical examination was performed for 20 days. Serum samples were collected to determine anti-ORFV antibody by ELISA. Swabs from skin lesions were collected to determine viral loads by qPCR. Post-mortem examination determined distribution and number of lesions and histology served to determine lesion severity.

Results

The severity of lesions was similar in groups 1 and 3. In group 1, lesions were widely distributed, whereas in group 3, they only occurred on the muzzle. In group 2, almost no lesions were observed. Viral loads were significantly higher in group 1 compared to group 2. A higher number of lesions was correlated with a higher viral load. All groups were seronegative throughout the entire experiment.

Conclusions

Intradermal inoculation of ORFV is the most efficient experimental infection route for reproduction of standard CE lesions.

Acknowledgements: Funded by ECTICONA (PC0080-0081). Government of Navarra.

Oral Abstracts Veterinary Pathology

SESSION 6: LIVESTOCK

FRIDAY 1 SEPTEMBER | 12.03-12.16

IS MECHANICAL MUCOSAL INJURY THE HIDDEN CULPRIT OF HAEMORRHAGIC BOWEL SYNDROME IN CATTLE?

B. De Jonge and K. Chiers

Department of Pathobiology, Pharmacology and Zoological Medicine, Ghent University Faculty of Veterinary Medicine, Merelbeke, BE

Introduction

Haemorrhagic bowel syndrome (HBS) is a highly fatal intestinal disease, almost exclusively affecting mature dairy cattle. It is characterized by a small intestinal intramucosal haematoma, dissecting the muscularis mucosae. This haematoma originates from small mucosal erosions with dissection of the muscularis mucosae. The pathogenesis is unknown. Based on the gross appearance of these early-stage lesions and lack of other histological changes, a traumatic aetiology might be considered. The objective of this study was to assess if lesions similar to HBS early-stage lesions can be produced by mechanical trauma (abrasion) to the small intestinal mucosa. It also evaluated if mucosal fragility may be an underlying predisposing factor.

Materials and Methods

An ex-vivo intestinal model creating mucosal abrasion was developed. Opened small intestinal samples (20x10 cm) collected from two cows with HBS and seven controls (4 dairy cows, 3 beef bulls), were exposed to 3 different bi-axial tensions (4N, 6N, 8N) with identical probe pressure (probe weight = 66g). Intestinal lesions were histologically examined and scored.

Results

In all animals, mucosal erosions with dissection of the muscularis mucosae similar to HBS early-stage lesions could be created. Dissection of the muscularis mucosae was more prevalent in lesions created in HBS cows and control dairy cows compared to beef bulls.

Conclusions

The study indicates that HBS early-stage lesions might develop from mechanical injury to the mucosa, and that the intestinal mucosa of dairy cows has a higher tendency to develop splitting of the muscularis mucosae compared to beef cattle.

Oral Abstracts Veterinary Pathology

SESSION 7: TUMOUR PATHOLOGY
FRIDAY 1 SEPTEMBER | 10.45-10.58

FREE-CIRCULATING AND EXTRACELLULAR VESICLE-ASSOCIATED MICRORNAS IN HEALTHY AND T CELL LYMPHOMA BEARING DOGS

V. Moccia*, **A. Molinari***, **S. Ferraresso***, **F. Torrigiani***, **C. Leo†**, **C. Capuano†** and **V. Zappulli***

**Comparative Biomedicine and Food Science, University of Padua, Padua, IT and †Oncology Service, Anicura Istituto Veterinario Novara, Novara, IT*

Introduction

microRNAs (miRNAs) are highly conserved small non-coding RNAs. In blood, they can circulate freely or associated with extracellular vesicles (EVs). miRNAs and EVs have been investigated as tumour biomarkers in human lymphomas; preliminary studies have recently been performed in veterinary oncology. The aim of this study was to identify expression patterns of specific circulating cell-free and EV-related miRNAs in dogs with T cell lymphoma.

Materials and Methods

Eight healthy dogs and eight dogs with newly diagnosed T cell lymphoma, free of concurrent diseases and naïve to corticosteroid therapy, were enrolled. Plasma samples were collected and ultracentrifuged to obtain EVs. Both pelleted EVs and supernatant were employed for miRNA extraction, obtaining EV-associated miRNAs and free-miRNAs. Quantitative Real-Time PCR (qPCR) assays were performed to quantify the expression of 84 target miRNAs. Cycle threshold (CT) values were analyzed via the data analysis web portal at <http://www.qiagen.com/geneglobe> using the $\Delta\Delta CT$ method, and normalization was based on the NormFinder method. The fold change was calculated using the $2^{-\Delta\Delta CT}$ formula, p values were calculated with the Student's t-test, considering $p < 0.05$ as significant.

Results

Nine EV-associated miRNAs and seven free miRNAs were significantly differentially expressed between healthy and lymphoma-bearing dogs. hsa-miR-222-3p, found to be overexpressed in some human tumours, was differentially expressed both in EV-associated and free-miRNAs of lymphoma bearing dogs compared to healthy dogs.

Conclusions

The results of this study could serve as the basis for further investigations on circulating miRNAs in liquid biopsies for early diagnosis of canine T cell lymphoma.

Oral Abstracts Veterinary Pathology

SESSION 7: TUMOUR PATHOLOGY
FRIDAY 1 SEPTEMBER | 10.58-11.11

STEREOLOGICAL ESTIMATION OF MEAN NUCLEAR VOLUME AS PROGNOSTIC FACTOR IN CANINE SUBCUTANEOUS MAST CELL TUMORS

J. Catarino^{*†}, A. Macara^{*}, F. Coelho^{*}, A. Barros[‡] and P. Faísca^{*‡}

^{}Faculdade de Medicina Veterinária, Universidade Lusófona- Centro Universitário de Lisboa, Lisboa, PT, [†]Comprehensive Health Research Centre (CHRC), Universidade de Évora, Évora, PT and [‡]Instituto Gulbenkian de Ciência, Oeiras, PT*

Introduction

Grading schemes for canine subcutaneous mast cell tumours (scMCT) are not clearly defined. Thompson et al. (2011) indicated infiltrative pattern, mitotic count, and presence of multinucleated cells as linked to decreased survival time. However, the applied qualitative and semiquantitative parameters are prone to interobserver variability and bias. This study investigated the prognostic value of volume-weighted mean nuclear volume (MNV), a stereological estimation that provides information about the nuclear size and its variability.

Materials and Methods

Thirty csMCTs were selected, based on the condition that these dogs were treated with surgery alone and 2 years of follow-up data, as well as age, sex, breed, and surgical margins, were available. MNV was estimated using the point-intercept method with the newCAST stereological software (Visiopharm). Postsurgical resolution of disease was given an outcome value of 0 (OCO), an outcome value of 1 (OC1) included cases that died or were euthanized as a result of local recurrence or development of metastases.

Results

MNV values were statistically different between OCO and OC1 groups in both univariable (Linear regression) and multivariable (Wilcoxon) analysis with higher values in dogs with poorer outcomes ($P < 0.001$). Multivariable logistic regression showed that MNV had good potential to predict negative outcomes, almost statistically significant ($p = 0.051$). An optimal cut-off value of $MNV > 143 \mu\text{m}^3$ was able to identify csMCT with poor prognosis (OC1 cases) with 80% specificity and 90% sensitivity ($p = 0.020$, McFadden's $R^2 = 0.57$).

Conclusions

This study suggests that the estimation of MNV can objectively detect csMCTs with poorer outcomes.

Oral Abstracts Veterinary Pathology

SESSION 7: TUMOUR PATHOLOGY
FRIDAY 1 SEPTEMBER | 11.11-11.24

COMPARISON OF CYTOLOGICAL AND HISTOLOGICAL CLASSIFICATION SYSTEMS FOR THE DETECTION OF NODAL METASTASES OF CANINE MAST CELL TUMOURS

A. Renzi, M.G. Ferrari, R. Zaccone, L. Marconato, C. Agnoli, S. Zanardi and S. Sabattini

Department of Veterinary Medical Sciences, University of Bologna, Ozzano dell'Emilia, Bologna, IT

Introduction

Weishaar's histological node (HN) classification represents the gold standard for the evaluation of lymph node (LN) metastases in canine mast cell tumors (MCT). Since its proposal in 2009, Krick's classification for the cytological assessment of nodal MCT metastasis has never been validated histologically. The present study assessed the diagnostic accuracy of Krick's classification using Weishaar's system as gold standard.

Materials and Methods

Surgically-removed regional/sentinel LNs of MCT-bearing dogs were prospectively collected (n=150). Krick's classification was applied independently by two operators on ex-vivo cytological aspirates. The interobserver agreement was recorded and discordant cases were reassessed to reach a consensus. The final assessments were compared with Weishaar's HN status. Additionally, in-vivo nodal aspirates of MCT-bearing dogs undergoing subsequent lymphadenectomy were retrospectively examined and the cytological and histological findings compared.

Results

Interobserver agreement was 80.7%. HN2/HN3 metastases were detected in 84% of LNs with possible/probable/certain metastases and in 25% of cytologically normal/reactive LNs. In-vivo aspirates were diagnostic in 44/64 (68.8%) cases. 50% of non-diagnostic, 41.4% of normal/reactive LNs and 100% of possible/probable/certain metastasis were HN2/HN3. All cytologically certain metastases were histologically classified as HN3 or HN2, in both ex-vivo and in-vivo cases.

Conclusions

The accuracy of Krick's classification was 78% for ex-vivo LNs and decreased to 63% for in-vivo aspirates, mainly due to a high non-diagnostic rate; thus, lymphadenectomy should not be limited to cytologically positive or suspected positive LNs. The cytological evidence of certain metastasis appears solid and can safely drive the decision of removing the affected LN.

Oral Abstracts Veterinary Pathology

SESSION 7: TUMOUR PATHOLOGY
FRIDAY 1 SEPTEMBER | 11.24-11.37

PROPOSAL FOR A NEW HISTOLOGICAL GRADING SYSTEM FOR CANINE ORAL MELANOCYTIC TUMORS

F. Chocteau[†], A. Prouteau[†], B. Hedan[†] and C. André[†]

[†]Team 7 - Stress, Adaptation and Tumor Escape, CRCI2NA - Cancer Research Center Nantes Angers, Nantes, FR and [†]Team Dog Genetics, IGDR - Institute of Genetics and Development of Rennes, Rennes, FR

Introduction

Melanocytic tumours are the most frequent neoplasias of the canine oral cavity (COMTs) with a poor prognosis but heterogeneous biological behaviour. While many studies established histological parameters for the prognosis of COMTs, a robust and easy-to-use grading system of COMTs has not yet been proposed.

Materials and Methods

This retrospective study comprised a cohort of 75 dogs with a COMT removed by surgery as the only treatment. Tumours were graded according to pigmentation (absence of pigment: 1 point), necrosis (>25% necrosis excluding skin ulceration: 1 point) and mitotic count (>6 mitoses per 0.00159 mm²: 1 point), with grades representing the sum of the 3 parameters: Grade 1 (0 or 1 point), Grade 2 (2 points) and Grade 3 (3 points). These histological data, as well as the epidemioclinical characteristics (location, stage...) were described and studied in relation to specific survival using univariate (Log-rank test) and multivariate (Cox regression) analyses.

Results

For specific survival, median survival times and hazard ratios (HR) by Log-rank analysis ($p=0.006$) were: Grade 1 (309 days; HR=1.00), Grade 2 (186 days; HR=1.87), and Grade 3 (85 days; HR=3.06). Multivariate analysis confirmed the poor outcome for dogs with higher grades (Grade 2: HR=2.02; $p=0.014$; Grade 3: 3.01; $p=0.021$ compared to Grade 1) independently of staging system (Stage III: HR=2.31; $p=0.016$ compared with Stage I) and tumour location (Mucosa: HR=0.51; $p=0.017$ compared with other locations).

Conclusions

The proposed histological grading system for COMTs is a very strong prognostic indicator and would allow better classification of these tumours.

Oral Abstracts Veterinary Pathology

SESSION 7: TUMOUR PATHOLOGY
FRIDAY 1 SEPTEMBER | 11.37-11.50

RAC1 PATHWAY IN CANINE ORAL MELANOMA PROGRESSION AND PROGNOSIS

I. Porcellato*, A. Lo Giudice*, C. Capaccia*, C. Brachelente*, G. Guelfi*, M. Starkey†, M. Sforna* and S. Di Palma‡

*Department of Veterinary Medicine, University of Perugia, Perugia, IT, †Wellcome Sanger Institute, Cambridge, GB and ‡IDEXX laboratories Ltd., Wetherby, GB

Introduction

In human medicine, the overexpression of genes involved in the RAC1 pathway is postulated to play a role in anti-apoptotic, pro-proliferative, pro-angiogenic properties, and in tumour metastasis. Moreover, activation of the RAC1 pathway is associated with resistance to both targeted therapy and chemotherapy. The aim of this study was to assess the involvement of RAC1 pathway members in the progression and metastasis of canine oral melanocytic tumours.

Materials and Methods

Thirty cases (25 primary oral melanomas, including 5 with nodal/distant metastases, 5 oral melanocytomas) were selected. RT-qPCR was performed on 5 oral melanomas, 5 metastases, and 5 melanocytomas to investigate the expression of ELMO1, DOCK2, CDKN1B, CORO1A, VAV3, CCR7, and MMP2. Immunohistochemistry for ELMO1, p27 (CDKN1B), ITGA4, VAV3, and CORO1A expression was performed on all cases.

Results

ELMO1 and VAV3 displayed significantly higher expression in melanomas than in melanocytomas, at both mRNA and protein level ($p < 0.05$). Cytoplasmic expression of p27 was more commonly observed in melanomas than in melanocytomas ($p = 0.001$). The protein expression of ELMO1 and cytoplasmic p27 was higher in cases with metastases, when compared to the non-metastatic tumours ($p < 0.05$). ELMO1, cytoplasmic p27, and VAV3 were also directly correlated with well-known histological prognostic features, such as mitotic count and atypia, and inversely correlated with pigmentation.

Conclusions

The RAC1 pathway appears to be activated in the progression and metastasis of canine oral melanomas, especially involving ELMO1, p27, and VAV3. These molecules could be further investigated regarding their relevance as prognostic markers and potential therapeutic targets.

Oral Abstracts Veterinary Pathology

SESSION 7: TUMOUR PATHOLOGY
FRIDAY 1 SEPTEMBER | 11.50-12.03

CORRELATION BETWEEN MALIGNANT HISTOLOGICAL FEATURES OF CANINE DIGITAL SQUAMOUS CELL CARCINOMA AND GENETIC KIT LIGAND COPY NUMBER VARIATION

A. Cerezo Echevarría*, **A. Kehl***, **C. Beitzinger***, **T. Müller†**, **R. Klopffleisch‡** and **H. Aupperle-Lellbach***

**LABOKLIN GmbH & Co. KG, †Universität Würzburg and ‡Freie Universität Berlin, DE*

Introduction

The development of canine digital squamous cell carcinoma (CDSCC) is known to have a strong breed and haircoat color predisposition, like in large, dark dogs. Consequently, few studies have suggested its development is genetically associated with an increased (>4) copy number (CN) in the KIT Ligand gene (KITLG). On that account, the aim of this research was to evaluate the potential association between malignant histological features of CDSCC based on two different adapted histological grading systems and CN of KITLG.

Materials and Methods

We histologically graded 61 CDSCC from 59 dogs with paired whole-blood samples. The animals were divided as follows; Group 1.a/black non-Schnauzers ($n = 15$); group 1.b/black Schnauzers ($n = 33$); group 1.c/black and tan dogs ($n = 7$); group 2/tan animals ($n = 4$). KITLG CNV was determined by ddPCR on the blood.

Results

The KITLG CN was between 2.02 and 9.14 (mean value = 5.6). The mean KITLG CN for each of the groups was always above 4, ranging between 4.5 and 5.8. Additionally, there was a significant association between KITLG CN and CDSCC histological grade. Animals with a higher KITLG CN had more histological features of malignancy and overall grade in CDSCC. This was independent from colour and/or sex.

Conclusions

This study allowed not only to correlate the presence of CDSCC to elevated KITLG CN, but also to its histological grade of malignancy. This corroborates previous studies and additionally may suggest that KITLG could be associated with DSCC development and, potentially, spreading and clinical behaviour.

Oral Abstracts Veterinary Pathology

SESSION 7: TUMOUR PATHOLOGY
FRIDAY 1 SEPTEMBER | 12.03-12.16

EXPRESSION OF THE INHIBITOR-OF-APOPTOSIS SURVIVIN IS ASSOCIATED WITH POOR PROGNOSIS IN CANINE INVASIVE MAMMARY CARCINOMA

M. Cuvelier, C. Humeau, L. Favennec, F. Lézin, L. Jaillardon and J. Abadie

LabOniris, Oniris-Ecole Nationale Vétérinaire, Agroalimentaire et de l'Alimentation, Nantes, FR

Introduction

Survivin is a well conserved member of the inhibitor-of-apoptosis family, coded by the gene BIRC5 and expressed in proliferative tissues during foetal development and neoplastic transformation. It is suggested to be involved in cancer progression by reducing cell adhesion and promoting mitosis and angiogenesis. Its overexpression in human breast cancer is associated with poorer prognosis. Survivin is also expressed in canine mammary tumours, the most prevalent neoplasms in intact female dogs, but its prognostic value remains unclear. This study aimed to retrospectively assess the expression of survivin and its prognostic value in canine invasive mammary carcinomas (IMC).

Materials and Methods

Epidemiological, clinical, and histopathological data of 39 female dogs diagnosed between 2011 and 2015 with IMC were reviewed, and survivin tissue expression was assessed by immunohistochemistry on formalin fixed samples. Correlation between parameters was studied using Fischer's exact test or ANOVA and their prognostic value then determined with Kaplan Meier's method.

Results

Survivin tissue expression with a threshold defined at 10% of positive neoplastic cells in canine IMC was found to be positively correlated to clinical stage, histological grade, the presence of lymphovascular emboli and a high mitotic index. It was associated with shorter overall and specific survival time, distant-metastasis free interval and disease-free interval in univariate analysis.

Conclusions

These data highlight the association of survivin expression with poor outcome in canine IMC and support its immunohistochemical assessment as part of prognosis establishment. Its potential use as a serological biomarker for tracing cancer progression is under investigation.

Oral Abstracts Veterinary Pathology

SESSION 8: ANIMAL MODELS
FRIDAY 1 SEPTEMBER | 16.00-16.11

NEURONAL AND MYOCARDIAL DAMAGE IN A RAT MODEL OF VENTRICULAR FIBRILLATION CARDIAC ARREST WITH EXTRACORPOREAL CARDIOPULMONARY RESUSCITATION

S. Högl^{*}, A.M. Warenits[†], I.A.M. Magnet[†], M. Müller[†], A. Szinovats[†], P. Kodajova^{*}, J. Kaschmekat^{*}, T. Schütz[‡], M. Holzer[†] and W. Weihs[†]

^{}Unit of Laboratory Animal Pathology, Department of Pathobiology, University of Veterinary Medicine Vienna and [†]Department of Emergency Medicine and [‡]Center for Biomedical Research, Medical University of Vienna, Vienna, AT*

Introduction

Extracorporeal cardiopulmonary resuscitation (ECPR) may restore spontaneous circulation after cardiac arrest (CA) when conventional resuscitation attempts fail. However, CA survivors often suffer from neurologic sequelae. This study aimed to establish a rat model of ventricular fibrillation CA with subsequent ECPR that leads to consistent neuronal damage.

Materials and Methods

Adult male Sprague Dawley rats were subjected to 6 (n=15) or 8 (n=16) min of CA and resuscitated with ECPR. Ten sham operated animals served as controls. ECPR consisted of an open reservoir, a roller pump, and a membrane oxygenator, combined with mechanical ventilation. Surviving rats were sacrificed after two weeks, and brain and heart sampled. Viable neurons were counted in HE stained sections of the hippocampal CA1 region. Activation of microglia and astrocytes was assessed by Iba1 and GFAP immunohistochemistry, respectively. Collagen fibres in the myocardium were highlighted in Azan-stained sections. QuPath served to quantify positive pixels.

Results

Ten 6 min and five 8 min CA animals reached the endpoint. The number of viable neurons was significantly reduced and the area of Iba1 and GFAP positive pixels was significantly increased in the hippocampus of both CA groups, without differences between the CA groups. The amount of collagen fibres in the myocardium was significantly increased in the 8 min CA group compared to controls, but not the 6 min CA group.

Conclusions

Both CA times led to consistent neuronal damage in the hippocampus in this model. However, survival was reduced after 8 min CA, possibly due to myocardial damage.

Oral Abstracts Veterinary Pathology

SESSION 8: ANIMAL MODELS

FRIDAY 1 SEPTEMBER | 16.11-16.22

PATHOLOGICAL AND TRANSCRIPT ANALYSIS OF PROTECTION INDUCED BY MTBVAC AND BCG AGAINST MYCOBACTERIUM TUBERCULOSIS INFECTION IN RHESUS MACAQUES

F.J. Salguero*, J. Medley†, L. Hunter‡, I. Ruedas-Torres*, A. Bird*, E. Puentes§, E. Rodriguez§, S.J. Waddell†, C. Martin¶ and S. Sharpe*

*Pathology, UKHSA and †Brighton and Sussex Medical School, GB, §Biofabri and ¶Universidad de Zaragoza, ES

Introduction

Tuberculosis (TB) is the leading cause of death of humans from a single infectious agent worldwide. Non-human primate (NHP) animal models are widely used to test vaccines and therapeutics against TB. BCG (Bacillus Calmette-Guérin) is the only currently available vaccine against TB. New vaccines are in the preclinical and clinical pipeline evaluation, including MTBVAC, a live-attenuated strain of Mycobacterium tuberculosis (Mtb), designed to stimulate specific host immune responses mimicking natural TB infection without causing disease, by the deletion of major virulence genes. The current project studied the protection conferred by MTBVAC or BCG in adult Rhesus macaques (*Macaca mulatta*) by means of histopathology, immunohistochemistry (IHC) and tissue transcript analysis.

Materials and Methods

We have used three groups of 8 rhesus macaques (BCG, MTBVAC and unvaccinated), challenged with an ultra-low dose of Mtb. Histopathological analyses included a granuloma scoring system to determine the severity and distribution of TB lesions in the lungs. IHC was used to determine the distribution of cell populations within the granulomas. Nanostring was used with FFPE sections to map host immune transcript abundance.

Results

MTBVAC animals showed a reduction in the frequency and severity of lesions compared with BCG. The small number of granulomas observed in MTBVAC animals showed earlier stages of development compared to BCG and more significantly with unvaccinated animals. Transcript analysis revealed upregulation of proinflammatory cytokines and chemokines in unvaccinated animals, mirroring the pathological processes.

Conclusions

MTBVAC conferred a significant improvement in the pathological outcomes compared to BCG.

Oral Abstracts Veterinary Pathology

SESSION 8: ANIMAL MODELS
FRIDAY 1 SEPTEMBER | 16.22-16.33

USUTU VIRUS EXPERIMENTAL INFECTION IN EURASIAN BLACKBIRDS (TURDUS MERULA): A STEP TOWARDS THE IDENTIFICATION OF AN EXPERIMENTAL AVIAN MODEL

G. Agliani*, **I. Visser†**, **E.M. Marshall†**, **G. Giglia‡§**, **E. de Bruin¶**, **R. Verstappen***, **T. van Mastrigt*‡**, **M.P.G. Koopmans†**, **A. Gröne*^Δ**, **B. Rockx†** and **J.M.A. van den Brand*^Δ**

**Biomolecular Health Sciences, Veterinary Medicine, †Virosciences, Erasmus Medical Center, Rotterdam, NL, ‡Biomolecular Health Sciences, Veterinary Medicine, Utrecht University and §Veterinary Medicine, University of Perugia, Perugia, IT, ¶Biomolecular Health Sciences, Veterinary Medicine and *Animal Ecology, Netherlands Institute of Ecology (NIOO-KNAW), *Vogeltrekstation, Dutch Centre for Avian Migration and Demography (NIOO-KNAW), Wageningen, NL and ^ΔDutch Wildlife Health Centre (DWHC), Utrecht University, Utrecht, NL*

Introduction

Usutu virus (USUV) is an emerging zoonotic arbovirus. Eurasian blackbirds (*Turdus merula*) are particularly susceptible to develop severe disease after infection. USUV associated pathological changes have been investigated in naturally infected birds, although a suitable experimental avian model is still needed to study the pathogenesis. This project aimed to identify an experimental model of severe disease to study the pathogenesis in an avian host. We hence infected blackbirds with USUV to establish reference parameters of the disease in a particularly susceptible host.

Materials and Methods

Six blackbirds were divided in two groups of three birds and challenged with USUV lineage Africa 3 and Europe 3, respectively. Health status, weight and activity levels were monitored daily. Blood, pharyngeal and cloacal swabs and feathers were sampled every other day. Spontaneously dead and euthanized animals were necropsied, and tissues were sampled for histopathology, immunohistochemistry, RT-PCR and virus titration.

Results

Infected animals started showing signs of general illness and succumbed to disease within a week. Virus RNA was detected by PCR and tissue titration in analyzed tissues. Pathological lesions and virus antigen distribution matched what was previously observed in naturally infected birds.

Conclusions

Blackbirds are susceptible to experimental USUV infection and can be used as animal model for severe disease. However, the limited commercial availability of these animals make it difficult to use them as experimental model. This experiment set the reference parameters of severe USUV infection in an avian host for comparison with other suitable species.

Oral Abstracts Veterinary Pathology

SESSION 8: ANIMAL MODELS
FRIDAY 1 SEPTEMBER | 16.33-16.44

VASCULAR CHANGES IN ASSOCIATION WITH NON-SUPPURATIVE ENCEPHALITIS IN SARS-COV-2 INFECTED K18-HACE2 MICE

S. De Neck*, **U. Hetzel***, **S. Parul†**, **E.G. Bentley†**, **A. Kirby†**, **F. Seehusen***, **J.P. Stewart†** and **A. Kipar*†**

**Laboratory for Animal Model Pathology, Institute of Veterinary Pathology, Vetsuisse Faculty, University of Zurich, Zürich, CH and †Department of Infection Biology and Microbiomes, Institute of Infection, Veterinary and Ecological Sciences, University of Liverpool, Liverpool, GB*

Introduction

Neurological symptoms have been reported frequently in COVID-19 patients but the underlying pathological processes are not fully understood. The K18-hACE2 mouse model of COVID-19, where widespread infection of the brain, with and without overt non-suppurative encephalitis, is observed, can serve to address the potential role of blood vessels in the pathogenesis. The present study aimed to investigate the vascular reaction in the brain of mice infected with SARS-CoV-2. It has its focus on morphological changes of the blood vessels, with emphasis on the recruitment of leukocytes, the disruption of the blood brain barrier, and the potential SARS-CoV-2 infection of endothelial cells.

Materials and Methods

The brains of K18-hACE2 mice intranasally infected with the SARS-CoV-2 Delta variant (5-7 dpi; $10^2/10^3$ PFU) were examined by light and transmission electron microscopy, including immunostaining for SARS-CoV-2 proteins, AQP4, CD31, PDGFR β , and α SMA.

Results

Light and transmission electron microscopy showed endothelial activation and leukocyte recruitment at the level of venules and capillaries, with leukocyte accumulation in the perivascular space and limited further emigration in the neuroparenchyma. Vessel involvement was locally restricted mainly to the brainstem despite global infection of the brain. There was no evidence of SARS-CoV-2 infection of endothelial cells or structural disruption of the vessel wall. Viral elements and antigen were only detected in neurons which generally appeared otherwise unaltered.

Conclusions

The results provide strong evidence that the inflammatory environment in the brain, resulting from the neuronal SARS-CoV-2 infection, induces the recruitment of leukocytes into the perivascular space and neuroparenchyma.

Acknowledgements: The work received support from the European Union's Horizon Europe research and innovation programme under grant agreement No 101057553 and the Swiss State Secretariat for Education, Research and Innovation (SERI) under contract number 22.00094.

Oral Abstracts Veterinary Pathology

SESSION 8: ANIMAL MODELS

FRIDAY 1 SEPTEMBER | 16.44-16.55

COULD HAMSTERS BE A MODEL FOR RESPIRATORY POST-ACUTE SEQUELAE OF SARS-COV-2?

L. Heydemann*, **M. Ciurkiewicz***, **T. Störk***, **K. Hülskötter***, **K.M. Gregor***, **L.M. Michaely***, **W. Reineking***, **T. Schreiner***, **A. Volz^{†,‡}**, **M. von Köckritz-Blickwede^{§,‡}**, **T. Tuchel^{†,‡}**, **C. Meyer zu Natrup^{†,‡}**, **L.M. Schünemann^{†,‡}**, **S. Clever^{†,‡}**, **W. Baumgärtner*** and **F. Armando***

**Department of Pathology, [†]Department of Virology, [‡]Research Center for Emerging Infections and Zoonoses (RIZ) and [§]Department of Biochemistry, University of Veterinary Medicine, Hanover, DE*

Introduction

We previously established that the hamster model for COVID-19 features alveolar regeneration processes, which mimic the situation in humans after SARS-CoV-2 infection. Until 14 days post infection (dpi), epithelial proliferation areas, consisting of a heterogeneous population of cells, were detected in the alveoli. They were dominated by alveolar differentiation intermediate (ADI) cells, CK14+ airway progenitors (AWP) or SCGB1A1+ club cells with sub-pleural fibrosis. The aim of this study was to determine the presence of these changes after a prolonged time-period post infection and to correlate pathomorphological changes with functional readouts.

Materials and Methods

112 male, 11-12 months old, golden Syrian hamsters were infected with either SARS-CoV-2-Delta variant or received PBS. Functional data was obtained by using a whole body plethysmograph in combination with exercise on a rodent treadmill. Animals were sacrificed at 1, 3, 6, 14, 28, 56 and 112 dpi. At necropsy, arterial blood was collected and analyzed using a hemogas analyzer. Lungs were evaluated for histopathological changes. The immunohistochemical expression of CK8 (ADI) and CK14 (AWP) was evaluated by means of digital quantitative analysis.

Results

Infected animals showed prominent epithelial cell proliferation and sub-pleural fibrosis. These lesions were observed as late as 112 dpi. Functional data revealed a transient decrease of lung function that was more evident after physical exercise. No significant changes were detected by the hemogas analysis.

Conclusions

Hamsters represent a very suitable model to study SARS-CoV-2-induced long-term pulmonary changes at both the pathomorphological and the functional level.

Acknowledgements: This project was partially supported by the COVID-19 Research Network of the State of Lower Saxony (COFONI) with funding from the Ministry of Science and culture of Lower Saxony, Germany (14-76403-184, FA, WB, MC). Furthermore, this research was partially supported by Deutsche Forschungsgemeinschaft (DFG; German Research Foundation) -398066876/GRK 2485/1, WB, LH, TS).

Oral Abstracts Veterinary Pathology

SESSION 8: ANIMAL MODELS
FRIDAY 1 SEPTEMBER | 16.55-17.06

NERVE REGENERATION AFTER TRAUMA-INDUCED WALLERIAN DEGENERATION: WHAT DO WE LEARN FROM MURINE ANIMAL MODELS?

R. de Miguel, K. Weber, A. Liens, H. Winkler, Z. Hovádková, P. Kamat, P. Ortega, K. Kegler, O. Richard, R. Vallejo and N. Warfving
AnaPath Services GmbH, CH

Introduction

Nerve regeneration represents a promising avenue for the treatment of nerve injuries. Animal models are crucial for evaluating medical devices and provide a rationale for studying the processes of degeneration induced by trauma and regeneration in peripheral nerves. This study describes the progression of histopathological findings in multiple medical device studies with murine models of sciatic nerve transection.

Materials and Methods

Control groups, including non-implanted (Sham Control) and commercial devices (Reference Item), were analyzed in murine models of sciatic nerve transection. Transected gaps ranged from 0 mm (Non-Gap studies) to 10 mm (Critical nerve defect studies). Necropsy timepoints ranged from 0 to 26 weeks post intervention. Hematoxylin-eosin, Masson's Trichrome, Luxol Fast Blue stains and S100 and NF200 immunohistochemistry were applied. Histomorphometry of myelin sheaths was performed on Toluidine Blue stained sections.

Results

Nerve transection was followed by mild nerve fiber degeneration at the proximal edge of the gap and complete degeneration at the distal edge. Host reaction was more prominent in Reference Item groups compared to Sham Control groups. At the proximal edge, Schwann cells were aligned longitudinally (Bands of Büngner) and associated with regrowing axons. Over time, nerve regeneration progressed from proximal to distal, with maturation of regenerated nerve fibers. Sham Control animals frequently showed incomplete regeneration, misdirected growth, adhesion to surrounding structures, and neuromas.

Conclusions

These findings contribute to a better understanding of nerve degeneration and regeneration processes, offering insights into trauma-induced neuropathies that can guide the development of medical devices for nerve repair.

Oral Abstracts Veterinary Pathology

SESSION 8: ANIMAL MODELS
FRIDAY 1 SEPTEMBER | 17.06-17.17

MITOCHONDRIAL DEFECTS IN THE PARL DEFICIENT MOUSE MODEL LEAD TO ARRESTED SPERMATOGENESIS AND FERROPTOSIS

E. Radaelli*, C.A. Assenmacher*, J. Verrelle*, E. Banerjee*, F. Manero†, S. Khiati†, A. Girona†, G. Lopez-Lluch‡, P. Navas‡ and M. Spinazzi†

**Pathobiology, School of Veterinary Medicine, University of Pennsylvania, Philadelphia, US, †University of Angers, Angers, FR and ‡Universidad Pablo de Olavide, Seville, ES*

Introduction

Impaired spermatogenesis and male infertility are common manifestations of mitochondrial diseases, but the underlying mechanisms are unclear.

Materials and Methods

The testicular phenotype of mice deficient for the mitochondrial intra-membrane rhomboid protease PARL was characterized at morphological, bioenergetic, and molecular levels by means of immunohistochemistry, electron microscopy, high-resolution respirometry, and other assays to assess mitochondrial function.

Results

PARL-deficient mice developed postpubertal testicular atrophy with a complete arrest of spermatogenesis at the level of meiosis I, followed by germ cell death. Genetic modifications of PINK1, PGAM5, and TTC19, three major substrates of PARL with important roles in mitochondrial homeostasis, did not reproduce or modify this severe phenotype. PARL deficiency in spermatocytes led to severe abnormalities in the mitochondrial structure associated with prominent electron transfer chain defects, alterations in Coenzyme Q biosynthesis and redox status, and adaptive metabolic remodeling with GLUT1 overexpression. Ablation of PARL abrogated GPX4 expression specifically in arrested primary spermatocytes, but not in other cell types, committing them to massive ferroptosis, an iron-dependent regulated cell death modality characterized by uncontrolled lipid peroxidation.

Conclusions

Mitochondrial defects, such as those induced by depletion of PARL, spontaneously initiate ferroptosis in primary spermatocytes by simultaneous effects on GPX4 and Coenzyme Q. These results advance our understanding of the physiological roles of mitochondrial intramembrane proteolysis in the maintenance of mitochondrial fitness and establish ferroptosis as a stage-specific consequence of impaired mitochondrial function in premeiotic spermatocytes. Hence, ferroptosis warrants to be further scrutinized in the pathogenesis of mitochondrial diseases and male infertility.

Acknowledgements: This study was supported by the University of Pennsylvania URF research funding to ER (URF Fall 19-0914) and AFM Telethon to MS (23019). MS is supported by an INSERM translational research position (CIHU ISERM).

Oral Abstracts Veterinary Pathology

SESSION 8: ANIMAL MODELS
FRIDAY 1 SEPTEMBER | 17.17-17.27

IMPACT OF THE CGAS/STING PATHWAY ON THE TUMOUR ECOSYSTEM UNDER CHEMOTHERAPEUTIC PRESSURE IN TRIPLE NEGATIVE BREAST CANCER

F. Chocteau, F. Briand, F. Gautier, P. Juin, F. Nguyen and S. Barillé-Nion

Team 7 - Stress, Adaptation and Tumor Escape, CRCI2NA - Cancer Research Center Nantes Angers, NANTES, FR

Introduction

Triple negative breast cancers (TNBCs) are of poor prognosis due to a high metastatic propensity and a therapeutic resistance to classical treatment, though new drugs are still developed, including immunotherapies to reactivate the immune microenvironment. In this context, this study investigated the tumour-intrinsic cGAS/STING pathway (known for both anti- or pro-tumour inflammatory activity) under antimitotic chemotherapeutic pressure, in a murine model of TNBCs (4T1-Luc).

Materials and Methods

4T1-Luc cells expressing STING (4T1-LucSTING^{+/+}) or not (4T1-LucSTING^{-/-}, obtained by CRISPR-Cas9 approach) were allografted in the fourth fat pad of immunocompetent Balb/c mice that were treated once with Paclitaxel (antimitotic chemotherapy, Day 5). Tumors were removed early (Day 12) and tumour ecosystems (epithelial and immune cells) were analyzed by single-cell RNA sequencing (scRNAseq), flow cytometry and immunohistochemistry.

Results

We observed that intrinsic tumour STING contributed to tumour anti-proliferative response to chemotherapy with a lower Ki-67 index in 4T1-LucSTING^{+/+} (0.67-fold, p=0.0003). Furthermore, tumour STING also modulated the immune microenvironment, both innate and adaptive, with decreased numbers of CD3⁺ T cells (0.61-fold, p=0.0193), notably FOXP3⁺ T regulators (0.60-fold, p=0.0356) and increased numbers of B cells (3.6-fold, scRNAseq), NK cells (2.1-fold, scRNAseq), type 1 Innate Lymphoid Cells (2.4-fold, scRNAseq) and Iba1⁺ macrophages (1.29-fold, p=0.0389) with a more M1-like macrophage phenotype (scRNAseq) in 4T1-LucSTING^{+/+} than in 4T1-LucSTING^{-/-} tumours.

Conclusions

The results help to better understand the role of the cGAS/STING pathway in the TNBCs ecosystem early after chemotherapy and would allow to propose new drugs to maximize the effects of classical treatments.

Oral Abstracts Veterinary Pathology

SESSION 9: FORENSIC MATTERS
FRIDAY 1 SEPTEMBER | 16.00-16.15

GROSS, HISTOLOGICAL, AND CHEMICAL EVALUATION OF GUNSHOT WOUNDS IN VETERINARY FORENSIC PATHOLOGY

G. Piegari*, **I. d'Aquino***, **L. Riccio***, **D. De Biase†**, **V. Salanti*** and **O. Paciello***

**Department of Veterinary Medicine and Animal Production, University of Naples "Federico II, Napoli, IT and †Department of Pharmacy, University of Salerno, Fisciano, IT*

Introduction

The forensic evaluation of gunshot wounds is essential to characterize the injury and define the range of fire. The present study investigated the macroscopic, histological, and chemical modifications of gunshot wounds both in animals that died from gunshot trauma and in cadavers shot at different shooting distances.

Materials and Methods

Eleven animals were divided into three groups. Group A comprised two pig heads shot at a firing ground from a distance of 0.05 and 1 m; group B comprised eight dog limbs shot from a distance of 0.05, 1 and 6 m; group C comprised 7 animals (3 cattle, 3 dogs and 1 wolf) who died for gunshot trauma. Macroscopic and histological examination was performed on all gunshot wounds. Lead residues were investigated using both macroscopic and microscopic chromogenic tests, Bullet Hole Testing Kit (BTK) and Rhodizonate Sodium histochemical staining (NaR-s), respectively.

Results

Gunshot wounds in group A showed circular or ovoidal morphology with identifiable sooty area. Histological examination also showed black material on the wound surface. No macroscopically evident sooty areas were observed in other groups. Chromogenic tests showed positive results in all cases in groups A and C and in group B cases shot from a distance of 0.05 m. Positivity with 1 m and 6 m distance was observed in 3/6 cases for BTK and in 5/6 cases for NaR-s.

Conclusions

Our results suggest that the chromogenic tests and pathological examination represent valid tools to investigate gunshot wounds, even in cases of long-range shooting.

Oral Abstracts Veterinary Pathology

SESSION 9: FORENSIC MATTERS
FRIDAY 1 SEPTEMBER | 16.15-16.30

FORENSIC EVALUATION OF TAIL LESIONS IN PIGS: HISTOLOGICAL AND RADIOLOGICAL OBSERVATIONS

C.K. Flyger, C.B. Becker, B.M. Jørgensen and H.E. Jensen

Department of Veterinary and Animal Sciences, University of Copenhagen, Frederiksberg, DK

Introduction

A forensic case comprising 67 pigs with tail lesions (bites) of varying degrees were sent to the University of Copenhagen for pathoanatomical examination, including histological and radiological evaluation of 30 tails.

Materials and Methods

The tails were divided into four groups based on gross inspection: 1) total lack of the tail [0-2 cm]; 2) short [2-6.7 cm] and thickened tails; 3) long [5.5-7.5 cm] and thickened tails, and 4) tails with wounds at the tip, but without or with minimal thickening [3-8.4 cm]. Tails selected for histological and radiological evaluation originated from all four groups.

Results

The histological evaluation showed varying degrees of bone involvement while the soft tissue structures showed necrosis, leukocyte infiltrations, bacterial colonization as well as fibroplasia and angiogenesis. The radiological evaluation revealed necrosis, osteolysis and osteomyelitis, dominating in groups 1, 2 and 3. Further, periosteal reactions with extensive new bone formation were present in all four groups, however especially in groups 1 and 2.

Conclusions

Thickened tails exhibited extensive histopathological changes including both the soft and bony tissues. In general, changes in the soft tissue were characterized by necrosis, cellular infiltrations, and proliferation of fibroblasts while the radiological changes included sclerosis, lucency, osteomyelitis, and osteoproliferation. In conclusion, all changes revealed chronic lesions and several were consistent with violation of the Danish Animal Protection Act and Transportation Regulations.

Oral Abstracts Veterinary Pathology

SESSION 9: FORENSIC MATTERS
FRIDAY 1 SEPTEMBER | 16.30-16.45

SKIN ULCERATIONS IN DANISH NURSERY PIGS

K. Barington*, **K. Pankoke***, **K.T. Hartmann***, **M.S. Hansen***, **H.E. Jensen***, **S.A. Blirup-Plum***, **B.M. Jørgensen***, **J.P. Nielsen***, **E.Ø. Eriksen***, **E. Kudirkiene***, **J.E. Olsen*** and **K.S. Pedersen*†**

**Department of Veterinary and Animal Sciences, University of Copenhagen, Frederiksberg C, DK and †Ø-Vet A/S, Næstved, DK*

Introduction

Acute ulcerations in the skin are painful and may serve as portals of entry for bacterial infections. The aim of the study was to investigate the prevalence of skin ulcerations among nursery pigs that died or were euthanized for welfare reasons and to assess the histological changes in necrotic ear and tail ulcerations.

Materials and Methods

A total of 268 nursery pigs from five intensive indoor herds were necropsied, and skin ulcerations were registered. Necrotic ulcerations on the ears and tails of 64 and 17 randomly selected pigs, respectively, were assessed histologically.

Results

Out of 268 pigs 204 (76.1%) had one or more ulcerations located on the ears (n=160), the tail (n=93), limbs (n= 49), head (n=22), umbilical outpouchings (n=14) and on other body parts (n=26). At gross evaluation ear and tail ulcerations were characterized as necrotizing in 111 out of 160 pigs and in 62 out of 93 pigs, respectively. Necrotic ear ulcerations were bilateral in 72 pigs. Tail ulcerations were accompanied by sequestration of coccygeal vertebrae. Histologically, necrosis was present in 96.9% and 88.2% of the ear and tail ulcerations, respectively. Leukocyte infiltration was seen in 53.1% and 64.7 % of the ear and tail ulcerations, respectively. Thrombosis was present in 45.3% and 64.7% of ear and tail ulcerations, respectively. Moreover, signs of healing were present in 17.2% and 11.8% of the ear and tail ulcerations, respectively.

Conclusions

Skin ulcerations are frequent in dead Danish nursery pigs including severe, necrotizing ulcerations that constitute an animal welfare concern.

Acknowledgements: The research was funded by the Danish Veterinary and Food Administration.

Oral Abstracts Veterinary Pathology

SESSION 9: FORENSIC MATTERS
FRIDAY 1 SEPTEMBER | 16.45-17.00

BETA-AMYLOID PRECURSOR PROTEIN (β APP) AS A BIOMARKER FOR DETECTING TRAUMATIC AXONAL INJURY IN CATS

W.H. Huang and P.W. Liao

The Graduate Institute of Molecular and Comparative Pathobiology, National Taiwan University, Taipei City, TW

Introduction

Traumatic brain injury (TBI) is one of the most common causes of death in veterinary forensic cases, and traumatic axonal injury (TAI) is almost a universal consequence of TBI. The immunohistochemistry (IHC) against beta-amyloid precursor protein (β APP) is a gold standard for the detection of early axonal injuries in human forensic neuropathology, but to date, the application of β APP-IHC in animals is limited. The study aims to detect TAI in cats with head injury by β APP IHC and correlate the severity of head injury to histopathological and immunohistochemical findings in TAI.

Materials and Methods

Fifty-nine cat carcasses were collected from routine forensic necropsy cases, including thirty-nine with head injury (two trauma subgroups) and twenty without head injury (control group). Entire brains were collected and underwent appropriate fixation, representative sections were selected following standardized serial sectioning. The β APP positive signals (axonal retraction bulbs) were calculated in brains with head injury and correlated to the severity of the head injury.

Results

A total of 64.1% of head injury cases showed evidence of axonal injury. The total axonal bulb count (ABC) was remarkably increased in severe head injury cases, and the regional ABC was significantly higher in severe head injury cases in corpus callosum, cerebral white matter, and hippocampus. The most frequent location of axonal bulbs was the cerebral white matter. The shortest post-traumatic interval for the presence of axonal bulbs was between 0.5-2 hours.

Conclusions

The results shed light on the early detection of TAI in companion animals.

Oral Abstracts Clinical Pathology

SESSION 1: HEMATOLOGY

THURSDAY 31 AUGUST | 11.45-12.00

ESTABLISHING A MURINE MODEL ON LOW-DENSITY NEUTROPHILS GRANULOPOIESIS FOR PAEDIATRIC CEREBRAL MALARIA

C. Attipa^{1,2,3,7}, **D. McGuinness**³, **C. Johnson**³, **B. Amulic**⁴, **C. Rice**⁴, **B. Stokes**³, **L. L. Soares**³, **K. Fleming**⁴, **A. Chardas**⁶, **V. Herbert**³, **A. Craig**¹, **S. Abrams**⁵, **C. Moxon**^{2,3}, **J. Brewer**³

¹Liverpool School of Tropical Medicine, Liverpool, UK

²Malawi-Liverpool-Wellcome Trust Clinical Research Programme, Kamuzu University of Health Sciences, Blantyre, Malawi

³Wellcome Centre for Integrative Parasitology, University of Glasgow, Glasgow, UK

⁴University of Bristol, Bristol, UK

⁵University of Liverpool, Liverpool, UK

⁶Royal Veterinary College, London, UK

⁷The Royal (Dick) School of Veterinary Studies and The Roslin Institute University of Edinburgh, The University of Edinburgh, Edinburgh, UK

Background

Cerebral malaria (CM) caused by *Plasmodium falciparum* accounted for >500,000 paediatric deaths in 2022. We recently identified a sub-population of neutrophils called low-density-neutrophils (LDNs) that were associated with CM compared to other causes of paediatric coma. LDNs in CM were evaluated using light and electron microscopy, flowcytometry, neutrophils extracellular traps (NETs) and RNA-sequencing. The previous showed that LDNs were immature, hyper-activated, pro-inflammatory with increased NETs and mitochondria. NETs are vasculopathic and can contribute to BBB dysfunction, coma, and fatal outcome. Currently there is no mouse model of CM to investigate and test interventions regarding LDNs.

Aim

Develop a murine model of granulopoiesis in CM that leads to the formation of LDNs similar to these found in children.

Methods

C57BL/6 mice infected with *P. berghei* were used to investigate presence, ontogeny and trajectory progression of LDNs. Day-5/Day-6 post-infection, the BM and blood were harvested with LDNs and normal-density neutrophils (NDNs) isolated from these two organs. The isolated sub-sets of neutrophils underwent cytomorphological analysis, electron microscopy, flowcytometry, NETs formation and bulk RNA-sequencing.

Results

P. berghei infection caused a progressive neutrophilia and left shift in the BM with LDNs becoming the dominant sub-set in blood and BM. The murine LDNs in this mouse model had increased spontaneous NETs formation, mitochondria and granules indicating a pro-inflammatory status. **Discussion:** The current murine model, replicates closely the LDNs found in paediatric CM. It provides the 1st evidence regarding the ontogeny and trajectory progression of LDNs in the BM, paving the way for experimental anti-NETotic treatments.

Oral Abstracts Clinical Pathology

SESSION 1: HEMATOLOGY

THURSDAY 31 AUGUST | 12.00-12.15

BOMBAY-LIKE DISCORDANCE BETWEEN ABC BLOOD GENOTYPE AND PHENOTYPE IN A DOMESTIC SHORT-HAIRED CAT

A. Ginoudis¹, B. Canard², A. Kehl^{3,4}, U. Giger⁵, C. Koutinas⁶, S. Christoforaki⁶, E. Smyroglou¹, Z. Polizopoulou¹ and M.E. Mylonakis⁶

¹Diagnostic Laboratory, School of Veterinary Medicine, Faculty of Health Sciences

²Alvedia, Limonest, France

³Laboklin GmbH&Co., Bad Kissingen, Germany

⁴Comparative Experimental Pathology, School of Medicine, Technical University of Munich (TUM), Munich, Germany

⁵Vetsuisse Faculty, University of Zürich, Zürich, Switzerland

⁶Companion Animal Clinic, School of Veterinary Medicine, Faculty of Health Sciences, Aristotle University of Thessaloniki, Thessaloniki, Greece

Background

In the feline ABC blood group system, there are three blood types (type A, B, and C [ABC]) based upon immunodiagnostics and cytidine monophosphate-N-acetyl-neuraminic acid hydroxylase (CMAH) genotyping. A 4.5-year-old, DSH cat was referred to a Veterinary Teaching Hospital with evidence of chronic kidney disease. Due to the worsening anemia requiring transfusion, blood typing was requested.

Objective

We report a genotype-phenotype discordance in a transfusion-naive cat apparently lacking both the A and B antigen.

Methods

Blood typing was performed by an immunochromatographic strip assay (Feline QuickTest BT, Alvedia) several times at different time points. For the major and minor crossmatching test, plasma or red blood cells (RBCs) from recipient and 2-3 type A and 2 type B donor cats, respectively, were admixed in a gel column test. A genotyping panel of 4 CMAH variants was assessed.

Results

No discrete A or B bands appeared on the immunochromatographic strip, as opposed to the control band for the recipient cat. The recipient's plasma agglutinated RBCs from tested A and B cats. The recipient's RBCs were compatible with plasma from type A and B donors except with one type A plasma. Genotyping of recipient blood revealed a single homozygous c.179>T CMAH variant predicting a type B.

Conclusion Blood type studies of this cat resemble the exceedingly rare Bombay phenotype in the human ABO blood group system, although a precursor substrate to the N-acetylneuraminic acid analogous to the H antigen in the ABO system has yet to be identified in cats.

Oral Abstracts Clinical Pathology

SESSION 1: HEMATOLOGY

THURSDAY 31 AUGUST | 12.15-12.30

PLASMA MRNA LEVELS OF CDC6 DECREASE IN RESPONSE TO CHEMOTHERAPY IN CANINE LYMPHOMA PATIENTS

A. Seijger^{*†}, A. Musi[‡], M.M.J.M. Zandvliet[†], M.E. Kuipers^{*}, F.E.M.M. van der Steen[†], V. Rinaldi[‡], E.N.M. Nolte-’t Hoen^{*}, L. Bongiovanni^{*‡} and A. de Bruin^{*§}

^{}Department of Biomolecular Health Sciences and [†]Department of Clinical Sciences, Faculty of Veterinary Medicine, Utrecht University, Utrecht, NL, [‡]Department of Veterinary Medicine, University of Teramo, Teramo, IT and [§]Department of Pediatrics, University Medical Centre Groningen, University of Groningen, Groningen, NL*

Introduction

Lymphoma is one of the most commonly diagnosed cancers in veterinary oncology. CDC6, which is part of the E2F pathway, is significantly increased in the plasma of canine cancer patients and it is likely enclosed in the extracellular vesicles (EVs). The aim of this study was to investigate how CDC6 is expressed in canine lymphoma patients, whether CDC6 can be used to monitor treatment response, and whether CDC6 expression is related to EVs secretion.

Materials and Methods

The platelet free plasma (PFP) of 18 canine lymphoma patients throughout treatment and of 15 healthy controls was collected. EVs isolated from PFP by size exclusion chromatography followed by an ultracentrifugation step and a subsequent density gradient were then quantified by high-resolution flow cytometry. The abundance of the CDC6 mRNA in both the unfractionated plasma and the EVs was measured by digital droplet PCR. We introduced the 'CDC6 ratio', which is a ratio between the CDC6 total-mRNA expression in follow-up plasma samples of the patient to their pre-treatment sample.

Results

CDC6 is significantly overexpressed in the canine lymphoma patients compared to the controls. The CDC6 ratio decreases significantly upon good treatment response. Moreover, our findings implicate a correlation between CDC6 abundance and the number of circulating EV.

Conclusions

CDC6 represents a suitable candidate marker for a clinical screening test and it could have a potential clinical utility to monitor progression during treatment. Future experiments on expanding the cohort and on investigating CDC6's potential in predicting long term survival are recommended.

Oral Abstracts Clinical Pathology

SESSION 2: BIOCHEMISTRY

THURSDAY 31 AUGUST | 14.00-14.15

DETECTION OF RENAL TUBULAR TRANSPORTER PROTEINS IN CANINE URINARY EXTRACELLULAR VESICLES USING LIQUID CHROMATOGRAPHY TANDEM MASS SPECTROMETRY

L. McGravey¹, P. Antrobus², T. Williams¹

¹Department of Veterinary Medicine and ²Cambridge Institute for Medical Research, University of Cambridge, UK.

Background

Urinary extracellular vesicles (UEVs) are membranous particles released from kidney cells which carry tubular transporter proteins.

Objective

To demonstrate that selected renal tubular transporter proteins can be detected on UEVs isolated from small volume canine urine samples.

Methods

Urine samples were obtained from dogs with PTH/PTHrP dependent hypercalcaemia (n=6), hyperadrenocorticism (n=6), hypoadrenocorticism (n=3) and healthy dogs (n=6). Creatinine content of urine sample was calculated from urine volume and creatinine concentration. UEVs were isolated by size exclusion chromatography, prior to quantification by nanoparticle tracking analysis and proteomic analysis by liquid chromatography tandem mass spectrometry (LC-MS/MS). Group comparisons were made using non parametric statistics. Data are presented as median [range].

Results

UEV preparations from healthy dogs contained higher numbers of UEVs (7×10^9 [$6 \times 10^8 - 2 \times 10^{10}$]) than those from dogs with hypercalcaemia (3×10^8 [$1 \times 10^8 - 8 \times 10^9$]; $P=0.016$), hyperadrenocorticism (5×10^8 [$7 \times 10^7 - 2 \times 10^9$]; $P=0.01$) and hypoadrenocorticism (4×10^8 [$4 \times 10^8 - 6 \times 10^8$]; $P=0.02$). Aquaporin-2 (AQP2) and the renal sodium/phosphate co-transporter (NPT2A) were detected in 6/20 UEV preparations (isolated from urine of 6 healthy dogs for AQP2, and 5 healthy dogs and 1 hypoadrenocorticism dog for NPT2A) obtained from 3.7 [0.9-4.9] mL urine with total creatinine content of 44 [19-89] mol. AQP2 and NPT2A were detected in samples containing $>6 \times 10^8$ and $>4 \times 10^8$ UEVs (>22 mol and >19 mol creatinine) respectively. AQP2 and NPT2A were detected in all UEV preparations containing $>1 \times 10^{10}$ UEVs (>56 mol creatinine).

Conclusion

AQP2 and NPT2A were detectable by LC-MS/MS from $\sim 4-6 \times 10^8$ canine UEVs, however $>1 \times 10^{10}$ UEVs are likely needed for consistent detection.

Acknowledgements: European College of Veterinary Clinical Pathology who funded the work.

Oral Abstracts Clinical Pathology

SESSION 2: BIOCHEMISTRY

THURSDAY 31 AUGUST | 14.15-14.30

DETECTION OF TOTAL CELLULAR HISTAMINE IN BLOOD FROM CANINE AND FELINE PATIENTS USING A NOVEL BASOPHIL HISTAMINE RELEASE ASSAY

N. Nielsen¹, I. Schou¹, S. Esmail-Tehrani², P. Stahl Skov², M. Schjærff¹, L. N. Nielsen¹ and A. Krogh¹

¹Department of Veterinary Clinical Sciences, University of Copenhagen, Frederiksberg C, Denmark and ²RefLab, Copenhagen N, Denmark

Background

Atopic dermatitis (AD) is a common immune-mediated disease in both humans, dogs and cats. Basophils play a significant role in the pathogenesis of human AD and potentially also in veterinary species. Basophils release histamine when activated, contributing to inflammation. Histamine concentration could reflect an allergic response and be useful as a diagnostic tool for veterinary patients with allergies.

Objective

To investigate if total cellular histamine in whole blood from canine and feline patients, with or without basophilia and/or AD, can be measured in a basophil histamine release assay (BHRA) and a partial validation of the assay.

Methods

A prospective pilot case-control study including a partial validation. Dogs and cats presented to a University Animal Hospital due to either health-check, AD or an evaluation of varying inflammatory reactions were included. All patients had clinical examination, hematology and acute-phase protein analysis performed. Histamine concentrations were measured using a BHRA assay and the assay was partially validated. Group comparison and correlation tests were performed ($p < 0.05$).

Results

In both species the BHRA showed good recovery of spiked histamine but a low stability over time. 9/8 dogs/cats with basophilia and 16/7 dogs/cats without basophilia were included. In dogs histamine concentration was significantly increased in patients with basophilia (32 ng/mL) compared to dogs without basophilia (1 ng/mL); and correlation between histamine and basophil levels was present ($R^2 = 0.479$).

Conclusion

The BHRA assay performs in both dog and cat samples. For dogs, a difference and a correlation between total cellular histamine and basophil levels were present.

Oral Abstracts Clinical Pathology

SESSION 2: BIOCHEMISTRY

THURSDAY 31 AUGUST | 14.30-14.45

RELATIONSHIP BETWEEN INFLAMM-AGING AND MYXOMATOUS MITRAL VALVE DISEASE (MMVD) IN SENIOR AND GERIATRIC DOGS: PRELIMINARY RESULTS

F. Bonsembiante¹, C. Valente¹, C. Guglielmini¹, H. Poser¹, P. Zhong¹, I. Bernardis¹, S. Bedin¹, L. Mellia¹ and M.E. Gelain²

¹Department of Animal Medicine, Production and Health and ²Department of Comparative Biomedicine and Food Science, University of Padova, Legnaro (PD), Italy

Background

Ageing dogs are prone to developing degenerative diseases, including cardiovascular disease. They also experience changes in their immune system, leading to chronic low-level inflammation and increased oxidative stress known as "inflamm-aging." Myxomatous mitral valve disease (MMVD) is a common cause of congestive heart failure, and the progression of valve lesions is influenced by inflammatory mediators and cytokines.

Objective

To compare inflammatory and oxidative markers in aged dogs with MMVD and healthy age-matched dogs.

Methods

Seventy-four aged dogs were enrolled who underwent a comprehensive cardiologic examination and with complete hematologic, biochemical and serum protein electrophoresis exams. Dogs were classified as adult, senior and geriatric based on a combination of age and weight and healthy, preclinical and clinical based on MMVD severity. The Kruskal-Wallis test was used to assess differences between groups.

Results

There were 10 adult dogs (4 healthy and 6 pre-clinical), 26 senior dogs (5 healthy, 13 preclinical and 8 clinical), and 38 geriatric dogs (8 healthy, 19 preclinical and 11 clinical). Clinical geriatric dogs showed the highest leukocyte ($P=0.04$) and neutrophil ($P=0.03$) counts and increased beta1-globulins ($P<0.01$), creatinine ($P<0.01$), urea ($P<0.01$), and potassium ($P=0.02$). Preclinical geriatric dogs showed higher alfa2-globulins ($P=0.04$) and lower albumin ($P=0.01$). Other parameters, including the serum paraoxonase-1 (PON-1) oxidative stress marker, did not differ between the age and MMVD groups.

Conclusion

Geriatric dogs, regardless of their MMVD classification, show increased inflammation. To elicit the role of oxidative stress in the development and progression of MMVD, additional oxidative stress markers will be measured.

Oral Abstracts Clinical Pathology

SESSION 3: BIOCHEMISTRY

THURSDAY 31 AUGUST | 14.45-15.00

GLYCATED HAEMOGLOBIN (HbA1c) AND SERUM FRUCTOSAMINE IN SICK, NON-DIABETIC DOGS RECEIVING ORAL PREDNISOLONE: PRELIMINARY RESULTS

I. Oikonomidis¹, Z. Tzenetidou², J.J. Ceron³, A. Tvarijonaviciute³, F. Lambrou⁴, A. Daravigka², A. Konstantinidis² and N. Soubasis²

¹ IDEXX Laboratories, Wetherby, UK; ² School of Veterinary Medicine, Aristotle University of Thessaloniki, Greece; ³ Interdisciplinary Laboratory of Clinical Analysis, University of Murcia, Spain; ⁴ Labnet Laboratories

Background

HbA1c and serum fructosamine concentration reflect the average blood glucose concentration of the preceding 8-12 and 2-3 weeks, respectively. However, they have been scarcely studied in dogs on long-term corticosteroid therapy.

Objective

To study the HbA1c and serum fructosamine in non-diabetic dogs receiving oral prednisolone.

Methods

This was a cross-sectional, prospective study including non-diabetic dogs receiving prednisolone for >3 weeks for diverse immune-mediated diseases. Aliquots of blood samples collected for diagnostic purposes were used. HbA1c was measured using a validated capillary electrophoresis method (Sebia Capillarys 2 flex-piercing). Fructosamine was measured using the nitroblue tetrazolium assay.

Results

Twenty-seven dogs with a mean age of 7.2 (SD: 4.2) years were included. The dogs were receiving prednisolone (0.1-2.3 mg/kg SID) for 3-52 weeks (median: 6 weeks). Median glucose, fructosamine and HbA1c was 101 (76-259) mg/dL, 235 (142-389) $\mu\text{mol/L}$ and 1.4 (0.9-2.5)%, respectively. Nine (33.3%) and 4 (14.8%) dogs had high glucose (>110 mg/dL) and fructosamine (>310 $\mu\text{mol/L}$), respectively. All dogs had HbA1c within the RI (0.6-2.7%). HbA1c was significantly correlated with prednisolone dose of the preceding 2 weeks and average prednisolone dose of the preceding 4 weeks ($\rho=0.382$, $P=0.049$). Fructosamine was not significantly correlated ($P>0.05$) with prednisolone dose of the preceding 2 weeks and average prednisolone dose of the preceding 4 weeks. Neither HbA1c nor fructosamine was significantly correlated ($P>0.05$) with the duration of prednisolone administration.

Conclusion

HbA1c does not appear to be increased in sick, non-diabetic dogs receiving oral prednisolone for >3 weeks, whereas increases in serum fructosamine can be seen.

Oral Abstracts Clinical Pathology

SESSION 3: BIOCHEMISTRY

THURSDAY 31 AUGUST | 15.00-15.15

CAN WE USE OUR PATIENT DATABASE FOR ESTIMATING REFERENCE INTERVALS? CHALLENGES AND OPPORTUNITIES OF THE NEW “INDIRECT METHODS”

S. Manzocchi¹ and L. Van Rooyen²

¹Laboratory Analytical and Method Advisors, IDEXX, Novara, Italy and ²Laboratory Analytical and Method Advisors, IDEXX, Johannesburg, South Africa

Background

Population-based reference intervals (RIs) are fundamental for appropriate result interpretation. Current recommendations for their determination specify that a direct a priori approach, including at least 120 carefully selected subjects, is preferable. This is not always feasible due to logistical and cost constraints. Indirect approaches using retrospective “big data” are well known since the 1960s but failed to provide accurate RIs. Recently, several sophisticated algorithms for the indirect estimation of RIs have been proposed in human medicine and described as comparable with direct methods in many cases.

Objective

Preliminary evaluation of the utility and feasibility of novel indirect methods for determining RIs in the veterinary clinical laboratory.

Methods

Four biochemical measurands with different indices of individuality (Albumin, ALP, Chloride, Creatinine) were chosen. Unselected patient results (n=100000) from a clinical laboratory were used to calculate RIs by applying three novel statistical algorithms: truncated minimum chi-square, tidyKosmic, and RefineR. The reference limits obtained were then compared to those currently in use in the laboratory, determined through a direct approach.

Results

The three novel algorithms provided almost identical reference limits. The reference limits were very similar to those directly established and generally inside their 95% confidence intervals. One algorithm was challenged with artificial pathological values up to 50% of the population and consistently returned identical reference limits.

Conclusion

Novel statistical tools for indirect estimation of RIs appear as a promising opportunity with good potential for sex/age/breed stratification and they may represent a cost-effective option when direct approaches are not feasible.

Oral Abstracts Clinical Pathology

SESSION 3: BIOCHEMISTRY

THURSDAY 31 AUGUST | 15.15-15.30

EVALUATION OF A NOVEL APPROACH TO DETERMINE A REFERENCE INTERVAL OUT OF MIXED DATA SETS AND CALCULATION OF OPTIMIZED CUTOFFS FOR CANINE DGGR LIPASE

A. Pankraz¹.

¹*Biocontrol, Bioscientia Healthcare GmbH, Ingelheim, Germany*

Background

Laboratories possess large amounts of unused data, usually consisting of mixed data from diseased and healthy individuals. In contrast, conventional calculations of a reference interval (RI) require a rather small number of healthy animals to be used, which are not easily accessible for reference laboratories.

Objective

First, to use the Reference Limit Estimator (RLE) of the German Society for Clinical Chemistry and Laboratory Medicine (GSCCLM) to generate a new RI for canine serum DGGR lipase from existing laboratory data. Second, to compare this generated RI with the results of Spec CPL measurements to determine its sensitivity and specificity for detecting elevated or normal Spec CPL.

Methods

The results of 4064 canine DGGR lipase measurements were included in the calculation of the RI using the GSCCLM algorithm. Receiver Operating Characteristics (ROC) analyses were performed on the results of 2714 parallel DGGR lipase and Spec CPL measurements.

Results

The RI determined with the RLE for canine lipase was < 92 U/l. The ROC analysis revealed a sensitivity of 99% to detect a Spec CPL of <200 microgram/l for DGGR values <92 U/l. A cut-off for DGGR lipase of >260 U/l provided a 99% specificity to detect Spec CPL values of >400 microgram/l.

Conclusions

The RLE provided an RI comparable to that generated by conventional methods, providing a novel option to determine RI from mixed data sets. The ROC analysis generated cut-offs for DGGR lipase that provide excellent concordance with Spec CPL measurements, rendering this more expensive test unnecessary in some cases.

Oral Abstracts Clinical Pathology

SESSION 4: HEMATOLOGY

THURSDAY 31 AUGUST | 14.45-15.00

AGREEMENT BETWEEN NUCLEATED RED BLOOD CELLS INSTRUMENTAL COUNT USING SYSMEX XN-V AND MANUAL COUNTS AND POSSIBLE IMPACT ON THE DIAGNOSIS OF ANEMIA AND LEUKOPENIA

S. Paltrinieri¹, S. Meazzi¹, V. Martini¹, R. Ben Dov¹ and A. Giordano¹

¹*Dept of Veterinary Medicine and Animal Sciences, Lodi, Italy*

Background: Nucleated erythrocytes (nRBCs) are virtually absent in blood of healthy adult dogs but may be present (normoblastemia) in regenerative anemia, conditions altering the blood-bone marrow barrier or hypoxic diseases. Usually, cell counters do not differentiate nRBCs from WBCs. Therefore, nRBCs must be microscopically counted on blood smears, which is time-consuming, operator-dependent, and imprecise. Moreover, instruments overestimate WBCs in normoblastemic dogs and misclassify leukopenic patients. The laser-based cell counter Sysmex XN-V fluorescence flow cytometry analyser differentiates nRBCs from WBCs, but its accuracy to identify nRBCs in dogs has not extensively investigated.

Objective

To compare the accuracy of XN-V nRBCs/100 WBCs (nRBCs%) with microscopical counts in dogs with and without normoblastemia and to estimate the impact of the possible inaccuracy on anemic or leukopenic dogs.

Methods

The nRBC% determined by the Sysmex-XN and manually by three observers in 188 blood samples with different levels of normoblastemia were compared to each other. The agreement between manual and instrumental counts in classifying anemic or leukopenic patients was also assessed.

Results

Manual and instrumental nRBCs/100 WBC counts were highly correlated, but significantly different to each other, due to proportional errors, except for one observer. The agreement between instrumental and manual counts was good ($k=0.615$ to $k=0.669$) in detecting normoblastemia in anemic dogs, and almost perfect ($k>0.900$ for all the observers) in detecting leukopenic dogs.

Conclusion Sysmex XN-V nRBC% correlates well with manual counts, although the latter are imprecise and operator-dependent. The Sysmex XN-V is suitable for identification of normoblastemia and leukopenia in dogs.

Oral Abstracts Clinical Pathology

SESSION 4: HEMATOLOGY

THURSDAY 31 AUGUST | 15.00-15.15

ASSOCIATION BETWEEN LIPAEMIA, HAEMOLYSIS AND ICTERUS, AND DIFFERENCE BETWEEN MEAN CORPUSCULAR HAEMOGLOBIN CONCENTRATION (MCHC) AND MEAN CELLULAR HAEMOGLOBIN CONCENTRATION (CHCM) (Δ MCHC-CHCM) IN CANINE COMPLETE BLOOD COUNT ASSESSED WITH SIEMENS ADVIA 2120

M.G. Ferrari¹, S. Fasoli¹, K. Vasylyeva¹, M. Tumbarello¹, E. Brini¹, C. Agnoli¹ and F. Dondi¹

¹Dept. of Veterinary medical sciences, Alma Mater Studiorum-University of Bologna, Ozzano dell'Emilia, Bologna, Italy

Background

Increased discrepancy between MCHC and CHCM (Delta-MCHC-CHCM) can be related to pigmented plasma interference in haemoglobin measurement obtained by haematology analysers.

Objective

To evaluate prevalence and causes of increased Delta-MCHC-CHCM in dogs.

Methods

Retrospective study (2020-2022) including dogs with concurrent CBC (ADVIA 2120) and serum chemistry analyses. Delta-MCHC-CHCM reference interval (RI; -1.7-2.2) and 95% confidence interval (CI) of RI were calculated. Dogs with increased Delta-MCHC-CHCM (95%CI of upper limit RI) were selected. CBC, chemistry results (including triglyceride, cholesterol, total bilirubin and total protein) and sample colour changes related to lipaemia, haemolysis and icterus were recorded. Variables were compared between dogs with normal and increased Delta-MCHC-CHCM. Nonparametric statistics were performed (P<0.05 considered significant).

Results

10040 samples collected from 4049 dogs were selected; 1241/10040 (12%) were haemolytic, 960/10040 (9%) lipaemic, 320/10040 (3%) icteric, and 318/10040 (3%) were concomitantly lipaemic and haemolytic; other combinations were <0.3%. Delta-MCHC-CHCM \geq 2.5 (median 4.5, range 2.5-35.5) was recorded in 143/10040 (1.4%) samples from 113/4049 (2.8%) dogs. Among these samples, 95/143 (66%) were lipaemic, 67/143 (47%) haemolytic, 14/143 (10%) icteric, and 55/143 (39%) concomitantly lipaemic and haemolytic. Dogs with Delta-MCHC-CHCM \geq 2.5 had significantly increased frequency and severity of lipaemia, haemolysis, icterus, and combination of lipaemia and haemolysis (P<.01), if compared to other dogs. Delta-MCHC-CHCM correlated with lipaemia (r=0.17; P<0.01) and haemolysis (r=0.09; P<0.01) severity, triglyceride (r=0.10; P<0.01) and total protein (r=0.07; P<0.01) concentration.

Conclusion

A Delta-MCHC-CHCM increase in dogs is frequently associated with the presence of lipaemia and haemolysis and can be related to their severity.

Oral Abstracts Clinical Pathology

SESSION 4: HEMATOLOGY
THURSDAY 31 AUGUST | 15.15-15.30

DEFINITIVE RADIOTHERAPY IN DOGS WITH SOLID TUMORS ALTERS PERIPHERAL LYMPHOCYTES AND MONOCYTES

J. Lawrence^{1,2}, J. Coffey³, A. Morgan³, K. Demos-Davies¹, D. Seelig^{1,2}, A. Wolf-Ringwall^{1,2}, D. Vallera^{4,2}, S. Terezakis^{4,2}, L. Greenlund⁵ and L. Sloan^{4,2}

¹Department of Veterinary Clinical Sciences

²Masonic Cancer Center,

³Veterinary Medical Center, University of Minnesota, Saint Paul, United States

⁴Department of Radiation Oncology and ⁵Medical School, University of Minnesota, Minneapolis, United States

Background

Immune suppression following radiotherapy (RT) may be associated with poor outcomes in solid tumors. Stereotactic body RT (SBRT), an advanced technique that uses large doses per treatment, is considered less immunosuppressive than low-dose conventionally fractionated RT (cfRT). Decreased lymphocyte concentration occurs in dogs treated with cfRT, but the effects of cfRT compared to SBRT on lymphocyte and monocyte counts are unknown.

Objective

To compare lymphocyte and monocyte changes following cfRT or SBRT.

Methods

Complete blood counts were retrospectively reviewed for dogs with solid tumors treated with cfRT or SBRT between 2018-2022. Lymphocyte and monocyte concentrations were recorded from samples collected before RT, at the final treatment, and following RT. For cfRT-treated dogs, mid-treatment concentrations were also collected. Lymphocyte or monocyte concentrations over time were compared using mixed-model repeated measures with statistical significance set at $p < 0.05$.

Results

Lymphocyte concentration decreased ($p=0.001$) and monocyte concentration increased ($p=0.001$) secondary to RT in all dogs ($N=107$). For dogs treated with cfRT ($N=57$), lymphocyte concentration decreased mid-treatment ($p=0.024$) and at the final treatment ($p=0.001$); monocyte concentration increased following RT compared to both baseline ($p=0.047$) and mid-treatment ($p=0.016$). For dogs treated with SBRT ($N=50$), lymphocyte concentration did not significantly decrease with treatment; monocyte concentration increased following RT ($p=0.005$).

Conclusion

Contrary to cfRT, SBRT did not significantly reduce absolute lymphocyte concentration in dogs. Monocyte concentration increased following both cfRT and SBRT. Further studies should evaluate immune subsets within these populations to understand their potential impact on tumor control and response to combined RT and immunotherapy.

Acknowledgements: Support for this project was provided in part by the V Foundation for Cancer Research (DCORC2021-002).

Oral Abstracts Clinical Pathology

SESSION 5: CYTOLOGY

FRIDAY 1 SEPTEMBER | 08.45-09.00

PREDICTING CANINE CUTANEOUS MAST CELL TUMOR BEHAVIOR BY INTEGRATING CYTOLOGY AND STEREOLOGY

G. Azevedo¹, C. Lopes¹, M. Caniatti², C. Correia-Gomes³, R. Marcos¹ and M. Santos¹

¹Laboratory of Histology and Embryology, ICBAS, Porto, Portugal

²Dipartimento di Medicina Veterinaria e Scienze Animali (DIVAS), Università degli Studi di Milano, Milan, Italy

³Animal Health Ireland, Carrick-on-Shannon, Ireland

Background

Mast cell tumors (MCTs) are the most prevalent skin neoplasm in dogs and cytology is crucial for their diagnosis. Reliable cytological prognostic parameters would enable tailored pre-surgical therapeutical planning. Nuclear area (NA) is a quantitative, objective and highly reproducible morphological parameter that allows the establishment of well-defined cut-offs. The NA determined through stereological methods in cytological smears of MCTs has been associated with the histological grade, suggesting a potential prognostic value of this parameter.

Objective

Assessing the role of stereological methods in predicting MCT behavior by evaluating if NA estimated by 2D-nucleator in cytology smears is associated with survival.

Methods

A case series of 37 MCT with histologic confirmation and available clinical follow-up data was included in a retrospective survival study. The smears routinely stained with May Grunwald-Giemsa were destained and restained with hematoxylin-eosin (HE) to clearly outline the mast cells nuclei. The 2D-nucleator method was used to estimate NA in 100 cells per smear. Cox proportional hazards regression tests and Kaplan-Meier curves were used to perform the survival analysis.

Results

Short overall survival was correlated with an increase in the mean NA. The risk of MCT-related death increased by 1.07 for each increment of 1 m² in NA. The cut-off of 62.8 m² allowed the identification of cases with a worst clinical outcome.

Conclusion

In dogs with cutaneous MCTs, the NA estimated by stereological methods in HE-restained cytology smears is a prognostic factor. This parameter can assist in tailored therapeutic planning prior to surgery.

Oral Abstracts Clinical Pathology

SESSION 5: CYTOLOGY

FRIDAY 1 SEPTEMBER | 09.00-09.15

FLOW CYTOMETRY APPLICATION IN THE DETECTION OF NODAL METASTASIS IN DOGS WITH MAST CELL TUMOUR

G. Iamone¹, B. Miniscalco¹, C. Chalfon, L. Marconato², S. Sabbatini², M. Martano³, E. Morello¹, S. Iussich¹, E.I. Ferraris¹ and F. Riondato¹

¹Department of Veterinary Sciences, University of Turin, Grugliasco (TO), Italy

²Department of Veterinary Medical Sciences, University of Bologna, Ozzano dell'Emilia, Italy and

³Department of Veterinary Sciences, University of Parma, Parma, Italy

Background

In canine mast cell tumours (MCTs) the presence of nodal metastasis is a negative prognostic factor. Therefore, its detection is pivotal to drive clinical decisions. Flow cytometry (FC) is a less invasive and quicker tool compared to histology and can quantify mast cells in lymph nodes (LNs).

Objective

The aim of the study is to evaluate the association between Weishaar (histological) and Krick (cytological) grades of nodal infiltration and the reliability of FC to detect metastasis according to Weishaar classification.

Methods

Fifty-three dogs with MCT were enrolled. Samples for histology, cytology and FC analysis were collected. Histological and cytological slides were classified according to Weishaar (HN0-HN3), and Krick (normal/reactive, possible, probable, or certain metastasis), respectively. Mast cells were identified as CD117+ IgE+/- CD5- CD21- events by FC and reported as percentage.

Results

A significant association between histological and cytological grades was detected on 100 LNs. All probable and certain metastasis by Krick were HN2/HN3 by Weishaar, and all HN0 and HN1 by Weishaar were reactive/normal or possible metastasis by Krick. ROC curves performed on 109 LNs showed that a FC value >0.7% can detect the presence of metastasis (HN2-HN3) with a specificity of 98.4% and a sensitivity of 46.8%, and discriminate HN3 with specificity of 93.3% and sensitivity of 85%.

Conclusion

According to these results, the identification of probable or certain metastasis by cytology is predictive of a metastatic LN (HN2-3) by histology. In these cases, a FC mast cell percentage >0.7% is highly indicative of HN3.

Oral Abstracts Clinical Pathology

SESSION 5: CYTOLOGY

FRIDAY 1 SEPTEMBER | 09.15-09.30

CYTOLOGY OF AQUEOUS HUMOR IN CATS WITH UVEITIS

D. Legroux¹, C. Maringue² and E. Ramery¹

¹*VetAgro-Sup*

²*Ophvet, France*

Background

Although, in case of uveitis, aqueocentesis is routinely sent out by ophthalmologists for cytologic evaluation, scarce related-information is available in the literature. This is particularly true in cats where the association between uveitis and coronavirus is questioned.

Objective

To collect more data on aqueous humor cytology in cats with uveitis and investigate possible correlation with identified etiologies, especially coronavirus.

Methods

Twenty-three aqueous humor collected from 18 cats diagnosed with uveitis were analysed between February 2022 and April 2023. Results were compared with clinical presentation and additional results.

Results

Total nucleated cell counts (NCC) ranged from 1 to 8000 cells/uL. Six cats had NCC within usual values (<37 cells/uL). In these cases, mononuclear cells predominated. The highest cellularities (>780 cells/uL, 6 cases) were associated with predominance of neutrophils. Among those, 2 had degenerate neutrophils, one being associated with intracellular bacteria leading to a diagnosis of bacterial infection. Four out of 5 cats with increased NCC and lymphoplasmacytic infiltrate were PCR positive for coronavirus. Three cats with coronavirus had neutrophilic predominance. In one 7-months-old cat presented for apathy and fever, the large predominance of plasma cells (67%) initially led to an erroneous diagnosis of neoplasia (coronavirus PCR was negative). 2 weeks later serology was positive and aqueocentesis revealed a mixed infiltrate.

Conclusion These preliminary results suggest cytology of aqueous humor can be helpful in refining uveitis etiology in cats. Although neutrophils can predominate in coronavirus infection, lymphoplasmacytic infiltration is frequent and may lead in extreme cases to erroneous neoplasia diagnosis.

Oral Abstracts Clinical Pathology

SESSION 6: CYTOLOGY

FRIDAY 1 SEPTEMBER | 09.30-09.45

CEREBROSPINAL FLUID FINDINGS AND CENTRAL NERVOUS SYSTEM DISORDERS IN SMALL RUMINANTS – A RETROSPECTIVE STUDY IN SHEEP AND GOATS

Leandra C. Schöb^b, Christian Gerspach^a, Regina Hofmann-Lehmann^b, Barbara Riond^b

^a Clinic for ruminants, Department of farm animals, Vetsuisse Faculty, University of Zurich, Switzerland

^b Clinical Laboratory, Department for Clinical Diagnostics and Services, Vetsuisse Faculty, University of Zurich, Switzerland

Background

Small ruminants often suffer from central nervous system (CNS) disorders and cerebrospinal fluid (CSF) analysis can be used as a diagnostic tool. In small animals and cattle, specific CSF patterns have been defined for specific disease categories. No data exists for CSF results in small ruminants. **Objectives:** The objective of this study was to retrospectively investigate CSF findings in sheep and goats and to identify possible CSF patterns associated with disease categories.

Methods

CSF samples and medical records from 44 sheep and 27 goats were included in the study. All animals were presented to the University animal hospital of the Vetsuisse Faculty Zurich between 2003 and 2016. They had either a confirmed CNS diagnosis or showed CSF changes without a specific CNS diagnosis.

Results

Mixed mononuclear pleocytosis was the most common CSF pattern in sheep (27%), followed by monocytic pleocytosis (21%). Lymphocytic pleocytosis was most frequently found in goats (37%). In 80% of sheep and 63% of goats, infectious CNS diseases were diagnosed with listeriosis as the most common infectious disease in both species followed by parasitic disorders (Nematodiasis, Coenurosis).

Conclusions

Cytologic CSF patterns in small ruminants are mainly based on the increased presence of monocytic and lymphocytic cells with variable quantitative expression, whereas neutrophilic pleocytosis and cytoalbuminologic dissociation were rare findings. Infectious diseases of bacterial origin were the most common underlying causes for CSF alterations in sheep and goats, followed by parasitic disorders. However, the pleocytosis type is not helpful to definitely differentiate among disease types.

Oral Abstracts Clinical Pathology

SESSION 6: CYTOLOGY

FRIDAY 1 SEPTEMBER | 09.45-10.00

CYTOMORPHOLOGICAL ASSESSMENT OF CANINE INTERMEDIATE/LARGE CELL LYMPHOMA – A PROPOSED MODEL FOR PHENOTYPE PREDICTION: PRELIMINARY RESULTS

M. Neta¹, N. Pinto da Cunha^{2,3}, C. Piccinelli¹, A. Forlani¹ and I. Oikonomidis¹.

¹Clinical Pathology, IDEXX Laboratories LTD, Wetherby, United Kingdom ² Universidade Lusófona, Lisbon, Portugal ³VEDIS – Veterinary Expertise in Diagnosis, Porto, Portugal

Background

Immunophenotype of canine intermediate/large cell nodal lymphoma (CL) has a growing role in establishing of treatment plan, and its prediction can add value to cytology reports.

Objective

To assess a set of morphological features as potential predictors of phenotype in CL.

Methods

Sixty cytology cases of CL that had follow-up immunocytochemistry (ICC) were retrospectively reviewed by four boarded-certified pathologists, blinded to the ICC results. The cases were assessed for twelve morphological criteria. Agreement was reached by consensus or majority. Logistic regression analysis (LRA) was used to determine the effects of morphological criteria on prediction of immunophenotype using the statistical language R.

Results

Fifteen (25%) T cell and forty-five (75%) B cell CLs were reviewed. The final model of LRA included the following: heterogeneity of neoplastic population (HNP), prevalence and/or prominence of nucleoli (N), prominence of Golgi zone (GZ), cytoplasmic colour (CC), abundance of cytoplasmic fragments (CF) and number of tingible-body macrophages (TBM). N, CF and TBM were independent predictors of the immunophenotype (P=0.012, P=0.028 and P=0.041, respectively) with odds ratio (95% confidence interval) of 59.8 (4.3-3,322), 57.4 (2.6-4,587) and 3.0 (1.2-10.4), respectively. HNP yielded a P value of 0.054 and odds ratio of 21.0 (1.4-922). The accuracy of this model in predicting the immunophenotype was 93.3%.

Conclusion

TBM, N, CF and HNP were identified as independent predictors of immunophenotype in CL. Combined in a panel, these features achieved high accuracy for phenotype prediction. These results should be confirmed on a larger cohort before applied in a diagnostic setting.

Oral Abstracts Clinical Pathology

SESSION 6: CYTOLOGY

FRIDAY 1 SEPTEMBER | 10.00-10.15

IMMUNOHISTOCHEMICAL CLASSIFICATION OF THE FOÀ-KURLOFF CELL IN GUINEA PIGS

K. Weber¹ and R. Schoenauer²

¹AnaPath Services GmbH, Oberbuchsitzen, Switzerland

²AnaPath Services GmbH, Liestal, Switzerland

Background

Foà-Kurloff (FK) cells are leukocytes with cytoplasmic PAS-positive inclusion bodies and characteristics of lymphocytes and monocytes found in blood, bone marrow and other organs from guinea pigs and close relatives (family Caviidae) only. They are believed to represent natural killer cells (NK). Their function and origin are still poorly understood.

Objective

To understand the origin and function of FK cells.

Methods

In order to classify FK cells, immunohistochemistry was applied, using different CD markers (CD3, CD4, CD8, CD20, CD56), granzyme B and anti-estrogen-receptor beta; in guinea pig blood and bone marrow.

Results

FK cells showed a positive reaction with anti-CD4 and anti-CD8 antibodies but did neither express the pan-T-cell marker CD3 nor the NK cell marker CD56. The reactions with CD68 and CD20 were negative. Therefore, a macrophage nature or B-cell origin were excluded. In this study, FK cells expressed granzyme B in the cytoplasm and inside the inclusion, leading to the conclusion FK cells have a cytotoxic function. Finally, the cells reacted positively with anti-estrogen-receptor beta; in the cytoplasm that is deemed to be related to their higher presence in females.

Conclusion

FK cells are assumed to belong to a distinct lymphocyte subpopulation. The absence of CD3 does not allow classifying this cell type as a classical T-cell, rather a T-like cell. In contrast, CD4+/CD8+ cells are deemed to represent effector memory T-cells. It is therefore concluded that FK cells are memory cells with cytotoxic function.

Poster Abstracts Veterinary Pathology

ANIMAL MODELS

1 | EFFECT OF TESTOSTERONE AND TACROLIMUS ON NERVE REGENERATION PROCESS AFTER INJURY IN RAT: HISTOPATHOLOGIC EVALUATION

M. Jazinidorcheh*, **H. Fattahian***, **A. Aliaghaei†**, **M.A. Abdollahifar†**, **H. Azarabad‡**, **M. Ghanaatpishe§** and **H. Salehpour§**

**Department of Clinical Science, Science and Research Branch, Islamic Azad University, †Department of Biology and Anatomical Sciences, School of Medicine, Shahid Beheshti University of Medical Sciences and ‡Department of Pathology and §Department of Diagnostic Imaging, Hamidreza Fattahian Small Animal Hospital, Tehran, IR*

Introduction

Peripheral nerve injuries are common in animals. Corticosteroids, NSAIDs, hormones, growth factors, vitamins and immunosuppressives have been used to support nerve regeneration. We report a medical therapy to support healing of sciatic nerve injury in rat.

Materials and Methods

Groups of adult male rats (n=5) had the sciatic nerve crushed for 10 seconds and received 'testosterone' (Tes) or 'tacrolimus' (Tac) along or combined (Tes + Tac) at doses of 5 mg/kg for four weeks; five rats were sham treated. After euthanasia, nerve fibre size, axon diameter, myelin vacuolation, myelin thickness and inflammation were assessed in haematoxylin-eosin (HE), Masson's trichrome (MT), luxol fast blue (LFB) and GFAP stained sections.

Results

HE staining showed higher nerve fibre size, axon diameter and myelin thickness in the Tes + Tac group. In Tes + Tac group, MT staining revealed better vascularity of the endoneurial and epineurial compartments with regular blue-stained collagenous fibres. With LFB staining, the colour intensity was higher in Tes and Tes + Tac than the sham group. GFAP staining showed more GFAP-positive areas in Tac group than Tes + Tac group. The results of the Tes + Tac group were closer to the sham group and showed a significant difference or a slight difference with the other treated groups in some evaluations.

Conclusions

Healing of the crushed nerve was most advanced with Tes + Tac treatment for 28 days, suggesting that further studies are pursued for long term evaluation, application of different doses and testing in other animal models.

Poster Abstracts Veterinary Pathology

ANIMAL MODELS

17 | THREE-DIMENSIONAL QUALITATIVE AND QUANTITATIVE ANALYSIS OF MOUSE CORNEAL NERVE

M. Inanaga, E. Kaitani, A. Matsuda, T. Matsuura and K. Ozaki

Pharmacology, Setsunan university, Osaka, JP

Introduction

Corneal sensory nerves (CSNs) have attracted considerable interest as a potential site for the assessment of diabetic peripheral neuropathy. In rodent models of diabetes, CSNs are a possible inspection site for peripheral neuropathy. So far, analyses were limited to a two-dimensional method but there is now an increasing need for more accurate three-dimensional evaluations. Therefore, we established a method to elucidate the three-dimensional structure of the mouse corneal nerve and undertook quantitative analyses.

Materials and Methods

Male C57BL/6 mice aged 8 weeks were used. Corneal nerve fibres were visualized using a transparency technique and immunofluorescence. Wholemout images were acquired to construct three-dimensional images using confocal microscopy and analyzed with Imaris software. The density and total length of the nerve fibres running in all directions were then calculated.

Results

The subbasal nerve plexus (SBNP) branched from the bundles of nerve fibres in the corneal limbus stroma and formed whorl-like structures or vortices in the subbasal zone towards the corneal centre. The terminal epithelial nerves (TENs) branched from the SBNP and extended vertically to the epithelial surface in the central cornea, whereas in the peripheral cornea, they extended vertically to the epithelial surface and then ran parallel to it. The density of SBNP was higher in the centre than in the periphery. The density of TENs was also significantly higher in the centre, and their total length was greater compared to the periphery.

Conclusions

This study successfully captured the microstructure of mouse corneal nerve fibres and quantified the resulting three-dimensional images.

Poster Abstracts Veterinary Pathology

ANIMAL MODELS

22 | CHARACTERIZATION OF RENAL (DYS)FUNCTION IN RAT MODELS OF EARLY AND ADVANCED CHRONIC KIDNEY DISEASE

I. Lousa^{*†}, F. Reis^{‡§}, S. Viana^{‡§}, P. Vieira^{‡§}, H. Vala^{¶‡}, L. Belo^{*†} and A. Santos-Silva^{*†}

**Associate Laboratory i4HB - Institute for Health and Bioeconomy, Faculty of Pharmacy, University of Porto, 4050-313 Porto, †UCIBIO-Applied Molecular Biosciences Unit, Laboratory of Biochemistry, Department of Biological Sciences, Faculty of Pharmacy, University of Porto, 4050-313 Porto, ‡University of Coimbra, Institute of Pharmacology & Experimental Therapeutics, & Coimbra Institute for Clinical and Biomedical Research (iCIBR), Faculty of Medicine, 3000-548 Coimbra, §University of Coimbra, Center for Innovative Biomedicine and Biotechnology (CIBB), 3004-504 Coimbra, ¶Centre for the Research and Technology of Agro-Environmental and Biological Sciences (CITAB), Universidade de Trás-os-Montes e Alto Douro, 5001-801 Vila Real and *CERNAS, Escola Superior Agrária de Viseu, Instituto Politécnico de Viseu, Campus Politécnico, 3504-510 Viseu, PT*

Introduction

Despite its limitations, serum creatinine remains the most widely used test to estimate renal function, while microalbuminuria adds additional information on renal damage. The diagnostic utility of beta-trace protein (BTP), a novel biomarker of kidney function, has not been characterized in animal models. This study aimed to determine serum and urine patterns of renal markers alongside the occurrence of renal lesions in rat models of early and advanced chronic kidney disease (CKD) induced by nephrectomy.

Materials and Methods

Early and advanced CKD was induced in rats by the complete removal of one kidney or two-step 5/6 nephrectomy, respectively; a control group was included. Serum and urine were collected to assess the levels of several renal function biomarkers and study their association with the presence of several glomerular and tubulointerstitial lesions.

Results

The early CKD group presented a significant increase in total mild glomerular lesions, without significant changes in the studied biomarkers, as compared to control group. In advanced CKD we found a significant increase in both glomerular and tubulointerstitial lesions, alongside with creatinine, BTP and albuminuria, but not proteinuria. Overall, albuminuria and proteinuria correlated with the severity of glomerular lesions, while creatinine and BTP correlated with glomerular and tubular lesions.

Conclusions

Histological changes in the early-stage CKD group are not accompanied by significant variations in traditional renal function markers, neither BTP. In advanced CKD, serum creatinine and BTP seem to reflect the histopathological changes observed with disease progression. The combined use of creatinine and BTP might improve disease staging.

Acknowledgements: This work was financially supported by CITAB UIDB/04033/2020 and CERNAS UIDB/00681/2020; national funds from FCT & MCTES from UCIBIO (UIDP/04378/2020 and UIDB/04378/2020) and from the project LA/P/0140/2020 of i4HB; by FEDER COMPETE2020 funds UIDP/04539/2020 (CIBB) and POCI-01-0145-FEDER-007440; FCT doctoral grant SFRH/BD/145939/2019; funds from Portugal Regional Coordination and Development Commissions (Norte-01-0145-FEDER-000024; Centro-01-0145-FEDER-000012).

Poster Abstracts Veterinary Pathology

ANIMAL MODELS

40 | A NEW WILD TYPE MOUSE MODEL PAVES THE WAY FOR THE STUDY OF USUTU VIRUS PATHOGENICITY IN MAMMALS

M. Gérardy, F. Rivas, A. Blanquer and M. Garigliany

Veterinary Pathology, University of Liege, Faculty of Veterinary Medicine, Liège (Sart Tilman), BE

Introduction

Usutu virus (USUV) is an emerging mosquito-borne Flavivirus closely related to West Nile Virus. Originating from Africa, both viruses are currently spreading all over Europe, causing seasonal episodes of mass mortalities in birds and sporadic neurological diseases in mammals. The host-pathogen factors leading to these events remain unknown, and the increasing number of cases diagnosed in Europe represents a serious threat for public health. Thus, there is need for relevant models to study USUV pathogenicity in mammals. The most commonly used mammalian models are immunocompromised mice. We have recently developed a wild-type (WT) model based on the age-dependent susceptibility of mice to USUV infection, using older but genetically identical pups as controls. To identify the main host-pathogen interactions responsible for the observed difference in outcome of infection, we compared viral dissemination and immune response in the two groups of mice over time.

Materials and Methods

Susceptible (9 day-old) and resistant (15 day-old) 129/Sv WT pups received a peripheral injection of USUV, and a kinetic examination of the viral dissemination and the host's response was conducted, using RT-qPCR and flow cytometry.

Results

While no consequence of the viral inoculation was found in resistant mice, the susceptible group suffered a neurotropic infection and displayed severe changes in the brain (extensive neuronal apoptosis and necrosis, satellitosis, neuronophagia and perivascular lymphoplasmacytic cuffs) and evident viral antigen expression in neurons..

Conclusions

Qualitative and quantitative differences in the host's response appear to determine the outcome very early after infection.

Poster Abstracts Veterinary Pathology

ANIMAL MODELS

48 | ACCELERATION OF AGE-ASSOCIATED CHANGES AND DECREASED SURVIVAL IN OLD MICE BY DELETION OF THE GENE FLOWER

T. Carvalho*, **M. Bettencourt†** and **E. Moreno†**

**Histopathology Platform and †Cell Fitness Lab, Champalimaud Foundation, Lisbon, PT*

Introduction

Flower plays a crucial role in regulating various physiological processes, including cell growth, development, and survival. Previous research has linked Flower dysfunction to neurodegenerative disorders in drosophila and cancer in mice. This study investigated the impact of Flower gene deletion on lifespan and disease spectrum in mice.

Materials and Methods

89 female mice were included in the study: 29 wild type (WT), 26 Flower heterozygous (HET), and 34 Flower knockout (KO). Animals were continuously monitored and euthanized when death was imminent. Weight and clinical signs were recorded. Postmortem examination was performed, with systematic analysis of all major organs and tissues. Cause of death was determined by integrating clinical, gross, and histopathological data. When a single fatal lesion was absent, the combined effect of multiple comorbidities was considered as a significant factor leading to clinical deterioration and death.

Results

Flower KO mice exhibited significantly lower survival rates compared to WT and HET mice. They exhibited a spectrum of age-associated diseases: malignant neoplasms, hyperplastic lesions, degenerative changes, chronic inflammation, commonly observed in normal aging mice. Haematopoietic neoplasms were the most frequent lesions across all genotypes. Proliferative non-neoplastic lesions, degenerative changes (cardiomyopathy, nephropathy), and chronic inflammation were seen in all genotypes. The most frequent cause of death was haematopoietic neoplasia, followed by comorbidities.

Conclusions

Deletion of Flower is associated with accelerated aging and reduced lifespan, without genotype specific lesions. These findings shed light on the underlying mechanisms of aging and provide valuable insights into the role of Flower in disease.

Poster Abstracts Veterinary Pathology

ANIMAL MODELS

66 | INSIGHTS INTO THE PATHOGENESIS OF PERIPHERAL NERVE LESIONS IN A MODIFIED VIRUS-INDUCED ANIMAL MODEL OF MULTIPLE SCLEROSIS

E. Leitzen*, **W. Jin***, **K.M. Gregor***, **W. Baumgärtner*†** and **F. Hansmann***

**Department of Pathology and †Center for Systems Neuroscience, University of Veterinary Medicine, Hannover, DE*

Introduction

Viral infections induce devastating diseases in the peripheral (PNS) and central nervous system (CNS) of humans and animals. Several demyelinating diseases, like multiple sclerosis (MS) or Guillain-Barré syndrome (GBS) are linked to antecedent infections. Theiler's murine encephalomyelitis virus (TMEV) represents a well-established animal model for MS. Intraplinal TMEV infection has been shown to induce peripheral nerve damage. Knowledge on the nature of TMEV-induced PNS lesions is scarce. This study provides a more detailed characterization of peripheral nerve lesions (PNL).

Materials and Methods

Groups of 4-8 young-adult female C57BL/6 (B6) and SJL mice were inoculated intraplinally with the BeAn strain of TMEV or vehicle. Necropsies were performed at 14, 28 (B6) or 28, 63 (SJL) days post inoculation (dpi). PNL were investigated using immunofluorescence staining targeting TMEV, Schwann cells, axons, macrophages and cells of NG2 lineage. Toluidine-blue stained semi-thin sections were morphometrically analyzed and ultrastructural analysis of nerve tissue was performed.

Results

PNL comprised reduced fibre density but increased myelin thickness in infected animals. Ultrastructural changes included vacuolation of myelin sheaths, axons with intracytoplasmic electron dense structures, and macrophages with intracytoplasmic myelin debris. Immunofluorescence staining indicated co-localization of TMEV with axonal and myelin damage and macrophages but no co-localization with NG2 cells.

Conclusions

Within PNL, TMEV capsid protein was detected in macrophages and in close proximity to axonal and myelin damage. These results provide new insights into cell tropism of TMEV in the PNS and show for the first time a direct link between lesion development and virus localization.

Poster Abstracts Veterinary Pathology

ANIMAL MODELS

67 | DCIR EXPRESSION ON DENDRITIC CELLS DECELERATES EARLY T CELL ACTIVATION IN A MURINE MIXED BONE MARROW CHIMERA MODEL OF NEUROTROPIC VIRUS INFECTIONS

M. Stoff^{*}, T. Ebbecke[†], A. Glasenapp[‡], S. Pavasutthipaisit^{*}, M. Ciurkiewicz^{*}, C. Kinder^{*}, M. Bankstahl[‡], B. Lepenies[†] and A. Beineke^{*}

^{}Department of Pathology and [†]Research Center for Emerging Infections and Zoonoses, Immunology Unit, University of Veterinary Medicine Hannover and [‡]Institute for Laboratory Animal Science and Central Animal Facility, Hannover Medical School, Hannover, DE*

Introduction

The pattern recognition receptor Dendritic cell immunoreceptor (DCIR) is a myeloid C-type lectin receptor that is expressed on antigen-presenting cells, e.g. dendritic cells (DCs), and promotes ambivalent functions depending on the initial trigger. During acute Theiler's murine encephalomyelitis (TME) DCIR expression inhibits antiviral immunity contributing to virus- and immunity-related detrimental neuropathological changes. Here, mixed bone marrow chimeras were utilised to gain insight into DC-specific DCIR expression related effects on antiviral immune responses and neuropathological processes upon TMEV infection in vivo.

Materials and Methods

Mixed bone marrow chimeras were generated by sublethal irradiation of C57BL/6 wildtype mice (WT) receiving bone marrow cells from DCIR^{-/-} and CD11c-diphtheria toxin receptor (DTR)-transgenic donor mice. Selective depletion of DTR-expressing DCIR⁺CD11c⁺DCs was achieved by diphtheria toxin (DT) applications. Mice were TMEV-infected intracerebrally 6 weeks post irradiation and sacrificed 3, 7 and 14 days post infection (dpi). Flow cytometry of blood and spleen was performed. Brains were analyzed by histology and immunohistochemistry.

Results

Chimera exhibiting a complete lack of DCIR (DCIR^{-/-} > WT) or specific knockout of DCIR on DCs (DCIR^{-/-}/CD11c-DTR > WT+DT) showed significantly higher numbers of activated CD8⁺CD69⁺ splenic T cells compared to mice with partial unmodified DCIR expression (DCIR^{-/-}/CD11c-DTR > WT) at 3 dpi. The same groups (DCIR^{-/-} > WT & DCIR^{-/-}/CD11c-DTR > WT+DT) also exhibited a tendency toward diminished hippocampal damage at 7dpi.

Conclusions

The results indicate that DC-specific expression of DCIR promotes the inhibitory impact on antiviral immunity upon TMEV infection affecting peripheral T cell activation and cerebral integrity.

Poster Abstracts Veterinary Pathology

ANIMAL MODELS

69 | OLFACTORY AND RESPIRATORY EPITHELIAL IMPAIRMENT AND RECOVERY AFTER VANADIUM EXPOSURE IN RATS

M. Pereira*, **M.S. Alves Pimenta*†**, **C. Venancio***, **B. Colaço†‡** and **M.L. Pinto†‡**

**Centre for the Research and Technology of Agro-Environmental and Biological Sciences (CITAB), †Animal and Veterinary Research Centre and ‡Associate Laboratory for Animal and Veterinary Sciences (AL4Animals), University of Trás-os-Montes and Alto Douro, Vila Real, PT*

Introduction

Evidence suggests that environmental pollutants' fine particles are major risk factors for respiratory disorders. Vanadium, a metal component that induces metabolic changes in the respiratory system, is often present in these pollutants. This study determined the (sub)acute effects of vanadium exposure in the nasal respiratory (RE) and olfactory epithelium (OE).

Materials and Methods

Forty-two adult Wistar rats were divided in six groups. Four groups were exposed to a solution of vanadium pentoxide (V₂O₅) by intranasal delivery three times a week for 4 weeks; each two groups were exposed to V₂O₅ at a concentration of 273 µg and 182 µg, respectively, in 30 µL of distilled water, two groups served as controls. Individuals from each one 273 µg and 182 µg and one control group were sacrificed after 4 weeks of exposure, the remaining two concentration and control groups four weeks after the last V₂O₅ administration. Full necropsy was performed, and the heads were processed for routine paraffin embedding and histopathological evaluation.

Results

Exposure to higher doses of vanadium resulted in coagulative necrosis of OE cells, with the exception of few basal cells. The RE showed minor changes, limited to focal necrosis. Four weeks after exposure, the OE was partially restored, but single cell necrosis, vacuolization of sustentacular cells and histiocytes were still observed. The RE had fully recovered.

Conclusions

The results indicate that despite the severity of short-term effects, the OE maintains the ability to self-regenerate, and the RE fully recovers rapidly after intranasal vanadium exposure.

Acknowledgements: This work is supported by National Funds by FCT - Portuguese Foundation for Science and Technology, under the projects UIDB/04033/2020, UIDP/CVT/00772/2020, LA/P/0059/2020, Scientific Employment Stimulus—Institutional Call—CEEC-INST/00127/2018UTAD, and by research grant 2020.06947.BD.

Poster Abstracts Veterinary Pathology

ANIMAL MODELS

70 | CAUSES AND INCIDENCE OF FAILURE TO LITTER IN CONTROL RATS FROM EXTENDED ONE-GENERATION REPRODUCTIVE TOXICITY STUDIES

O. Greville-Heygate*, **P. Edwards***, **S. Renault†**, **P. Scott†** and **M. Levi***

**Labcorp Early Development Laboratories Limited, Huntingdon, GB and †Labcorp Early Development Laboratories Limited, Eye, GB*

Introduction

The Extended One-Generation Reproductive Toxicity Study (OECD 2018, Test No. 443) tests for effects of pre- and post-natal chemical exposure. Failure to litter (FL) is defined as successful mating with no offspring produced. The pathologist must interpret treatment relatedness of FL. We retrospectively analysed the incidence and causes of FL in control rats to aid interpretation.

Materials and Methods

Forty-two OECD 443 studies conducted between 2018 and 2022 at Labcorp Early Development Laboratories Limited, Huntingdon/Eye, UK, were examined. They included 30 oral gavage and 12 dietary studies, with Sprague Dawley® (SD) and RccHan®:WIST (HW) rats in 30 and 12 studies, respectively.

Results

FL animals were observed in 24/42 (57.1%) studies, showing no association with dosing procedure. The total incidence of FL was 42/1030 (4.1%), with a higher incidence in the HW [16/299 (5.3%)] than SD [26/731 (3.6%)] strain. Male infertility accounted for 13/42 (31%) of cases and was associated with tubular degeneration/atrophy of the testes [11/42 (26.2%)] and with low progressive sperm motility [2/42 (4.8%)]. Post-implantation loss of embryos/foetuses occurred in 5/42 (12%) females. Pyo/hydrometra was seen in 3/42 (7.1%) cases. Findings with uncertain significance included females acyclic prior to mating [2/42], pseudopregnancy [2/42], luteal cysts [1/42] and epididymal adipose necrosis [1/42]. There were no findings related to FL in 15/42 (35.7%) cases.

Conclusions

Tubular degeneration/atrophy and sperm abnormalities accounted for most of FL in control pairs. Several cases of FL were due to post-implantation loss. The cause of FL could not be identified in half of the cases.

Poster Abstracts Veterinary Pathology

ANIMAL MODELS

71 | EFFECTS OF VANADIUM IN THE CNS AT DIFFERENT TIME POINTS-PRELIMINARY RESULTS IN RATS

M. Pereira*, **A. Fernandes***, **C. Venancio***, **M.S. Alves Pimenta*†**, **B. Colaço†‡** and **M.L. Pinto†‡**

*Centre for the Research and Technology of Agro-Environmental and Biological Sciences (CITAB), #University of Trás-os-Montes and Alto Douro, Vila Real, PT,

†Animal and Veterinary Research Centre and ‡Associate Laboratory for Animal and Veterinary Sciences (AL4Animals), University of Trás-os-Montes and Alto Douro, Vila Real, PT

Introduction

Epidemiological data suggests that environmental vanadium has a direct impact on health and could be implicated in the aetiopathogenesis of neurodegenerative diseases, but time and dose-response relationships with CNS disorders are largely unknown. The aim of this study was to determine the effects of different doses of vanadium in the CNS at different time-points.

Materials and Methods

Forty two adult Wistar rats were used in this study, divided in six groups. Four groups were exposed to a solution of vanadium pentoxide (V_2O_5) by intranasal delivery three times a week for 4 weeks, in which two concentrations, two groups for each concentration of 273 μg and 182 μg of V_2O_5 in 30 μL of distilled water were tested, and two control groups. Individuals from one 273 μg and 182 μg concentration group and one control were sacrificed after 4 weeks of exposure, the remaining two concentration and control groups four weeks after the last V_2O_5 administration. Full necropsy was performed, and the brains processed for routine paraffin histopathological evaluation.

Results

Vanadium exposure resulted in gliosis and neuronal death, particularly in the olfactory bulb and hippocampus. Myelin basic protein expression was not compromised, but tyrosine hydroxylase expression in the olfactory bulb was decreased immediately and four weeks after exposure.

Conclusions

Vanadium has a negative impact in the CNS and its effects persist four weeks after exposure.

Acknowledgements: This work is supported by National Funds by FCT - Portuguese Foundation for Science and Technology, under the projects UIDB/04033/2020, UIDP/CVT/00772/2020, LA/P/0059/2020, Scientific Employment Stimulus—Institutional Call—CEEC-INST/00127/2018UTAD, and by research grant 2020.06947.BD.

Poster Abstracts Veterinary Pathology

ANIMAL MODELS

73 | KETAMINE ADMINISTRATION AT THE 1-4 SOMITES STAGE ZEBRAFISH DOES NOT ALTER THE DISTRIBUTION PATTERN OF SEROTONIN 5-HT-2B RECEPTORS IN ADULT ANIMALS

C. Santos^{*}, L. Félix[†], A.M. Valentim^{‡,§}, L. Antunes[†] and M.L. Pinto^{¶,‡}

^{}Centro de Investigação Vasco da Gama (CIVG), Escola Universitária Vasco da Gama, Coimbra, PT, [†]Centro de Investigação e de Tecnologias Agroambientais e Biológicas (CITAB), [‡]Instituto de Investigação e Inovação em Saúde (i3S) and [§]Instituto de Biologia Molecular e Celular (IBMC), Universidade do Porto, Porto, PT, [¶]Centro de Ciência Animal e Veterinária (CECAV) and [‡]AL4Animals Laboratório Associado, Universidade de University of Trás-os-Montes and Alto Douro, Vila Real, PT*

Introduction

Ketamine is a dissociative anaesthetic, which also exerts antidepressant effects, especially by acting on serotonin receptors. The 5-HT-2B serotonin receptor is known for its distribution in human brain, gut, and heart. This receptor is described to have important roles in the peripheral and central nervous system (CNS) being a therapeutic target of antidepressant effects and required for the action of selective serotonin antidepressants. Zebrafish is a widely used model in research, namely in antidepressant and toxicological studies, and an ortholog to mammalian 5-HT-2B receptors is present in zebrafish. Nonetheless, their precise distribution in the zebrafish CNS is still poorly identified. The aim of this study was to determine the distribution patterns of 5-HT-2B in the CNS of larvae and adult zebrafish, following ketamine exposure.

Materials and Methods

Zebrafish embryos at the 1-4 somites stage were randomly distributed into groups: control and ketamine exposure at 0.2 and 0.8 mg/mL. Animals grew until 144 hours postfertilization and 7 months. Then, brains were embedded in paraffin, and 5-HT-2B expression was assessed by immunohistochemistry.

Results

5-HT-2B expression was only seen in the CNS of adult zebrafish: olfactory bulb, optic tectum, torus longitudinal, medulla oblonga, vagal lobe, and in the pituitary and thyroid glands, with no apparent differences between groups.

Conclusions

The study revealed widespread expression of 5-HT-2B in the adult zebrafish CNS regardless of ketamine exposure. As in humans, zebrafish serotonin seems to be involved in the hypothalamo-pituitary-thyroid axis activity, as 5-HT-2B receptors were found in the pituitary and thyroid glands.

Acknowledgements: This work was funded by FEDER through the Operational Competitiveness Programme-COMPETE and by National Funds through FCT-Fundação para a Ciência e a Tecnologia under the project FCOMP-01-0124-FEDER-028683 (PTDC/CVT-WEL/4672/2012).

This work was supported by the projects UIDB/00772/2020 and LA/P/0059/2020 funded by the Portuguese Foundation for Science and Technology (FCT).

Poster Abstracts Veterinary Pathology

ANIMAL MODELS

76 | PATHOGENESIS OF INTRANASAL INOCULATION OF RIFT VALLEY FEVER VIRUS IN THE FERRET

A.L. Schlachter*, **K.L. Mansfield†**, **M. Schilling†**, **A. Nunez***, **F.Z. Lean‡**, **I. Garcia§** and **N. Johnson†**

**Pathology and Animal Sciences and †Virology, Animal Plant and Health Agency, Addlestone, GB, ‡Pathobiology and Population Sciences, Royal Veterinary College, North Mymms, GB and §Pathology, University of Cordoba, Cordoba, ES*

Introduction

Rift Valley fever virus (RVFV) is an emerging zoonotic arbovirus which can manifest as haemorrhagic fever, encephalitis, and ophthalmitis in humans. The ferret (*Mustela putorius furo*) has recently been proposed as a new animal model for studying human RVFV infections. In this study the neuropathogenesis, viral tropism and progression of RVFV infection is investigated in ferrets through intranasal inoculation with RVFV.

Materials and Methods

A group of 15 ferrets were inoculated intranasally with a high dose of RVFV (strain ZH501) then clinically monitored over the course of the study. Serial blood samples and swabs were taken for virological and serological analyses. Three ferrets were euthanised at 3 days post infection (DPI), and the remainder upon reaching clinical end points. Tissues collected were evaluated by histopathology and for RVFV-specific immunohistochemistry (IHC).

Results

Infected ferrets showed a range of neurological signs, with 100% mortality by 8 DPI. Grossly, mild to moderate hyperaemia of the meninges was identified in all infected ferrets. Histopathology revealed a non-suppurative meningoencephalitis and myelitis with prominent perivascular cuffing, progressing in a rostral to caudal direction. Virus was detected by IHC in the nasal cavity before dissemination to the brain and into the spinal cord.

Conclusions

Intranasal inoculation of RVFV in the ferret results in rapid infection of the brain via the cranial nerves with caudal extension into the spinal cord, resulting in neurological disease and mortality. This animal model represents a novel platform to further understand disease pathogenesis and assess countermeasure strategies.

Poster Abstracts Veterinary Pathology

ANIMAL MODELS

103 | TREG-ABLATED FOXP3DTR MICE ARE A MODEL OF INFLAMMATORY MYOPATHY AND AUTOIMMUNE MYOCARDITIS

F. Prisco*, **S. Da Costa Pereira†**, **B. Becher†** and **A. Kipar***

**Laboratory for Animal Model Pathology, Institute of Veterinary Pathology and †Institute of Experimental Immunology, University of Zurich, Zurich, CH*

Introduction

Inflammatory myopathy (IM) stands for a heterogeneous group of acquired immune-mediated disorders in which the skeletal muscle is targeted by the immune system. Since self-reactive T cells play a central role in IM we hypothesised that inhibition of their suppression by regulatory T (Treg) cells could trigger IM. The aim of the project was to establish a mouse model of IM that results from specific loss of Treg cell activity in suppressing self-reactive T cells.

Materials and Methods

Adult Foxp3DTR and C57BL mice were intraperitoneally injected with diphtheria toxin every 2 days within up to 18 days, then sacrificed. A defined set of skeletal muscles and the heart were sampled and processed for histology. Consecutive sections were stained with HE and by immunohistochemistry for T cell subsets, B cells and macrophages, followed by a morphometric analysis.

Results

In the Foxp3DTR mice, all examined muscles exhibited moderate multifocal endomysial, perimysial and often perivascular mononuclear infiltrates with myonecrosis and myophagocytosis. The infiltrates also arranged around and occasionally invaded unaltered muscle fibres. A concurrent mild mononuclear endomyocarditis was also observed. The inflammatory infiltrates were comprised of T cells (mainly CD8+) and macrophages, with rare B cells. No inflammatory processes were observed in the control animals.

Conclusions

The findings are consistent with immune-mediated polymyositis and myocarditis and most likely result from activation of self-reactive T cells. Since this model results from the ablation of Treg cells, it might be useful to study the role of Treg in the breakdown of tolerance underlying IM.

Poster Abstracts Veterinary Pathology

ANIMAL MODELS

106 | **SIGNALLING OF THE C-TYPE LECTIN RECEPTOR CLEC12A RESTRAINS PROTECTIVE IMMUNITY DURING ACUTE THEILER'S MURINE ENCEPHALOMYELITIS VIRUS INFECTION**

M.K. Ameen*, **M. Stoff***, **S. Pavasutthipaisit***, **T. Markus Ebbecke†**, **M. Ciurkiewicz***, **T. Störk‡**, **B. Lepenies§** and **A. Beineke‡**

**Department of Pathology and †Department of Immunology, ‡Department of Pathology, University of Veterinary Medicine, Hannover, DE and §Department of Immunology, University of Veterinary Medicine, Hanover, DE*

Introduction

Theiler's murine encephalomyelitis virus (TMEV) is an enteric pathogen of rodents belonging to the family Picornaviridae. Intracerebral TMEV infection represents a reliable model to study virus-induced hippocampal damage and seizure development. C-type lectin domain family 12 member A (CLEC12A) is an inhibitory C-type lectin receptor which negatively regulates the functions of innate immune cells but its role in neurotropic viral infection has not yet been determined. The current study aimed at characterizing the effect of CLEC12A upon antiviral immunity and virus-mediated neuropathological processes in a knockout mouse model.

Materials and Methods

C57BL/6 mice (WT) and CLEC12A^{-/-} mice were intracerebrally inoculated with TMEV and euthanized at 3, 7 and 14 dpi. Neuroinflammation, hippocampal integrity and the presence of virus were determined by histology and immunohistochemistry. In addition, peripheral immune responses were determined by flow cytometry.

Results

Histological and immunohistochemical analyses revealed increased inflammatory responses and enhanced CD3⁺ T cell infiltration in the hippocampus of infected CLEC12A^{-/-} mice at 3 dpi. Significantly reduced numbers of TMEV-infected cells and GFAP⁺ astrocytes were observed in the hippocampus of CLEC12A^{-/-} mice at 7 dpi. No differences were found between CLEC12A^{-/-} mice and WT mice regarding the number of NeuN⁺ hippocampal neurons as well as of brain-infiltrating CD45⁺ B cells and CD107b⁺ macrophages/microglia. Flow cytometric analyses of spleens showed increased frequencies of CD4⁺CD69⁺ T cells in CLEC12A^{-/-} mice at 3 dpi.

Conclusions

CLEC12A deficiency supports antiviral immune mechanisms by enhanced neuroinflammation and T cell activation, leading to rapid virus clearance upon acute neurotropic virus infection.

Acknowledgements: The study is supported by the Deutsche Forschungsgemeinschaft (DFG, German Research Foundation)-BE4200/4-3 and 398066876/GRK 2485/1-VIPER-GRK. Muhammad Kamran Ameen received grants from DAAD/HEC, Pakistan.

Poster Abstracts Veterinary Pathology

ANIMAL MODELS

109 | CHARACTERIZATION OF DORSAL ROOT GANGLIA OF GOLDEN SYRIAN HAMSTERS (*MESOCRICETUS AURATUS*) IN A PHYSIOLOGICAL AND POTENTIAL PATHOLOGICAL STATE

I. Zdora, L. Heydemann, F. Armando, M. Ciurkiewicz, E. Leitzen and W. Baumgärtner

Pathology, University of Veterinary Medicine, Hannover, Hannover, DE

Introduction

Dorsal root ganglia (DRG) harbour neurons transmitting somatosensory signals from the periphery to the CNS. Satellite glial cells (SGCs) tightly envelope these neurons and thereby regulate and maintain a stable environment. As a response to injurious processes, SGCs particularly display signs of activation and dedifferentiation and influence neuronal excitability and sensory signalling. Recently, sensory abnormalities with detectable molecular changes in DRG have been reported in SARS-CoV-2 infected hamsters. However, knowledge about the cellular composition, protein expression profile and potential changes under pathological conditions of DRG in hamsters is scarce. The aim of the present study was a thorough phenotypical characterization of DRG in non-infected and SARS-CoV-2 infected hamsters.

Materials and Methods

DRG of SARS-CoV-2 and mock-infected hamsters were collected, formalin-fixed and paraffin embedded followed by histomorphological and immunohistological examination. Antibodies against glutamine synthetase (GS), potassium channel Kir4.1 and glial fibrillary acidic protein (GFAP) as well as markers targeting immune cells and the SARS-CoV-2 nucleocapsid protein (NP) were applied.

Results

Hamster DRG show a similar composition compared to other species. Several SGCs surround each neuronal soma. SGCs of infected and non-infected animals stained positive for GS, Kir4.1 and GFAP, and few inflammatory cells were detectable in DRG of both groups. No SARS-CoV-2 NP was detectable.

Conclusions

DRG from infected and non-infected hamsters have not shown discernible differences in the expression of markers examined to date. Whether other phenotypic changes can be observed in DRG as a response to SARS-CoV-2 infection with potential effects on the somatosensory behaviour requires further investigation.

Acknowledgements: This project was supported by the COVID-19 Research Network of the State of Lower Saxony (COFONI) with funding from the ministry of science and culture of Lower Saxony, Germany (14-76403-184)

Poster Abstracts Veterinary Pathology

ANIMAL MODELS

111 | UNEXPECTED HISTOPATHOLOGICAL FINDINGS IN SELECTED PRE-CLINICAL MEDICAL DEVICE STUDIES

P. Ortega, K. Weber, R. de Miguel, K. Kegler, A. Liens, R. Vallejo, O. Richard and N. Warfving

AnaPath Services GmbH, CH

Introduction

Medical devices have become indispensable for health care, increasing the demand for novel methodologies, technologies, and biomaterials. These new therapeutic applications and biomaterials are often associated with novel, unexpected or unpublished histological findings that challenge their interpretation. This work aimed to summarize some relevant and unusual microscopic findings of selected non-clinical medical device studies arising from novel applications and biomaterials, and their degradation products.

Materials and Methods

Three non-clinical medical device studies were selected for presenting unforeseen histology findings further characterized using special technologies as Energy-dispersive X-ray spectroscopy (EDX) and Scanning Electron Microscope (SEM).

Results

In a stented porcine iliac artery model, brown pigment compatible with haemosiderin was found in the tunica intima. Further EDX analysis characterized it as rare earth elements from the degradable alloy. In a subcutaneous rabbit study with an implanted magnesium device, item degradation led to the formation of a gas void which appeared histologically as optical empty space. Microscopic morphological changes of the implant together with EDX analysis allowed the traceability of the magnesium degradation components. In a bone implantation sheep study, the lumen of the item pores presented particles/debris which suggested possible fragmentation of the implant. SEM analysis characterized these particles as artifactual related to the thickness and plane orientation of the slide, confirming the integrity of the implant.

Conclusions

These selected cases emphasize the need for careful interpretation in medical device studies and the usefulness of special technologies to ensure the accurate assessment of their safety and efficacy.

Poster Abstracts Veterinary Pathology

ANIMAL MODELS

119 | REFINEMENT OF MICRONEEDLES APPLICATION-A COMPARATIVE STUDY REGARDING SPECIES VARIATION IN SKIN HISTOLOGY

C. Santos^{*}, L. Leduque[†], G. Barandas^{*}, C. Jaworsky[†], A. Almeida^{*‡}, E. Silveira^{*§}, P. Carvalho[¶] and M.L. Pinto^{±*}

^{}Centro de Investigação Vasco da Gama and [†]Escola Universitária Vasco da Gama, Escola Universitária Vasco da Gama, [‡]Coimbra Institute for Biomedical Imaging and Translational Research (CIBIT) and [§]Faculdade de Farmácia, Universidade de Coimbra, [¶]Vetherapy, Vetherapy, Coimbra, PT and [±]Centro de Ciência Animal e Veterinária (CECAV) and ^{*}All4Animals, Universidade de Trás-osMontes e Alto Douro, Vila Real, PT*

Introduction

Microneedles (MN) have been used for different applications, from drug and vaccine systems delivery in medical procedures to cosmetics, among other new technologies. MN penetrate the skin, avoiding contact with nerve fibres and blood vessels in the dermal layer, inducing no pain. The aim of this study was to refine the procedures of MN design and application protocols regarding the dimensions/thickness of the epidermis and dermis of species commonly used in animal experimentation.

Materials and Methods

Skin samples from several animal species and body sites, i.e. pig's ear, sheep's podal extremity, rat's and dog's abdominal area were collected, and a MN device was applied manually. Samples were formalin-fixed, routinely processed for histology, and sections stained with HE. Measurement of the different skin structures was assessed by microscopy and DinoCapture 2.0 software.

Results

The histological examination revealed variations in the thickness of the epidermis and dermis between the studied species. The epidermis was thickest in the pigs' ear skin (1003.48 µm) and thinnest in the rat abdominal skin (136.276 µm).

Conclusions

This study provides valuable data for optimization of MN design based on specific animal species and the desired point for drug delivery. This optimization process allows the refinement and standardization of MN devices, ultimately leading to enhanced precision and effectiveness in drug administration.

Acknowledgements: This work is funded by FEDER funds through the COMPETE 2020 Program and National Funds through FCT - Portuguese Foundation for Science and Technology under the project FlexMicroDerm with reference POCI-01-0145-FEDER-029274 (PTDC/BTM-MAT/29274/2017).

Poster Abstracts Veterinary Pathology

ANIMAL MODELS

121 | EFFECTS OF KETAMINE ADMINISTRATION ON THE EXPRESSION OF SOX 2 IN THE ZEBRAFISH CNS

C. Santos^{*}, L. Félix[†], A.M. Valentim^{‡,§}, L. Antunes[†] and M.L. Pinto^{¶,‡}

^{}Centro de Investigação Vasco da Gama (CIVG), Escola Universitária Vasco da Gama, Coimbra, PT, [†]Centro de Investigação e de Tecnologias Agroambientais e Biológicas (CITAB), [‡]Instituto de Investigação e Inovação em Saúde (i3S) and [§]Instituto de Biologia Molecular e Celular (IBMC), Universidade do Porto, Porto, PT, [¶]Centro de Ciência Animal e Veterinária (CECAV) and [‡]All4Animals, Universidade de Trás-os-Montes e Alto Douro, Vila Real, PT*

Introduction

Zebrafish is one of the most used animal species in research with increased significance in toxicology studies, due to well described biological advantages. Ketamine is a commonly used anesthetic in humans the effects of which on development and stemness capability of the central nervous system (CNS) of zebrafish are poorly described. The transcription factor sex determining region Y-box 2 (Sox 2) has multiple roles, being a major pluripotency factor required in early neurogenesis. This study aimed to determine the Sox 2 expression and distribution patterns in the zebrafish brain at different timepoints following ketamine exposure.

Materials and Methods

Zebrafish embryos (1-4 somites stage, 10.5 hours post fertilization, hpf) were randomly allocated to study groups (control, ketamine concentrations at 0.2 and 0.8 mg/mL). Animals were grown until defined timepoints (50 hpf, 144 hpf, 7 months adults), then collected, embedded in paraffin or stored at -80 °C. Sox 2 expression patterns and levels were assessed by immunohistochemistry (IHC) and western blot (WB).

Results

There were no significant alterations in Sox 2 levels as detected by WB. Sox 2 immunoexpression in CNS was found in the areas previously reported to be positive (olfactory bulb and telencephalic ventricle), and in areas previously described as Sox 2 negative in adults, such as the cerebellum and vagal lobe.

Conclusions

Widespread Sox 2 expression in adult zebrafish CNS indicates that ketamine has no detrimental effects and that, in contrast to mammals, the stemness and pluripotency capabilities of Sox 2 are retained throughout the zebrafish life.

Acknowledgements: This work was funded by FEDER funds through the Operational Competitiveness Programme-COMPETE and by National Funds through FCT-Fundação para a Ciência e a Tecnologia under the project FCOMP-01-0124-FEDER-028683 (PTDC/CVT-WEL/4672/2012).

Poster Abstracts Veterinary Pathology

ANIMAL MODELS

124 | ASSESSING THE IN VIVO EFFECTS OF ALOYSIA CITRODORA EXTRACT: DATA FROM K14-HPV16 TRANSGENIC MICE

B. Medeiros-Fonseca^{*,†}, H. Vala^{‡,§}, C. Vasconcelos-Nóbrega^{*,¶}, A.I. Faustino-Rocha^{*,‡}, R. Medeiros[†], M. Bastos^{*,Δ}, R. Gil da Costa^{*} and P.A. Oliveira^{*}

^{}Centre for the Research and Technology of Agro-Environmental and Biological Sciences (CITAB), University of Trás-os-Montes and Alto Douro, UTAD, Vila Real, [†]Molecular Oncology and Viral Pathology Group, Research Center of IPO Porto, [‡]Centro de Investigação e de Tecnologias Agroambientais e Biológicas (CITAB), [§]CERNAS, Escola Superior Agrária de Viseu, Instituto Politécnico de Viseu, Campus Politécnico, 3504-510 Viseu, [¶]Escola Superior Agrária de Viseu, Instituto Politécnico de Viseu, Campus Politécnico, 3504-510 Viseu, ^ΔDepartment of Zootechnics, School of Sciences and Technology, University of Évora, Évora, ^{*}Laboratory for Process Engineering, Environment, Biotechnology and Energy (LEPABE), Faculty of Engineering, University of Porto (FEUP), 4200-465 Porto and ^ΔAssociate Laboratory in Chemical Engineering (ALiCE), FEUP, 4200-465 Porto, PT and Postgraduate Programme in Adult Health, UFMA, BR*

Introduction

Aloysia citrodora is used in folk medicine in the preparation of infusions due to its antispasmodic, digestive, sedative, and antipyretic properties. It also has antioxidant and antimicrobial properties. The present study evaluated the in vivo efficacy of aqueous extract (AE) of Aloysia citrodora in K14-HPV16 transgenic mice which HPV16 early genomic region and hence develop multiple-step epithelial neoplasia.

Materials and Methods

Thirty wildtype (WT) or K14-HPV16 female mice were divided into six groups (G) (n=5): G1 (WT, control), G2 (HPV, control), G3 (WT, 0.013g/mL), G4 (HPV, 0.006g/mL), G5 (HPV, 0.008g/mL), G6 (HPV, 0.013g/mL). AE was prepared and provided in drinking water every 48 h; the experiment lasted 28 days. Body weight, food and water consumption and humane endpoints were recorded weekly. At necropsy, organs were collected and processed for histological analysis.

Results

The mean body weight of all animals increased throughout the experiment (p<0.05). Food and water intake were slightly higher in the HPV groups. The humane endpoints score was different between G2 and G4, and G4 and G5 (p<0.05). The skin lesions in K14-HPV16 mice comprised hyperplasia, dysplasia, benign tumours (papillomas) and malignant tumours (carcinomas), with the worst lesions registered on the ear pavilion in G2, followed by G5 (p<0.05). The higher dose group (G6) showed fewer malignant tumours (p<0.05).

Conclusions

The results indicate that AE is safe for the studied animals, showing a dose-dependent trend towards lesion improvement. As AE is a natural product, the authors believe that further studies including higher doses are now warranted.

Acknowledgements: BMF is supported by FCT through grant number 2020.07675.BD. This work is supported by National Funds from FCT under the project UIDB/04033/2020. CERNAS UIDB/00681/2020.

Poster Abstracts Veterinary Pathology

ANIMAL MODELS

141 | HERPES SIMPLEX VIRUS TYPE 1 (HSV-1) INDUCED KERATITIS: NANOPARTICLES AND ANTIVIRAL PEPTIDES AS A NOVEL TOPICAL TREATMENT

I. Ruedas-Torres^{*}, Y. Jiménez-Gómez[†], L. Ortega-Llamas[†], J. Gómez-Laguna^{*}, M. González-Andrades[†], M. Griffith^{‡,§} and L. Cornea Consortium^{¶,*}

^{}Department of Anatomy and Comparative Pathology and Toxicology, Pathology and Immunology Group (UCO-PIG), UIC Zoonosis y Enfermedades Emergentes ENZOEM, University of Córdoba, International Excellence Agrifood Campus 'Ceja3', University of Córdoba and [†]Department of Ophthalmology, Maimonides Biomedical Research Institute of Córdoba (IMIBIC), Reina Sofía University Hospital and University of Córdoba, Córdoba, ES, [‡]Department of Ophthalmology and Institute of Biomedical Engineering and [§]Maisonneuve-Rosemont Hospital Research Centre, [¶]Department of Ophthalmology, Vilnius University Hospital, Vilnius, LT and ^{*}Department of Microbiology, Infectology and Immunology, University of Montreal, Montreal, CA*

Introduction

Herpes simplex virus type 1 (HSV-1) is a global health problem which can cause blindness due to uncontrolled inflammation that damages corneal tissue. In this work we studied the effect of four formulations in rabbit cornea models infected with HSV-1..

Materials and Methods

Perforations were made in the left eyes of 24 rabbits (6 rabbits/group) and were infected with HSV-1. Animals were treated for 6 months with four different formulations: cyanoacrylate adhesive (group 1), LiQD Cornea (liquid hydrogel matrix with collagen peptides, polyethylene glycol and fibrinogen) (group 2), LiQD Cornea+SiN9-GF19 (nanoparticles coated with the antiviral peptide GF19) (group 3) and LiQD Cornea+SiN9-GF19+ointment (with SiN9-GF19) (group 4). Samples were collected for histopathological and immunofluorescence investigation.

Results

Corneas from groups 1, 2, and 3 showed more severe histopathological lesions, mainly a higher degree of inflammatory infiltration and stromal neovascularization. On the other hand, regeneration of the corneal epithelium (CK3+) was observed in the treated groups that contained LiQD Cornea in their formulation (groups 2, 3, 4). The expression of α -SMA was significantly lower in corneas of animals from group 2, while β III tubulin expression was lower in groups 2, 3 and 4. In addition, viral antigen was not detected in the corneas of the animals belonging to these last two groups.

Conclusions

Our results suggest the greatest efficacy of the formulation containing LiQD Cornea + SiN9-GF19 + ointment (with SiN9-GF19), as it stopped the viral infection and induced corneal regeneration, similar to a healthy cornea 6 months after the operation.

Poster Abstracts Veterinary Pathology

ANIMAL MODELS

165 | POST-MORTEM FINDINGS IN NEONATAL C57BL/6J PUPS

S. Capas-Peneda^{*†}, G. Munhoz Morello^{*}, J.B. Prins[‡], I.A.S. Olsson^{*} and C. Gilbert[§]

^{}Laboratory Animal Science, i3S - Instituto de Investigação e Inovação em Saúde da Universidade do Porto and [†]ICBAS - School of Medicine and Biomedical Sciences, Porto, PT, [‡]The Francis Crick Institute, London, GB and [§]Babraham Institute, Cambridge, GB*

Introduction

The laboratory mouse accounts for 49% of all animals used in the EU in 2020. C57BL/6J is the most frequently used strain, both as a wild-type and as background strain for genetically modified animals. We found high neonatal mortality rates for this strain, reaching 30% in some facilities, but with considerable variation between facilities. Consequently, it is imperative to understand causes of neonatal death in C57BL/6J mice. This study determined post-mortem findings in C57BL/6J pups found dead on their first day of life (D0).

Materials and Methods

Neonatal C57BL/6J pups found dead on D0 originating from one facility were collected during a period of 6 months for post-mortem analysis. An established necropsy protocol was applied, to identify significant malformations, external and internal traumatic injuries, and to assess viability indicators such as hard palate, tongue morphology, stomach contents, stillbirths identification (hydrostatic test, lung morphology and stomach contents), and the condition of brown adipose tissue.

Results

Fifty-three D0 C57BL/6J pup cadavers were collected, weighing 1.2 ± 0.2 g and measuring 2.7 ± 0.2 cm. Traumatic injuries were observed in 12 (23%) pups, and all pups lacked milk in their stomachs. Microphthalmia was the only detected congenital abnormality. Sixteen pups (30%) were classified as stillbirths.

Conclusions

The results show no evidence of successful suckling and a high stillbirth rate in D0 C57BL/6J mice. Primary causes of death could be linked to starvation and low vitality at birth. Further research is required to elucidate the underlying mechanisms of these findings.

Poster Abstracts Veterinary Pathology

ANIMAL MODELS

202 | AI-DRIVEN QUANTIFICATION OF CRYPTOSPORIDIUM SPP. IN THE INTESTINE OF INFANT MICE

C. Goepfert^{*†}, M. Dale[‡], A.G. Valenti[‡], I. Klebic[§], J. Franzen[‡], M. Siffert[‡], S. Rottenberg[‡] and P. Olias[¶]

^{*}COMPAT, Institute of Veterinary Pathology, University of Bern, Bern, CH, [†]Histology Core Facility, École Polytechnique Fédérale de Lausanne, Lausanne, CH, [‡]Institute of Veterinary Pathology, University of Bern, Bern, CH and [§]BASF, Ludwigshafen, DE and [¶]Institute of Veterinary Pathology, Justus Liebig University, Giessen, DE

Introduction

The protozoan parasite *Cryptosporidium* spp. is the causative agent of a life-threatening enteric disease in infants and calves. The molecular mechanisms involved in the pathogenesis of the disease are not fully understood, resulting in a lack of preventive and curative treatments. Therefore, in-depth research on cryptosporidiosis using small animal models is essential. Here we present an infant mouse model mimicking cryptosporidiosis in the human and bovine host.

Materials and Methods

Newborn mice were orally infected with *C. parvum* and sacrificed after one, two, three, nine, 35 and 97 days. Small and large intestines were formalin-fixed, paraffin-embedded and HE stained. Whole-slide image analysis (Visiopharm) was used to localize and quantify protozoa in all parts of the intestine and to follow their occurrence in the different compartments of the mucosal epithelium over time. In parallel, part of the ileum of infected and mock-infected mice was harvested for scRNAseq analysis.

Results

Image analysis data showed parasites in the small intestine from day one post-infection (p.i.), with the highest parasite burden in the ileum on day three. No parasites were found on days 35 and 97 p.i.. Protozoa were first detected at the villus base (day one p.i.) before covering the entire villus (day three p.i.) and then again present at the villus base and within the crypts (day nine p.i.).

Conclusions

The results presented here provide new insights into the pathogenesis of cryptosporidiosis. Automated image analysis is an accurate method to diagnose and quantify *Cryptosporidium* spp. in a consistent manner.

Poster Abstracts Veterinary Pathology

ANIMAL MODELS

207 | A NOVEL SARS-COV-2 MODIFIED LIVE VACCINE WITH AN OPTIMIZED SAFETY PROFILE INDUCES STERILE IMMUNITY IN SYRIAN HAMSTERS

A. Breithaupt*, **T. Britzke***, **J. Schön†**, **G.T. Barut‡**, **N.J. Halwe†**, **L. Ulrich†**, **N. Ebert‡**, **B. Trüb‡**, **M. Brügger‡**, **V. Thiel‡,§**, **M. Beer†** and **D. Hoffmann†**

**Department of Experimental Animal Facilities and Biorisk Management and †Institute of Diagnostic Virology, Friedrich-Loeffler-Institute, Greifswald-Insel Riems, DE, ‡Department of Infectious Diseases and Pathobiology, Institute of Virology and Immunology, Vetsuisse Faculty, University of Bern and §Multidisciplinary Center for Infectious Diseases, University of Bern, Bern, CH*

Introduction

mRNA-based SARS-CoV-2 vaccines prevent severe clinical outcomes in humans but do not efficiently break transmission chains. Here we evaluated an attenuated live vaccine, based on the "one-to-stop (OTS)" genome recoding attenuation method in Syrian hamsters. We investigated the level of attenuation and protective potential, including the ability of inducing sterile immunity.

Materials and Methods

For the attenuation study, we inoculated Syrian hamsters intranasally with 10^{3.6} TCID₅₀/animal of the live vaccine candidate OTS-228. Naïve contact animals were screened for virus transmission. For protection, we immunized hamsters with OTS-228 and challenged them 21 dpi with homologous ancestral SARS-CoV-2, and heterologous Omicron BA.2 or BA.5. Attenuation and protection was evaluated through survival data, body weight, tissue virus RNA load, virus shedding, histopathology and virus antigen detection.

Results

The OTS-228 vaccine candidate was fully clinically attenuated and led neither to pneumonia-related atelectasis nor SARS-CoV2 characteristic vascular lesions, peribronchial infiltrates or necrotizing bronchitis. Virus antigen was detected associated with slight expansion of the pulmonary interstitium by mainly macrophages. The vaccine virus was not transmitted to naïve contact animals. Vaccinated animals were protected from clinical disease and pneumonia-related atelectasis post challenge infection. OTS-228 vaccination also efficiently protected against replication of the challenge virus in the lungs, provided sterile immunity following homologous but not after heterologous challenge infection.

Conclusions

The vaccine candidate OTS-228 meets all safety criteria for a SARS-CoV-2 live vaccine in the sensitive hamster model and has the efficacy to protect and induce strong immunity that can even inhibit SARS-CoV-2 transmission.

Poster Abstracts Veterinary Pathology

EXOTIC, WILDLIFE AND NON-HUMAN PRIMATES

7 | PCR-CONFIRMED ENTAMOEBA INVADENS-ASSOCIATED HEPATOCOLITIS IN 3 CO-HOUSED HOME'S HINGEBACK TORTOISES (KINIXYS HOMEANA)

I.I. Payne, M.F. Stidworthy, S.M. Thornton and A.F. Rich

International Zoo Veterinary Group, Keighley, GB

Introduction

Entamoeba invadens is an amoeboid protozoan known to be highly pathogenic in lizards and snakes. A single PCR-confirmed case is documented in a river turtle but reports of presumptive cases affecting terrestrial chelonians lack molecular confirmation by PCR testing. This presentation documents a rare outbreak of PCR-confirmed *Entamoeba invadens* infection in 3 co-housed terrestrial chelonians.

Materials and Methods

Three deceased Home's hingeback tortoises were submitted by a zoological collection over a two-month period for full post-mortem examination.

Results

Primary gross lesions included: 1) hepatomegaly with multifocal, 2-5mm diameter, pale-cream/tan, irregularly circular depressions rimmed by melanin pigment over the capsular surface and cut surfaces, and 2) catarrhal colitis with diffuse submucosal oedematous thickening, reddened mucosa, and moderate amounts of intraluminal mucoid fluid. Direct microscopy of colonic content revealed moderate numbers of large ciliate protozoa (consistent with *Balantidium coli*) and low numbers of smaller non-ciliate amoeba-like protozoa. Main histological lesions included: 1) marked, multifocal to coalescing random acute hepatic necrosis with intralesional protozoa (consistent with *Entamoeba* spp.) and occasional multifocal bacillary bacterial colonies, and 2) marked subacute diffuse erosive and heterophilic colitis with submucosa oedema and intralesional (*Entamoeba*-like) protozoa and mixed colonising bacteria. Pooled liver samples were positive on PCR analysis for *Entamoeba* spp. and *Entamoeba invadens*.

Conclusions

This PCR-confirmed outbreak of *Entamoeba invadens* infection substantiates past suspicions that this *Entamoeba* species can induce clinical disease in terrestrial chelonians and may be transmissible. Whilst the source of infection was unknown, co-housed reptiles or faecal contamination cannot be excluded.

Poster Abstracts Veterinary Pathology

EXOTIC, WILDLIFE AND NON-HUMAN PRIMATES

28 | FIRST ISOLATION OF STAPHYLOCOCCUS PSEUDINTERMEDIUS IN A CASE OF PYOMETRA IN A RED FOX (VULPES VULPES)

S. Roels*, **A. Vandekerkhove***, **E. Rolly***, **E. Forrez*** and **N. Caliskan***

*Pathology, Laboratory Dierengezondheidszorg Vlaanderen (DGZ), Torhout, BE

Introduction

Data on uterine pathology in wild canids are scarce and mainly concern captive animals in breeding programs of zoos. Here we report on a case of pyometra in a red fox, a highly opportunistic and successful wild carnivore.

Materials and Methods

A female fox was found dead in the countryside. Necropsy was performed and samples of different organs including uterine horns and enlarged right ovary were taken for histological examination. The purulent material was put on an aerobic culture medium followed by MALDI-TOF MS.

Results

The animal was in a good nutritional condition. It presented with an enlarged, hyperaemic uterus, with distention of the upper right horn and two dilations of the external wall of the left horn. The lumen was filled with purulent material, the cervix was closed. The right ovary was enlarged. Histologically, the uterus showed a diffuse mixed cellular and necrotic endometritis with intralesional bacterial aggregates, extending to the myometrium. The uterine lumen was mainly filled with neutrophils interlaced with necrotic material and coccoid bacteria. The bacterial examination revealed a pure culture of *S. pseudintermedius*.

Conclusions

In bitches, pyometra is the most frequent reproductive disease, mainly caused by *E. coli*. The natural hosts of *S. pseudintermedius* are dogs and foxes, infections are observed in dogs, cats and humans. Given the challenge of canid conservation it is important that further research focuses on the effect of *S. pseudintermedius* on reproductive health and fertility of wild canids, as well as its zoonotic potential.

Poster Abstracts Veterinary Pathology

EXOTIC, WILDLIFE AND NON-HUMAN PRIMATES

29 | TESTICULAR DEGENERATION DUE TO SUSPECT CHRONIC THEOBROMINE POISONING IN TWO RESCUED COATIS (NASUA SPP.)

E. Correa Dos Santos* and **B. McHale†‡**

**Pathology department, †Department of Pathology and ‡Zoo and Exotic Animal Pathology Service (ZEAPS), University of Georgia, Athens, US*

Introduction

Theobromine and caffeine are the most common methylxanthines present in high concentrations in cacao or/and caffeine. Theobromine absorption and excretion is slow in animals, therefore, the half-life is longer in most animals. In humans, there is increasing evidence that theobromine ingestion is involved in changes in endogenous physiological adrenocortical secretion and the development of testicular pathological changes, including cancer. Here we report testicular degeneration in two male Coatis (*Nasua spp.*) with a history of being fed a theobromine-rich diet.

Materials and Methods

Two rescued, 4-year-old Coatis (*Nasua spp.*) used for entertainment in a circus were neutered in a private veterinary practice in Texas, USA. The animals presented with friable testicles with scattered firm foci. Both had a history of being indiscriminately fed with food containing theobromine (e.g., cupcakes, chocolate). The testicles of both animals were submitted to the Zoo and Exotic Animal Pathology Service at the University of Georgia, USA, for histopathological analysis. The samples were histologically processed and stained with HE, Masson's trichome, and for the expression of MelanA (IHC).

Results

Histologically, both animals presented with diffuse partial or complete lack of spermatogenesis, along with germ cell degeneration, disorganization, and depletion. Severely affected tubules were sclerotic with mineralized spermatozoa and fibrosis. Approximately 90% of epididymal tubules were devoid of spermatozoa. Additionally, there were multifocal spermatozoa granulomas. One of the animals also had bilateral interstitial cell hyperplasia.

Conclusions

Considering the clinical history, the testicular histopathological alterations are comparable to theobromine-induced lesions reported in other species.

Poster Abstracts Veterinary Pathology

EXOTIC, WILDLIFE AND NON-HUMAN PRIMATES

41 | CRYPTOSPORIDIUM ANDERSONI ASSOCIATED PROLIFERATIVE ABOMASITIS IN A ROAN ANTELOPE (HIPPOTRAGUS EQUINUS)

S. Fingerhood^{*†}, J. Shotton[‡], C. Gola^{*†} and M. Betson[†]

^{}Veterinary Pathology Centre and [†]Comparative Biomedical Sciences, University of Surrey, Guildford, GB and [‡]Veterinary Department, Marwell Wildlife Zoological Park, Winchester, GB*

Introduction

Cryptosporidium spp. are zoonotic, intracellular and extracytoplasmic apicomplexan parasites; infections are an important cause of potentially life-threatening diarrhoea in a wide variety of vertebrate species worldwide. *C. andersoni* infections have mainly been described in cattle and camels, with occasional reports in humans. Though many cryptosporidia have a tropism for small intestinal enterocytes, *C. andersoni* preferentially infects abomasal epithelia in cattle. In other species, clinical findings, as well as the gross and histologic lesions associated with *C. andersoni* have not been described.

Materials and Methods

A 2 year-old male zoo-housed, roan antelope (*Hippotragus equinus*) was submitted for routine post-mortem investigation after a prolonged history of diarrhoea and weight loss. Genomic DNA was extracted from abomasal and intestinal contents and subject to PCR using primers specific for the 18S rRNA gene of *Cryptosporidium* spp., followed by Sanger sequencing.

Results

Gross findings included a diffusely thickened and corrugated abomasal mucosa. Histologically, the apical surface of the markedly hyperplastic abomasal mucosa was lined by abundant structures consistent with *Cryptosporidium* spp.. Ziehl-Neelsen staining of abomasal content smears highlighted abundant acid-fast positive structures consistent with *Cryptosporidium* spp. All samples tested were positive by 18S PCR and sequences were most closely homologous to *Cryptosporidium andersoni*.

Conclusions

This is the first report of abomasal cryptosporidiosis in a roan antelope. Zookeepers and veterinarians should consider this pathogen in cases of diarrhoea in this species. This agent is a zoonotic pathogen and early diagnosis of animals in captivity may help to prevent human cases, especially in immunocompromised patients.

Poster Abstracts Veterinary Pathology

EXOTIC, WILDLIFE AND NON-HUMAN PRIMATES

47 | INTRAABDOMINAL SOFT TISSUE SARCOMA IN AN ELDERLY CALIFORNIA SEA LION FROM A ZOO

I.C. Šoštarić-Zuckermann*, **D. Huber***, **B. Artuković***, **M. Hohšteter***, **L. Medven Zagradišnik***, **D. Vlahović***, **I. Mihoković Buhin***, **I. Bata†** and **A. Gudan Kurilj***

**Department of Veterinary Pathology, Veterinary Faculty, University of Zagreb and †Zagreb ZOO, Zagreb, HR*

Introduction

Neoplastic diseases in sea lions are frequent. Unfortunately, most of these are due to human-driven pollution of their habitat. However, tumours associated with high age in zoo-kept sea lions are uncommon. This report presents one such case with multiple intraabdominal tumour masses in an elderly Californian sea lion.

Materials and Methods

A 27-year-old male California sea lion (*Zalophus californianus*) was submitted for necropsy from Zagreb Zoo. During routine necropsy samples of the tumour masses were taken and the following histochemical or immunohistochemical stains were performed: haematoxylin and eosin, periodic acid-Schiff (PAS), vimentin, pancytokeratin, smooth muscle actin (SMA), S-100 protein (S-100), glial fibrillary acidic protein (GFAP) and neuron-specific enolase (NSE).

Results

Necropsy revealed two multilobulated, round, pink to grey, soft elastic, 13 and 3cm in diameter intraabdominal masses that were attached to the jejunal mesentery. Microscopical examination revealed a moderately cellular mass supported by scant stroma often containing watery extracellular matrix or protein, and composed of poorly defined streams and bundles of mostly plump but also elongated and oval-shaped, medium-sized cells. Large areas of the tumour were necrotic or haemorrhagic, mitoses were moderately frequent. PAS, pancytokeratin, SMA, and GFAP stains were negative, while vimentin, S-100, and NSE were expressed. The animal died due to causes unrelated to the tumour (chronic heart failure).

Conclusions

Based on the results the diagnosis of soft tissue sarcoma was made. The morphology of the cells and findings of the IHC-markers used favour the diagnosis of schwannoma.

Poster Abstracts Veterinary Pathology

EXOTIC, WILDLIFE AND NON-HUMAN PRIMATES

51 | OVARIAN TERATOMA IN A FREE RANGING ROE DEER (*CAPREOLUS CAPREOLUS*)

C. Pigoli*, **I. Karaman***, **E. Brambilla†**, **V. Grieco†**, **L.R. Gibelli*** and **A. Bianchi***

**Istituto Zooprofilattico Sperimentale della Lombardia e dell'Emilia-Romagna, Brescia, IT and †Dipartimento di Medicina Veterinaria e Scienze Animali, Università degli Studi di Milano, Lodi, IT*

Introduction

Ovarian teratomas (OTs), rare neoplasms composed of endodermal, mesodermal, and ectodermal derived elements (DEs), can occur in various species, including wildlife. However, there is limited knowledge about the occurrence of OTs in deers, with only 3 cases reported in the roe deer (RD) [*Capreolus capreolus*]. Here we describe an OT found in a RD.

Materials and Methods

A 3-year-old free ranging female RD in poor condition, with low adipose deposits, was found dead and subjected to necropsy, revealing a pathological condition in the right ovary, that was sampled for histopathology.

Results

The right ovary, measuring 27 cm in maximum diameter and weighing 3.3 kg, appeared cocooned and polycystic, compressing the right uterine horn where a partially lytic fetus was present. Histologically, the ovary was replaced by a variably cellular, well-demarcated, multilobulated, and polycystic unencapsulated neoplasm with expansive growth and consisting of tissues derived from endoderm, mesoderm, and ectoderm. The endodermal DEs were squamous and columnar epithelial cells, delimiting alveolar and bronchiolar structures, respectively. The mesodermal DEs comprised myxoid, fibrous, and cartilaginous connective tissue. The ectodermal DEs included epidermal tissue, delimiting large cysts containing abundant lamellar keratin. Numerous pilosebaceous units, often containing hair shafts, radiated from these cysts. One mitosis was observed in 2.37 square millimeters. A diagnosis of OT was made.

Conclusions

OTs are rare neoplasms derived from pluripotent cells rarely described in wildlife. Further reports will be useful to better understand the incidence, cause, and impact of reproductive neoplasms, including OTs, in wild ungulate populations.

Poster Abstracts Veterinary Pathology

EXOTIC, WILDLIFE AND NON-HUMAN PRIMATES

60 | MULTICENTRIC CUTANEOUS HISTIOCYTIC PROLIFERATION RESEMBLING LANGERHANS CELL HISTIOCYTOSIS IN A HOWLER MONKEY (ALLOUATA PALLIATA)

A. Reyes-Matute*, **Y.A. Basilio-Cornejo†**, **G.Y. Castillo-Mendoza‡** and **A.C. Negrete-Philippe†**

**Departamento de Patología, Facultad de Medicina Veterinaria y Zootecnia, Universidad Nacional Autónoma de México, Mexico city, MX, †Grupo Xcaret, Grupo Xcaret, Quintana Roo, MX and ‡Facultad de Agronomía y Medicina Veterinaria, Universidad Autónoma de San Luis Potosí, San Luis Potosí, MX*

Introduction

Langerhans cell histiocytosis has been mostly described in humans and, although uncommon, it is well recognized in dogs. This case report describes the clinical and pathological aspects of a multifocal cutaneous histiocytic proliferation resembling Langerhans cell histiocytosis in a howler monkey.

Materials and Methods

An eleven-year-old male howler monkey (*Alouatta palliata*) was presented with mild lethargy, weight loss, and numerous skin lesions. The biggest one was located close to the elbow, others were reported to have grown and regressed. Seven months later, new skin masses had developed in the chest and submandibular region. Neither worsening of clinical signs nor lymphadenomegaly were reported, and a prednisone treatment was initiated. The largest initial masses (elbow and submandibular region) and some later masses were completely excised and subjected to histological and immunohistochemical examination.

Results

Microscopically, the masses consisted of large neoplastic round cells arranged in sheets. The cells had distinct margins and moderate to large amounts of eosinophilic cytoplasm. Nuclei were large and oval to reniform, with stippled chromatin and 1-3 small nucleoli. There was moderate to marked anisocytosis and anisokaryosis. The cells exhibited widespread and intense vimentin and Iba-1 expression, while CD3 staining was negative. The new skin masses exhibited identical histological features, but with a higher mitotic count.

Conclusions

In humans, it is not yet well established, whether this condition represents a neoplasm or an inflammatory response, and scarce information is available about its origin and clinical features in animals. No cases have previously been reported in new world primates.

Poster Abstracts Veterinary Pathology

EXOTIC, WILDLIFE AND NON-HUMAN PRIMATES

74 | TRICHOMONOSIS IN WILD BIRDS FROM ENGLAND AND WALES: A RETROSPECTIVE STUDY OF SUBMISSIONS TO THE ANIMAL AND PLANT HEALTH AGENCY (APHA)

C. Guerreiro*, **A. Schock***, **C. Poulos*** and **P. Holmes†**

**Diagnostic & Consultant Avian Pathology, Animal and Plant Health Agency (Lasswade), Penicuik, GB and †Diseases of Wildlife Scheme, Animal and Plant Health Agency (Shrewsbury), Shrewsbury, GB*

Introduction

Trichomonosis is a parasitic disease of wild birds caused by the protozoa *Trichomonas gallinae*. In England and Wales, wild bird disease surveillance is accomplished mainly through the APHA Diseases of Wildlife Scheme and the Garden Wildlife Health Project. Members of the public and wildlife organisations are encouraged to report wild bird mortalities and suitable cases are further investigated. This is a retrospective study of the range of species and pathological features of trichomonosis in wild birds submitted to APHA between 2018-2022.

Materials and Methods

All data were extracted from the APHA reporting system. Birds were initially tested for Avian Influenza Virus. Following a negative result, a detailed postmortem examination was performed.

Results

Between 2018-2022, 3612 submissions of wild birds were recorded on the APHA system. Trichomonosis was diagnosed as the cause of death in 62 cases. The disease was most frequently detected in columbiformes (21/144 submissions). It was diagnosed in 5/69 tawny owls, 14/183 sparrow hawks, 3/45 peregrine falcons and 15/471 buzzards. It was also found in one kestrel, two yellowhammers and a greenfinch. Most carcasses presented in poor body condition with necrotising lesions obstructing the alimentary tract. Lesions were detected in the oropharynx, larynx, crop, and oesophagus. In a few cases, there were coinfections with nematodes.

Conclusions

APHA Scanning surveillance confirmed trichomonosis in several species of wild birds, particularly in columbiformes and birds of prey. Future work could involve molecular studies to determine if there is any variation of strains between different bird species.

Poster Abstracts Veterinary Pathology

EXOTIC, WILDLIFE AND NON-HUMAN PRIMATES

81 | TEMPERATURE AFFECTS REPTARENAVIRUS INFECTION AND INCLUSION BODY FORMATION IN A HOMOTYPIC IN VITRO MODEL

F. Baggio*†, I. Krijestorac Berbic*†, E. Michalopoulou*, J. Hepojoki*†, A. Kipar* and U. Hetzel*

**Institute of Veterinary Pathology, Vetsuisse Faculty and †Center for Clinical Studies, Vetsuisse Faculty, University of Zurich, Zurich, CH and ‡Department of Virology, Medicum, Faculty of Medicine, University of Helsinki, Helsinki, FI*

Introduction

Reptarenaviruses cause Boid Inclusion Body Disease (BIBD), a lethal disease affecting in particular captive Boa constrictor populations. BIBD is characterized by cytoplasmic inclusion bodies (IBs), mainly composed of viral nucleoprotein, in many cell types. The study assessed the effect of reptarenavirus infection on cell growth, and of temperature on reptarenavirus growth and IB formation, a feature of potential relevance for snakes as poikilothermic animals.

Materials and Methods

A Boa constrictor kidney-derived cell line (I/1Ki) was inoculated with University of Giessen virus 1 (UGV-1) and incubated at different temperatures (24-36°C). At 3 and 6 days post-inoculation cell growth was assessed in infected vs mock-infected cells, and viral RNA release (qRT-PCR on cell culture supernatants), IB formation (immunohistology for viral nucleoprotein on cell pellets; morphometry) and subcellular changes (TEM) were determined.

Results

Cell proliferation was optimal at 30-34°C and not affected by UGV-1 infection. Viral RNA release per cell was highest at 28-32°C. IB measurements suggested that IB formation positively correlates with virus release. The ultrastructural findings corresponded to the immunohistological results regarding IB number and size and revealed limited damage to host cell mitochondria.

Conclusions

The results confirm previous evidence that reptilian cells grow optimally at lower temperatures than mammalian cells (<37°C). They indicate that reptarenavirus infection does not affect cell growth and that virus replication and IB formation is temperature-dependent. Therefore, environmental temperature control could be a tool to limit BIBD development as well as virus replication and, potentially, the spread of reptarenaviruses in captive snake colonies.

Poster Abstracts Veterinary Pathology

EXOTIC, WILDLIFE AND NON-HUMAN PRIMATES

102 | FATAL SEPTICAEMIC LISTERIOSIS IN A GOLDEN-HANDED TAMARIN (*SAGUINUS MIDAS*)

P. Mendonça*, **P. Carvalho***, **L. Orge*†**, **M. Monteiro***, **A. Azevedo*‡§**, **M.P.Teixeira¶** and **M.J. Fraqueza¶**

**Laboratory of Pathology, National Institute for Agricultural and Veterinary Research, I.P. (INIAV), Oeiras, PT, †Animal and Veterinary Research Centre (CECAV), University of Trás-os-Montes e Alto Douro (UTAD), Vila Real, PT, ‡Zoo de Lagos, Lagos, PT, §CIVG-Vasco da Gama Research Center, Vasco da Gama University School, Coimbra, PT and ¶Centre for Interdisciplinary Research in Animal Health (CIISA), Faculty of Veterinary Medicine, University of Lisbon, Lisbon, PT*

Introduction

Ubiquitous *Listeria monocytogenes* can cause a rare and severe food-borne disease in vertebrates, including humans, who develop different clinical signs and lesions. In ruminants, rhombencephalitis and meningoencephalitis are the main lesions. However, humans can also present with abortion, gastrointestinal disease and septicaemia. We report a case of sudden death in a captive golden-handed tamarin due to septicaemic listeriosis.

Materials and Methods

A captive 10-year-old male golden-handed tamarin (*Saguinus midas*) was found dead without prior signs of illness. Necropsy was carried out with toxoplasmosis, yersiniosis, and bacterial/viral hepatitis as differential diagnoses. Tissue samples were collected for histopathology, bacteriology and parasitology. DNA extraction on formalin-fixed and paraffin-embedded liver and brain tissues was performed for *L. monocytogenes* PCR diagnosis and molecular serogroup determination by multiplex PCR.

Results

Gross examination revealed pulmonary congestion and discrete white spots in the liver. Histology showed necrotic foci with mononucleated cells and numerous Gram-positive coccobacilli in liver and spleen. Clusters of these bacteria were also detected in renal interstitial vessels and glomerular and alveolar capillaries. Non-suppurative meningitis and granulomatous encephalitis with intralesional Gram-positive coccobacilli were also observed. PCR of hepatic and brain tissue detected *L. monocytogenes* (4b serogroup).

Conclusions

We report the first case of septicaemic listeriosis in a golden-handed tamarin caused by *L. monocytogenes* 4b serogroup, a serogroup frequently detected in human clinical isolates. The results show that listeriosis should be included in the differential diagnosis of bacterial hepatitis and meningoencephalitis in this species and possibly primates in general.

Poster Abstracts Veterinary Pathology

EXOTIC, WILDLIFE AND NON-HUMAN PRIMATES

123 | OCULAR LESIONS IN BIRDS OF PREY IN PORTUGAL-A RETROSPECTIVE STUDY

L. Ribeiro*, **M.V. Casero†**, **C. Nunes‡**, **M. Ribeiro§**, **R. Sargo¶·‡**, **F. Silva¶·‡**, **E. Correia*** and **M.L. Pinto^Δ**

**University of Trás-os-Montes and Alto Douro, Vila Real, PT, †Wildlife Rehabilitation and Research Centre (RIAS), Olhão, PT, ‡Wildlife Recovery Center of Santo André (CRASSA), Quercus ANCN, Vila Nova de Santo André, PT, §Center for The Study and Recovery of Wild Animals (CERAS), Quercus ANCN, Castelo Branco, PT and ¶Wildlife Rehabilitation Centre (CRAS), †Veterinary Teaching Hospital, *Center for Computational and Stochastic Mathematics (CEMAT), Instituto Superior Técnico - University of Lisbon, Lisboa, PT, ΔAnimal and Veterinary Research Centre and AL4AnimalS, University of Trás-os-Montes and Alto Douro, Vila Real, PT*

Introduction

Every year, thousands of animals are admitted to wildlife rehabilitation centres, and birds of prey represent a large proportion of these admittances. Vision is a vital sense in birds of prey, and vision ability is directly related to their hunting skills, which are fundamental to survival. The aim of this study was to determine the type of ocular injuries and factors related to the admittance of birds of prey in 4 centres located in different geographical areas of continental Portugal during the period of 2017-2021.

Materials and Methods

Data regarding the admittance of 156 birds of prey with ocular lesions was analysed. Whenever possible, eye samples were collected, fixed in Davidson's fixative and subjected to histological evaluation.

Results

The most frequent lesions were hyphema, observed in 44 animals (28.2%), and corneal ulcer, diagnosed in 32 individuals (20.5%). A statistically significant association was found between these lesions ($p=0.003$), as well as between hyphema and lens luxation ($p=0.021$). The prevalence of ocular lesions was higher in nocturnal raptors (76.9%). A positive correlation ($p=0.006$) was observed between ocular lesions and cause of admittance, with haemorrhages and multiple injuries having the highest degree of association. Despite the nature of the injuries, the release rate (51%) was high.

Conclusions

Ocular examination is of pivotal importance regarding decision-making for release purposes. More extensive studies are needed, in order to trace the impact of this type of injury on the recovery of wild birds and their return to the natural habitat in Portugal.

Acknowledgements: This work is supported by National Funds by FCT - Portuguese Foundation for Science and Technology, under the projects UIDB/04033/2020, UIDP/CVT/00772/2020, LA/P/0059/2020

Poster Abstracts Veterinary Pathology

EXOTIC, WILDLIFE AND NON-HUMAN PRIMATES

127 | BOTULISM OUTBREAK IN ASIAN ELEPHANTS: HISTOPATHOLOGICAL FINDINGS AT NECROPSY

P.J. De Andres Gamazo*, **E. Pavón†**, **J. Stumpel‡**, **T. Bouts§**, **W. Schaffenaar¶**, **M. Kik‡** and **M.d.I.Á. Jiménez Martínez***

**Zoo and Wildlife Pathology Service, Complutense University of Madrid, Madrid, ES, †Reserva del Castillo de las Guardas, ES, ‡Wildlands Zoo, Emmen, NL, §Pari Daiza, Brugelette, BE, ¶Rotterdam Zoo, Rotterdam, NL and ‡Pathology division, Department of Biomedical Health Sciences, Utrecht University, Utrecht, NL*

Introduction

Six Asian elephants with severe progressive clinical signs of dysphagia, hyporexia, weakness and recumbency died at a zoological facility within a 12 day period. After ruling out many diseases, a postmortem diagnosis of botulism was made based on clinical signs observed in mice after intraperitoneal inoculation of digestive content of deceased elephants or silage used to feed the animals, and the isolation of *Clostridium botulinum* from these samples.

Materials and Methods

Complete necropsies were performed and tissues from every organ system, including brain, were processed for histopathology at the Pathology division, Department of Biomedical Health Sciences, Veterinary Medicine, Utrecht University, The Netherlands and the Zoo and Wildlife Pathology Service of the Complutense Veterinary Teaching Hospital of Madrid, Spain, following routine laboratory procedures. Samples from the digestive system were processed for additional laboratory tests.

Results

Histopathology revealed a severe systemic vascular disorder with oedema, congestion, haemorrhages, thrombi, and associated hypoxic degeneration and necrosis of affected tissues. Lung, liver, kidneys and gastrointestinal tract were vastly affected. These lesions were non-specific, but death was ultimately attributed to hypovolaemic shock, given the extent of the haemorrhages. No infectious agents were noted within any of the examined tissues.

Conclusions

Botulism causes flaccid paralysis produced by toxins that interfere with synapsis function by blocking acetyl-choline receptors. Morphologic alterations of nervous tissue are usually lacking or extremely unspecific, however some of the toxins produced by *C. botulinum* induce vascular alteration, congestion, vasogenic and interstitial oedema similar to what was observed in the present cases.

Poster Abstracts Veterinary Pathology

EXOTIC, WILDLIFE AND NON-HUMAN PRIMATES

135 | NEURODEGENERATIVE DISEASE WITH LAFORA BODIES IN AN EMU (DROMAIUS NOVAEHOLLANDIAE)

M.A. Jimenez Martinez*, **J. de Andres Gamazo***, **J. Garcia Garcia†**, **B. Lourdes Saldia†** and **E. Martínez Nevado†**

**Animal Medicine and Surgery, Complutense University of Madrid and †Zoo Aquarium Madrid, Madrid, ES*

Introduction

Lafora disease is an autosomal recessive neurodegenerative disease in humans characterized by cytoplasmic polyglucosan deposits in neuronal bodies and dendrites, hepatocytes, and cardiac cells, that causes progressive myoclonus epilepsy. A similar storage disease was diagnosed in an emu (*Dromaius novaehollandiae*) upon light and electron microscopic examination.

Materials and Methods

A 20 year old female emu (*Dromaius novaehollandiae*) with severe, progressive clinical signs of neurodegeneration, incoordination, hypermetria, ataxia and emaciation, was humanely euthanized at a zoological facility. Neurological signs had become evident 4 months prior and progressed in severity until death. Complete necropsy was performed and tissues from every organ system, including brain, were processed for histopathology following routine laboratory procedures. Samples from the brain were processed for transmission electron microscopy.

Results

Almost 100% of the cerebellar Purkinje cells and brain stem neurons contained 25-75 micron inclusions with pale basophilic to amphophilic central cores rimmed by dark basophili, radiating spicules, compatible with Lafora bodies. Electron microscopy revealed glycoprotein cytoplasmic inclusions in the soma of neurons and Purkinje cells.

Conclusions

Results were consistent both clinically and morphologically with Lafora disease. Lafora inclusions have also been reported in dogs and cockatoos. Although rare, other lysosomal storage diseases have been described in emu, but this is the first description of Lafora like inclusions associated with clinical neurologic dysfunction in this species.

Poster Abstracts Veterinary Pathology

EXOTIC, WILDLIFE AND NON-HUMAN PRIMATES

137 | CAUSES OF MORTALITY IN WILD EUROPEAN HEDGEHOG (*ERINACEUS EUROPAEUS*) POPULATIONS IN ITALY AND SWITZERLAND

I. Prandi*, **E. Dervas†**, **E. Colombino***, **L. Bertolotti***, **M. Cardello***, **D. Ippolito***, **M. Perotti***, **M. Vacchetta‡**, **S. Zanet***, **M. Mauthe Von Degerfeld***, **G. Quaranta***, **U. Hetzel†** and **M.T. Capucchio***

**Department of Veterinary Sciences, University of Turin, Turin, IT, †Institute of Veterinary Pathology, Vetsuisse Faculty, Zurich, CH and ‡Centro Recupero Ricci La Ninna, Cuneo, IT*

Introduction

The European hedgehog is a small insectivorous mammal whose populations show a consistent decline across different European countries. Human activities (e.g., landscape modifications, pesticide use, road traffic) are some of the main drivers of this phenomenon. However, so far few studies provided solid data on the pathological processes underlying hedgehog mortality. The aim of this study was to analyse gross and histopathological lesions and determine the main causes of mortality of European hedgehogs in Italy and Switzerland.

Materials and Methods

Deceased/euthanised hedgehogs were necropsied at Turin and Zurich Universities (years 2012-2022) and samples of the main organs processed for histological examination.

Results

A total of 265 hedgehogs were analysed (156 in Italy, 109 in Switzerland). The main histopathologic features were observed in the lungs, with interstitial and/or peribronchial lymphoplasmacytic infiltrates (39.4%), granulomatous (20.3%) or suppurative pneumonia (8.2%) and concurrent evidence of lungworms in 121 cases (77.1%). Other frequent lesions were lymphoplasmacytic hepatitis (24.6%), nephritis (12.8%), and enteritis (12.4%). Bone fractures/amputations, skin lacerations and brain haemorrhages were common findings in trauma cases. The primary cause of death were infections (70.6%; 39.0% of these led to septic processes), and traumata (11.9%) in Swiss cases, whereas Italian hedgehogs mostly died from traumata (46.8%), followed by infections (44.9%).

Conclusions

In contrast to previous studies, which report trauma as the main cause of hedgehog mortality, our results highlight the primary role of infections. These findings underline the importance of pathogen monitoring in hedgehogs while considering their interaction with humans and other animal species.

Poster Abstracts Veterinary Pathology

EXOTIC, WILDLIFE AND NON-HUMAN PRIMATES

143 | GRANULOMATOUS PNEUMONIA CAUSED BY MYCOBACTERIUM SIMIAE AND NECROULCERATIVE ENTERITIS CAUSED BY ENTAMOEBA SPP IN A PANTHER CHAMELEON (FURCIFER PARDALIS)

E. Martínez Fuentes, J.T. Pico Rodriguez, A. Reyes Matute and L.C. Martínez Chavarria

Departamento de patología, Facultad de Medicina Veterinaria y Zootecnia. Universidad Nacional Autonoma de México, Ciudad de México, MX

Introduction

Mycobacteria are ubiquitous in nature and can be isolated from soil, water and bioaerosols. Entamoeba is an protozoan that can cause ulcerative enterocolitis. Reptiles generally acquire mycobacteria and amoebae via ingestion. A 9-month-old male Panther chameleon (*Furcifer pardalis*) was presented with a history of dehydration, dyspnea, anorexia, and diarrhea. This case report describes the pathological aspects observed in this chameleon and the molecular identification of the aetiological agent.

Materials and Methods

A complete necropsy of the animal was performed and samples for histopathology were taken. Due to the evidence of an infectious process, histochemical stains, including PAS, Gram, and Ziehl-Neelsen were also applied. Additionally, PCR for *Mycobacterium* spp using total DNA extracted from formalin-fixed paraffin-embedded (FFPE) lung tissues and sequencing were performed.

Results

Macroscopically, the lungs presented multiple coalescent greyish-white nodules, and the intestine was severely distended. Histopathology revealed a severe and generalized necrohaemorrhagic and granulomatous bronchopneumonia with Gram-positive bacteria and intralesional acid-fast bacilli; the intestine exhibited a necrotic and ulcerative enterocolitis with evidence of intralesional 15-20 microns diameter, PAS positive amoebic trophozoites. PCR confirmed the presence of *Mycobacterium* spp by amplifying the mycobacterial 16S rRNA gene. Sequencing of the amplified fragment identified *Mycobacterium simiae* complex.

Conclusions

This case shows a polymicrobial infection in a chameleon, the granulomatous bronchopneumonia and the ulcerative enterocolitis are consistent findings in infections by mycobacteria and entamoeba. To our knowledge, this is the first report of granulomatous bronchopneumonia in a reptile caused by *Mycobacterium simiae* complex.

Poster Abstracts Veterinary Pathology

EXOTIC, WILDLIFE AND NON-HUMAN PRIMATES

148 | UV-LIGHT SKIN DAMAGE IN A CYNOMOLGUS MACAQUE (MACACA FASCICULARIS)

F. Parisi*, **M. Orlandi†**, **P. Laricchiuta‡**, **A. Carnimeo§**, **F. Millanta***, **M. Massaro†** and **F. Abramo***

**Department of Veterinary Sciences, University of Pisa, Pisa, IT, †Private Veterinary Laboratory "MyLav", Passirana di Rho (MI), IT, ‡Zoosafari, Fasano (BR), IT and §Animanatura - Wild Sanctuary, Semproniano (GR), IT*

Introduction

Chronic exposure to ultraviolet (UV) light causes cutaneous damage with specific histopathological findings, including actinic keratosis and dermatitis. These types of lesions have been widely described in humans and many animals. In the non-human primate group, which lacks a comprehensive literature on dermatological disease, this condition has rarely been reported. We describe a case of chronic UV-light exposure in a cynomolgus macaque (*Macaca fascicularis*).

Materials and Methods

A captive-bred adult female cynomolgus macaque, living in an indoor-outdoor enclosure, was presented with a seven-month-history of multifocal irregular alopecic, erythematous and hyperkeratotic plaques on the dorsum with itching. A skin biopsy was taken under sedation for histopathological examination.

Results

Histologically, the epidermis was moderately and regularly hyperplastic showing orthokeratotic hyperkeratosis, stratification disorder with dysplastic keratinocytes, scattered apoptosis and squamous cells within the basal layer. The upper dermis showed lamellar fibrosis and multiple areas of deposition of short basophilic fibrils between collagen fibers. Van Gieson staining highlighted thickened and fragmented fibrils, which were considered to be elastotic material. The diagnosis was actinic keratosis and dermatitis with elastosis. Systemic therapy with nutritional supplements (retinol and omega-3) and firocoxib (1/3 tablet 57mg/day for 15 days) was started without any improvement. Firocoxib was discontinued and topical therapy with aloe gel and a sunscreen spray (SPF50) was added. The lesions were stable. At the same time, two further cynomolgus macaques from the same enclosure developed similar lesions.

Conclusions

The authors describe UV-light induced skin damage in a cynomolgus macaque, which did not respond to systemic therapy.

Poster Abstracts Veterinary Pathology

EXOTIC, WILDLIFE AND NON-HUMAN PRIMATES

162 | PULMONARY ANGIOMATOSIS IN A MEDITERRANEAN STRIPED DOLPHIN

B. Serrano*, **L. Martino***, **J. Alomar***, **L. Abarca***, **L. Pérez***, **Y. Espada†** and **M. Domingo***

**Departament de Sanitat i d'Anatomia Animals* and †*Departament de Medicina i Cirurgia Animals, Facultat de Veterinària, Universitat Autònoma de Barcelona, Bellaterra, ES*

Introduction

Angiomatosis in dolphins was first described in 1999 in bottlenose dolphins (*Tursiops truncatus*) from the Gulf of Mexico, as a proliferation of small thin-walled blood vessels of unknown aetiology and high prevalence affecting the lungs and lymph nodes. Here we describe a case of pulmonary angiomatosis in a Mediterranean striped dolphin (*Stenella coeruleoalba*).

Materials and Methods

An adult female striped dolphin stranded alive showing weakness and increased respiratory frequency and died shortly thereafter. CT scan and a complete necropsy, with histopathologic and immunohistochemical examination, were performed.

Results

The CT scan showed attenuation (interstitial-alveolar pattern) at the medial and dorsal aspect of both lungs, compatible with pneumonia or atelectasis. At necropsy, the dolphin had a low body condition. The dorsomedial aspect of both lungs showed an extensive dark red area, not well demarcated and depressed. The cranioventral part had normal appearance. The dark areas sank in formalin. Histologically, there was a tortuous proliferation of thin-walled vessels with a thin smooth muscle layer, stained by smooth muscle actin-IHC. Vessels contained erythrocytes. No inflammatory changes were observed in vessels, alveolar spaces, airways, or pleura. Interstitial fibrosis was minimal, and haemangiomas were not seen. Respiratory lymph nodes showed no changes. A PCR for *Bartonella* on lung was negative. Bacteriology yielded abundant colonies of Gram-neg bacteria identified (API20NE) as *Pasteurella multocida*.

Conclusions

This is the first description of pulmonary angiomatosis in a Mediterranean cetacean, and its first CT imaging. Proliferating vessels were identified as small venules. The cause of the lesion was not determined.

Poster Abstracts Veterinary Pathology

EXOTIC, WILDLIFE AND NON-HUMAN PRIMATES

184 | PATHOLOGICAL FINDINGS ASSOCIATED WITH HIGHLY PATHOGENIC AVIAN INFLUENZA VIRUS (H5N1) INFECTION IN NATURALLY INFECTED FREE-RANGING BIRDS IN BARCELONA ZOO

L. Fuentes^{*,†}, B. Serrano[†], H. Fernández-Bellón^{*}, V. Almagro^{*}, J. Alomar[†], M. Domingo^{†,‡} and N. Majó^{†,‡}

^{*}Parc Zoològic de Barcelona, Parc de la Ciutadella s/n, 08003 Barcelona, [†]Servei de Diagnòstic de Patologia Veterinària (SDPV), Departament de Sanitat i Anatomia Animals, Facultat de Veterinària, Campus UAB, Travessera dels turons s/n, 08193 Bellaterra (Barcelona) and [‡]Centre de Recerca en Sanitat Animal (CRESA), IRTA, Campus UAB, 08193 Bellaterra (Barcelona), ES

Introduction

Currently, highly pathogenic avian influenza viruses (HPAI) are circulating widely in wild birds, causing mass mortality events. Common pathological findings in these species are not fully characterised. Here we describe the pathological outcome of an H5N1 HPAI outbreak in wild birds in Barcelona.

Materials and Methods

During December 2022, the passive HPAI surveillance programme at Barcelona Zoo identified one grey heron (*Ardea cinerea*) and one yellow-legged gull (*Larus michahellis*) positive for H5N1 HPAI by preliminary (IRTA-CRESA) and definitive (Laboratorio Central de Veterinaria- LCV) testing. A cattle egret (*Bubulcus ibis*) tested positive in IRTA-CRESA but negative in LCV. An exhaustive postmortem study was performed.

Results

Grossly, the grey heron presented widespread haemorrhagic enteritis. The seagull displayed multiorgan congestion and multifocal pancreatic necrosis. The cattle egret presented a subcutaneous haematoma in the neck. Histologically, the first two animals presented multisystemic lymphoplasmacytic and heterophilic vasculitis, moderate gliosis and neuronal degeneration; with viral antigen expression in the glial and endothelial cells. In addition, the grey heron presented a generalised haemorrhagic and necrotizing enteritis with viral antigen in endothelial cells, as well as multifocal splenic necrosis. The seagull displayed pulmonary and pancreatic necrosis, with viral antigen in pancreatic cells. The cattle egret exhibited a generalised mild vasculitis; viral antigen was not detected in any organ by immunohistology.

Conclusions

Our findings align with the reported increase in natural HPAI infections in these taxa. The widespread haemorrhagic enteritis due to HPAI is reported infrequently, so it must be considered in the differential diagnoses.

Poster Abstracts Veterinary Pathology

EXOTIC, WILDLIFE AND NON-HUMAN PRIMATES

186 | SEPTICAEMIA IN TWO PYGMY MARMOSETS (*CEBUELLA PYGMAEA*) ASSOCIATED WITH *KLEBSIELLA PNEUMONIAE*

L. Fuentes^{*,†}, B. Serrano[†], H. Fernández-Bellón^{*}, V. Almagro^{*}, J. Alomar[†] and M. Domingo^{†,‡}

^{*}Parc Zoològic de Barcelona, Parc de la Ciutadella s/n, 08003 Barcelona, [†]Servei de Diagnòstic de Patologia Veterinària (SDPV), Departament de Sanitat i Anatomia Animals, Facultat de Veterinària, Campus UAB, Travessera dels turons s/n, 08193 Bellaterra (Barcelona) and [‡]Centre de Recerca en Sanitat Animal (CRESA), IRTA, Campus UAB, 08193 Bellaterra (Barcelona), ES

Introduction

Several cases of *Klebsiella pneumoniae* infection have been reported in different species of captive primates. Here we describe the pathological outcome of *K. pneumoniae* infection in two pygmy marmosets.

Materials and Methods

Within a period of one week, two pygmy marmosets from a family group of 8 animals in the zoo of Barcelona died suddenly. We conducted an exhaustive postmortem examination of each animal.

Results

Grossly, the first animal showed a fibrinosuppurative peritonitis. The second individual presented a 1 cm focal rounded ulcerative skin lesion at the right shoulder (compatible with a rodent bite wound), haemoperitoneum and diffuse hepatic lipidosis with multifocal liver fissures. Histologically, the first marmoset showed an intense diffuse lymphoplasmacytic and less neutrophilic and histiocytic enteritis and a fibrinosuppurative peritonitis. Both lesions were associated with the presence of abundant bacillary bacteria forming a biofilm that adhered to mucosa, submucosa and serosa. The second animal had a granulomatous splenitis. In both cases, abundant Gram-negative bacteria were present within the lumen of blood vessels of different calibre. The PAS reaction was negative. The bacteriological examination of the livers, one of which had been frozen, isolated *K. pneumoniae*. In one case, the hypermucoviscous phenotype was detected (positive string test).

Conclusions

The lesions in both pygmy marmosets were similar to those described in other primate species. We suspect that rodents may have played a major role in the origin of the infection because simultaneously, a rodent infestation occurred in the enclosure.

Poster Abstracts Veterinary Pathology

EXOTIC, WILDLIFE AND NON-HUMAN PRIMATES

187 | PRIMARY LUNG ADENOCARCINOMA IN A LION (PANTHERA LEO)

R. Pop*, **A.F. Tăbăran***, **A. Negoescu***, **I. Constantin***, **D.L. Hodor***, **G. Deak†** and **C. Cătoi***

**Department of Veterinary Pathology and †Department of Veterinary Parasitology, Faculty of Veterinary Medicine, University of Agricultural Sciences and Veterinary Medicine, Cluj-Napoca, RO*

Introduction

Primary lung adenocarcinoma is a poorly known and rare condition in wild felines, with only a few reported cases in the literature.

Materials and Methods

A fifteen-year-old male African Lion (*Panthera leo*) was euthanized due to chronic respiratory distress and severe emaciation. Following a complete autopsy, multiple organs were harvested and routinely processed for histological examination.

Results

Grossly, a 7 x 7 cm dense, focally necrotic mass was identified within the cardiac lobe of the left lung, associated with severe multifocal bullous emphysema (occupying 20% of the lung parenchyma). Within the pleural cavity, bilateral hydrothorax (500 ml) and multifocal carcinomatosis covering the parietal pleural and cranial mediastinum were observed. Histologically, within the lungs, there were multifocal to coalescing neoplastic masses composed of epithelial cells arranged in a predominantly tubular-papillary pattern, supported by small amounts of fibro-vascular stroma. Lining the tubular spaces, there were two to three layers of cuboidal to columnar neoplastic cells with moderate to marked polymorphism, showing a mitotic index of 10 mitoses/high power fields. By IHC, the tumour cells were positive for pan-cytokeratin and TTF1 and largely negative for vimentin. A diagnosis of pulmonary adenocarcinoma was made.

Conclusions

Primary lung adenocarcinoma is rarely diagnosed in felines. Most cases are seen in cats, where lung adenocarcinomas account for approximately 0.69% of all neoplasias. In wild cats reports are limited to ocelot and tiger. Primary lung adenocarcinoma should be considered as a potential cause of thoracic carcinomatosis in lions as well as in other wild felines.

Poster Abstracts Veterinary Pathology

EXOTIC, WILDLIFE AND NON-HUMAN PRIMATES

199 | NEMATODE INFESTATION IN THREE HARBOUR PORPOISES (*PHOCOENA PHOCOENA*) ON THE BLACK SEA COAST OF ROMANIA

M.A. Minea*, R.I. Rizac*, C. Timoffe†, R.M. Paiu†, M. Militaru*, G. Nicolae*, A. Neagu‡ and T. Soare*

*Pathology and †Mare Nostrum NGO, Constanta, RO and ‡Radiology, University of Agronomic Sciences and Veterinary Medicine of Bucharest, Faculty of Veterinary Medicine, Bucharest, RO

Introduction

Conservation efforts for the cetacean population are conducted every year on the Black Sea coast of Romania, and studies on cetacean diseases are crucial in identifying possible threats to the marine population. Here we report the pathological findings in three *Phocoena phocoena* stranded on the Black Sea coast of Romania. The study's main goal was to identify possible threats to the cetacean population and assess their implication in the stranding events.

Materials and Methods

The study material is represented by three *Phocoena phocoena* specimens stranded on the Black Sea Coast of Romania. Animals had been frozen and thawed. CT scans and complete necropsies were performed, with macroscopical assessment of cavities and organs. Histological specimens and parasitology samples were collected following the protocol for marine mammals and a standard staining technique was used (HE).

Results

The CT scan showed a modified density of the internal ear in all three cetaceans. They also had in common a pulmonary nematode infestation, that caused pulmonary lesions including verminous pneumonia, catarrhal pneumonia, emphysema, and oedema. Two specimens exhibited massive nematode infestation in the internal ear obvious after opening of the tympanic bulla. Other identified lesions were gastric and intestinal haemorrhage, reactive lymph node hyperplasia, panniculitis, epidermal hyperplasia, dermal fibrosis, and gastric nematode infestation.

Conclusions

The results contribute significantly to the collected data on cetaceans from the Black Sea coast of Romania. The lesions and the abundance of the parasites certainly play a significant role in the cetacean strandings.

Poster Abstracts Veterinary Pathology

EXOTIC, WILDLIFE AND NON-HUMAN PRIMATES

211 | COMPREHENSIVE PATHOLOGICAL ANALYSIS OF NORTHERN WHITE-BREADED HEDGEHOG (*ERINACEUS ROUMANICUS*): INSIGHTS INTO HEALTH AND DISEASE

E. Gagniuc^{*†}, O.C. Vasiliu[‡], A.I. Anton^{*}, G.L. Nicolae^{*}, G. Dinescu^{*} and M. Ionita[‡]

^{}Department of Pathology and Forensic Medicine, University of Agronomic Sciences and Veterinary Medicine of Bucharest and [†]Pathology Department, Synevovet Laboratory, Bucharest, RO and [‡]Department of Parasitology - Parasitic Diseases and Animal Biology, University of Agronomic Sciences and Veterinary Medicine of Bucharest, RO*

Introduction

The Northern White-Breasted hedgehog (*Erinaceus roumanicus*) is a nocturnal mammal found in Eurasia, including Romania. While studies on the Western European hedgehog (*Erinaceus europaeus*) are abundant, there is limited information on the pathological changes in *E. roumanicus*. Here we describe the macroscopic and microscopic lesions observed during post-mortem examinations of *E. roumanicus*, contributing to our understanding of hedgehog diseases.

Materials and Methods

Nine adult specimens, originating from different regions of Romania, were examined. After death, post-mortem examinations were performed. During necropsy, following gross examination of each organ, samples from representative areas were collected, fixed in 10% formalin, routinely paraffin embedded, sectioned and stained with hematoxylin-eosin (HE).

Results

On gross examination, ectoparasites (Ixodidae Family) were identified in two individuals. All animals had pulmonary congestion, pulmonary oedema and massive parasitic infestation with nematodes (*Capillaria erinacei*, *Crenosoma striatum*). In the intestine, catarrhal and haemorrhagic enteritis and massive cestode infestation (*Hymenolepis erinacei*) were observed. Histologically, all individuals exhibited pulmonary oedema, vasculitis and diffuse bronchointerstitial pneumonia. Severe inflammatory changes were noted in the intestine, characterized by eosinophilic infiltrates and, at times, with numerous epithelioid and foreign body multinucleated giant cells (granulomatous inflammation).

Conclusions

All examined individuals of *E. roumanicus* species showed, both macroscopically and microscopically, severe pulmonary and digestive inflammatory lesions, primarily caused by endoparasite infestation. This demonstrates that the death of the examined animals was due to severe parasitism, which secondarily caused dysfunction and multisystem failure. Understanding hedgehog diseases and their pathological manifestations is crucial for their conservation and management.

Acknowledgements: We thank the "Visul Luanei" Foundation for the support given in the realization of this study.

Poster Abstracts Veterinary Pathology

EXOTIC, WILDLIFE AND NON-HUMAN PRIMATES

213 | ORAL MELANOMA IN A RED FOX (*VULPES VULPES*)

A. Gonçalves*, **J. Requicha†:‡** and **M.A. Pires†:‡**

**Stapeley Grange Wildlife Centre & Cattery, Royal Society for the Prevention of Cruelty to Animals (RSPCA), Nantwich, GB and †Animal and Veterinary Research Centre (CECAV), University of Trás-os-Montes e Alto Douro and Associate Laboratory for Animal and Veterinary Science (AL4Animals) and ‡Department of Veterinary Sciences, University of Trás-os-Montes e Alto Douro, Vila Real, PT*

Introduction

Oral melanoma has been reported in several mammalian species, including companion animals (dog, cat, and ferret), and in the African lion. To our knowledge, there are no reported cases of oral malignant melanoma in the red fox (*Vulpes vulpes*).

Materials and Methods

An adult female red fox was admitted to the RSPCA Stapeley Grange Wildlife Centre and presented with severe lethargy. Physical examination revealed emaciation, pale mucous membranes, hypothermia, and no lymphadenopathy. As part of a general triage, an oral cavity assessment was performed, revealing multiple missing teeth, tooth fractures and wear, and stomatitis. A dark-coloured, 5x3 cm, sessile and asymmetrical mass involving mostly the right side of the soft palate, caudal hard palate, glossopalatine arch, and fauces was identified. Taking into consideration all the above findings and the old age of the individual, euthanasia was performed and samples from the oral mass and the surrounding tissue, lungs, and submandibular lymph nodes were submitted to histopathological evaluation.

Results

Histological examination of the oral mass revealed large amounts of cells with dark pigment in the cytoplasm, masking the cellular and nuclear morphology, identified as melanin after bleaching, and positive in the Masson Fontana stain. These cells invaded neighbouring salivary glands, muscle and regional lymph nodes. A diagnosis of oral melanoma with invasion of adjacent tissues was made.

Conclusions

This is the first report of oral melanoma in a non-captive red fox (*Vulpes vulpes*), highlighting the importance of systematic evaluation of the oral cavity during the screening of wild animals.

Acknowledgements: This work was financed by the Portuguese Foundation for Science and Technology, within the scope of the projects UIDB/CVT/00772/2020 (CECAV) and LA/P/0059/2020 (AL4Animals) and by CEECINS/00127/2018.

Poster Abstracts Veterinary Pathology

FISH PATHOLOGY

57 | WILD FISH PARASITES CONTROL IN FISHERY PRODUCTS

P. Ramos

Pathology Laboratory of Aquatic Animals, Portuguese Institute for the Ocean and Atmosphere, IPMA, I.P., Av. Doutor Alfredo Magalhães Ramalho, 6., 1495-165 Algés, PT and CIIMAR, Interdisciplinary Centre of Marine and Environmental Research, University of Porto, Rua dos Bragas 289, 4050-123 Porto, PT

Introduction

The presence of parasites in fishery products threatens their safety and quality and may represent a consumer health hazard. Monitoring parasites in fishery products is fundamental to avoid commercialising contaminated fishery products.

Materials and Methods

A total of 1216 samples of seafood products, whole fish, fish steaks, fish fillets, fish fingers, ray wings and shredded fish, from the Portuguese markets were analysed. External surface, internal organs, visceral cavity and muscle were visually inspected for detection of parasites. The fish muscle was submitted to the candling method and artificial digestion. Wet mount preparations of muscle were microscopically examined. The collected parasites were identified, and their viability evaluated. The occurrence, distribution and viability of the parasites were reported.

Results

Viable Anisakis and Pseudoterranova L3 larvae were retrieved from different fish samples, although live larvae were only found in fresh fish. In addition, the nematodes *Huffmanella lusitana* and *Philometra* sp.; cestodes, pleurocercoids of *Gymnorhynchus gigas* and *Hepatoxylon trichiuri*; crustacean copepods, *Pennella instructa* and *Lernaeocera branchialis*; mixosporean spores of *Kudoa* sp., *Kudoa thyrsites* and *Henneguya salminicola*; microsporidean *Spraguea americana*, *Spraguea lophii*, and *Dasyatispora levantinae* were also detected.

Conclusions

Commercially valuable fish are placed on the market as fresh fishery products and may contain parasites. If these parasites are macroscopically apparent in fishery products, it will lead to their withdrawal with consequent economic losses. On the other hand, L3 Anisakis larvae have been reported as zoonotic parasites, and the prevention of human infection (anisakiasis) is based on the monitoring work of the fishery products.

Acknowledgements: This work was supported by SANAQUA project MAR-02.05.01-FEAMP-0004.

Thanks also are due to FCT/MCTES for the financial support to CIIMAR (UIDB/04423/2020 and UIDP/04423/2020).

Poster Abstracts Veterinary Pathology

FISH PATHOLOGY

58 | COMPARATIVE PARASITOLOGICAL STUDIES OF CULTURED GILTHEAD SEABREAM, SPARUS AURATA AND EUROPEAN SEABASS, DICENTRARCHUS LABRAX IN PORTUGUESE FISH FARMS

P. Ramos^{*†}, I. Pinto[‡] and M.M. Oliveira^{§¶}

^{}Pathology Laboratory of Aquatic Animals, [†]Portuguese Institute for the Ocean and Atmosphere, IPMA, I.P., Av. Doutor Alfredo Magalhães Ramalho, 6, and [‡]CIIMAR, Interdisciplinary Centre of Marine and Environmental Research, University of Porto, Rua das Bragas 289, 4050-123 Porto, PT, [§]Pathology Laboratory of Aquatic Animals, [¶]Portuguese Institute for the Ocean and Atmosphere, IPMA, I.P. Av. Doutor Alfredo Magalhães Ramalho 6, 1495-165 Algés, PT, [¶]Portuguese Institute for the Ocean and Atmosphere, IPMA, I.P. Av. Doutor Alfredo Magalhães Ramalho 6, 1495-165 Lisboa, PT and [¶]3 Lusófona University, ECEO, Campo Grande 376, 1749-024 Lisboa, PT*

Introduction

The gilthead seabream (*Sparus aurata*) and European seabass (*Dicentrarchus labrax*) are two of the most important fish commonly cultured in the Mediterranean area. Consequently, disease outbreaks have significant effects on commercial production. This study identified and compared the parasitic infection rates of gilthead seabream and European seabass from semi-intensive Portuguese fish farms in 2014 and 2023.

Materials and Methods

Parasitological examinations were conducted on 271 fishes (138 seabass and 133 gilthead seabream) from semi-intensive fish farms. The body surface and gills of the fish were examined for ectoparasites, and the visceral cavity and internal organs for nematodes. Prevalence, abundance and mean intensity were calculated. Descriptive statistics were performed for each sampling site.

Results

There were no significant statistical differences between samples and sampling sites. Three classes of parasites were found attached to the gills of the European seabass or gilthead seabream, namely the copepod crustaceans *Lernanthropus kroyeri* and *Caligus* sp., the gnathiid isopod *praniza*; the protozoan *Trichodina* sp., and the monogenean species *Diplectanum aequans*, *Dactylogyrus* sp., *Sparocotyle chrysophrii* and *Furnestinia echeneis*. In the 2023 samples, two new species of Monogenea were identified in both gilthead seabream and European seabass.

Conclusions

Three possible ways of infection of fish in semi-intensive farms can be pointed out: a) infected fingerlings stocks were used to stock uninfected ponds; b) the characteristics of the production systems that make use of the tides for water renewal; c) the environmental conditions, namely the increase in water temperature that directly influences the parasite fauna of fishes.

Acknowledgements: This work was supported by SANAQUA project MAR-02.05.01-FEAMP-0004.

Thanks also are due to FCT/MCTES for the financial support to CIIMAR (UIDB/04423/2020 and UIDP/04423/2020).

Poster Abstracts Veterinary Pathology

FISH PATHOLOGY

209 | MICROSCOPIC EXAMINATION OF THE TISSUES FROM WILD BROWN TROUT WITH ULCERATIVE DERMAL NECROSIS SYNDROM (UDN) CAUGHT IN THE SŁUPIA RIVER IN POLAND

A. Kycko*, **M. Wasiak†**, **M. Stachnik‡**, **M. Matras‡** and **M. Reichert†**

**Department of Pathology, National Veterinary Research Institute and †Department of Pathology and ‡Department of Fish Diseases, National Veterinary Research Institute, Puławy, PL*

Introduction

Ulcerative dermal necrosis (UDN), a disease of unclear pathogenesis, has been repeatedly reported in recent years in brown trout migrating from the Baltic Sea into Polish fresh water. Here we present the microscopic features in the tissues of UDN-affected wild sea trout spawners caught in the Słupia River in Poland in 2021 and 2022.

Materials and Methods

Formalin-fixed paraffin-embedded (FFPE) tissue sections from skin, spleen, and liver of wild spawners, negative for known salmonid viruses, caught in 2021 (n=5) and 2022 (n=8) and archival FFPE tissues from experimentally immunosuppressed farmed sea trout (n=5) which developed UDN lesions while cohabited with UDN-affected wild spawners were subjected to histopathological examination using HE staining. Glutaraldehyde-fixed sections from the ulcers and normal-looking skin were subjected to scanning electron microscopy (SEM).

Results

Histopathological lesions included disruption of the epidermal layer with the occasional presence of fungal hyphae penetrating the epidermis and necrotic dermis in all cases. In the 2022 cases, there was also prominent lymphocytic infiltration of the dermis with minor fungal involvement plus periportal lymphocytic infiltrations in one liver. Other than that no changes were found in the liver and spleen. Degeneration of the skin penetrated by fungi was evident in SEM examination.

Conclusions

The pathological changes in the majority of the cases seemed to be associated with fungal infections, limited to the skin, which has been reported in previous years in salmonids. The increased intensity of the changes in the trouts from 2022 might indicate a more complex pathogenesis of the disease.

Acknowledgements: Financial support was granted by National Science Centre, Kraków, Poland, 2019/33/B/NZ6/0292

Poster Abstracts Veterinary Pathology

FORENSIC MATTERS

204 | RETROSPECTIVE STUDY OF FORENSIC NECROPSIES PERFORMED AT THE FACULTY OF VETERINARY MEDICINE OF THE UNIVERSITY OF LISBON BETWEEN 2014-2022

M.I. Rafael^{*.†}, R. Noiva^{*.†}, F. Afonso^{*.†}, J. Ferreira da Silva^{*.†}, M.C. Peleteiro^{*.†}, A. Moreira^{‡.†}, J. Correia^{*.†} and H. Pissarra^{*.†}

^{}Pathology and [†]Pathology, Associate Laboratory for Animal and Veterinary Sciences (AL4Animals) and [‡]Pharmacology and Toxicology, CIISA-Centre for Interdisciplinary Research in Animal Health, Faculty of Veterinary Medicine, University of Lisbon, Lisbon, PT*

Introduction

In Portugal, the abuse of companion animals has been considered a crime since 2014, when Law 69/2014 was implemented.

Materials and Methods

In order to better understand and characterize animal-related crimes in the jurisdictional region which this laboratory serves, a retrospective study of all forensic cases examined by the Anatomic Pathology Service of the Faculty of Veterinary Medicine, University of Lisbon between 2014-2022 was conducted.

Results

A total of 406 forensic necropsy reports were analysed, of which 138 (34%) were compatible with non-accidental/violent death. Of these, 102 (73.9%) were dogs, 30 (21.7%) involved cats, 1 (0.7%) was a horse and the remaining 5 (3.6%) involved various animals of the local wildlife fauna. Males were overrepresented (85/138, 61.6%). Most common cause of death was trauma (85/138, 61.6%) - mainly blunt force trauma (51/85, 81%) - and poisoning (47/138, 34.1%). In 124 cases (124/406, 30.5%), neglect was the main initial suspicion, including omission of care, abandonment or animals found dead without identification.

Conclusions

The number of cases reported shows that violence against animals is a reality in Portugal, and the number of complaints registered suggests growing awareness of the society regarding animal cruelty. Cooperation between law enforcement, veterinary pathologists and clinicians is an important support base in these legal cases, and the continuing improvement of the law to accommodate the country's reality and the reinforcement of the resources available are fundamental to protect this growing social priority.

Acknowledgements: Funding UIDB/00276/2020 e LA/P/0059/2020

Poster Abstracts Veterinary Pathology

FORENSIC MATTERS

220 | FORENSIC ANALYSIS OF FATALITIES WITH SUSPECTED COMPANION ANIMAL CRUELTY INVOLVING TOXIC SUBSTANCES

K. Lee, J. Kang, A. Kim, N. Moon, B. Ku, S. Kim and M. Lee

^{}Animal Disease Diagnostic Division, Animal and Plant Quarantine Agency, and [†]Forensic Toxicology Division, National Forensic Service, Republic of Korea*

Introduction

Animal abuse is a severe problem in South Korea, with numerous pets being endangered in terms of their health and safety. The number of annual requests for animal abuse-related tests has been increasing by more than 150% every year during 2019-2022, with Seoul, Incheon, and Gyeonggi regions having the highest number of requests, likely due to their high population densities. Here we report the results of toxicity tests conducted on dogs and cats in this time period.

Materials and Methods

National forensic science conducted drug toxicology tests on samples collected from 549 dogs and cats that had been subjected to a forensic post mortem examination. Using gas chromatography/mass spectrometry and liquid chromatography/mass spectrometry, the following substances were tested investigated: cyanates, organophosphorus, organochlorine carbamates, salicylates, barbitalic acid derivatives, benzodiazepine derivatives, salicylates and other alkaloids.

Results

A total of 38 types of toxic substances were identified. Pesticides and drugs used for insecticides, pain relief, anesthesia, anxiety, and muscle spasms were among the most commonly detected substances, with Coumatetralyl, Methomyl, Terbufos, and Bupropion being the most frequently detected. Grossly, all cases of Coumatetralyl poisoning showed pulmonary or subcutaneous haemorrhages. Histopathologically, in some cases of pesticide poisoning pulmonary haemorrhage and interstitial oedema and liver necrosis were seen.

Conclusion The identified substances are highly toxic and potentially lethal for pets. In many examined cases, pesticide and rodenticide poisoning was the primary cause of death. With 70 cases (12.8%), the detected animal poisoning rate was 3.4 times higher than the rate of human poisoning (about 3.3%) in Korea.

Poster Abstracts Veterinary Pathology

FORENSIC MATTERS

221 | CURRENT STATUS OF VETERINARY FORENSIC EXAMINATION FOR COMPANION ANIMALS IN KOREA

K. Lee, A. Kim, N. Moon, B. Ku and M. Lee

**Animal Disease Diagnostic Division, Animal and Plant Quarantine Agency, and †Forensic Toxicology Division, National Forensic Service, Republic of Korea*

Introduction

The recent amendments to the Animal Protection Act in South Korea not only significantly increased the penalties for animal cruelty, but also provided legal grounds for requesting a “veterinary forensic examination” which is essential for scientific proof of animal cruelty.

Materials and Methods

Post mortem examinations performed between 2019 to 2022 on 549 dogs and cats suspected to have died due to animal cruelty and referred to the APQA were analyzed based on the forensic diagnoses made. Gross lesions, pathogen testing, drug testing, and histopathological examinations were the basis for the diagnoses.

Results

Forensic examinations progressively increased in number, especially in 2021. On the basis of the forensic examination, we distinguished natural (36.3%) and non-natural (by external cause; 54.2%) death and cause of death unknown (9.5%). The most frequent non-natural cause of death in dogs was poisoning (41.3%) and blunt force trauma (27%), followed by starvation and malnutrition (11.1%). In cats, the most common cause of death was blunt force trauma (64.6%) and poisoning (11.5%), followed by bite injury by animals (11.1%). Generally, only one type of abuse was identified for each case.

Conclusion Having undertaken the first study that focuses on the analysis of forensic cases of suspected dog and cat abuse in South Korea, our main goal was to share our results with veterinary pathologists who can accurately recognize signs of animal abuse and are thereby able to deal with cases of companion animal cruelty in the appropriate way.

Poster Abstracts Veterinary Pathology

LIVESTOCK

30 | FIRST DETECTION OF SYSTEMIC PORCINE CIRCOVIRUS 3 ASSOCIATED DISEASE IN SWITZERLAND

G. Rosato*, **F. Seehusen***, **J. Segalés†‡**, **M. Sibila†§**, **A. Cobos†§** and **R. Graage¶**

**Institute of Veterinary Pathology, University of Zurich, Zurich, CH, †Unitat mixta d'Investigació IRTA-UAB en Sanitat Animal, Centre de Recerca en Sanitat Animal (CReSA), Campus de la Universitat Autònoma de Barcelona (UAB), Barcelona, ES, ‡Departament de Sanitat i Anatomia Animals, Facultat de Veterinària and §IRTA Programa de Sanitat Animal, Centre de Recerca en Sanitat Animal (CReSA), Campus de la Universitat Autònoma de Barcelona (UAB), Bellaterra, ES and ¶Qualiporc Cooperative, Appenzell, CH*

Introduction

Circoviruses are single-stranded DNA viruses that infect a wide spectrum of animals. In pigs, four different circoviruses have been identified. Porcine circovirus 3 (PCV-3), first reported in 2015, has been detected worldwide in pigs with or without clinical signs. However, the knowledge on clinicopathological and epidemiological aspects of PCV-3 infection and the pathogenic effect of the virus is limited.

Materials and Methods

In March 2023, a Swiss breeding farm reported an increase in spinal malformations, thickened ribs and facial oedema with otherwise unremarkable clinical condition in suckling piglets and weaners. Three 4- to 6-week-old piglets were euthanised and submitted for diagnostic examination. A full necropsy and histological examination as well as a qPCR and in situ hybridisation (ISH) for PCV-3 were performed.

Results

Grossly, all animals exhibited multiple rib fractures with callus formation; one pig also showed facial oedema. Histologically, the costal periosteal arteries exhibited lymphoplasmacytic and histiocytic infiltrates. Similar peri- and arterial changes were observed in several organs including facial skin, heart, kidney, mesentery, spleen, lymph nodes, liver, lung, nasal mucosa and skeletal muscles. The qPCR for PCV-3, advised by the histological features, revealed a systemic PCV-3 infection with high viral loads. ISH detected abundant viral genome expression in multiple organs, including the bones.

Conclusions

This is the first report on PCV-3 infections in Switzerland. It is also the first to detect the virus in bone lesions. In future, pathomorphological investigations and possible detection of PCV-3 is advisable in pigs displaying bone lesions similar to those reported here.

Poster Abstracts Veterinary Pathology

LIVESTOCK

42 | DELAYED VIRUS CLEARANCE AFTER RECOVERY FROM AFRICAN SWINE FEVER-A CHALLENGE FOR DISEASE CONTROL AND MONITORING

K. Mehinagic^{*†}, E. Radulovic^{*†}, H. Posthaus[‡], A. Summerfield^{*}, C. Benarafa^{*} and N. Ruggli^{*}

^{}Department of Infectious Diseases and Pathobiology, Vetsuisse-Faculty, Institute of Virology and Immunology IVI, Mithelhäusern, CH and [†]University of Bern, Graduate school for cellular and biomedical sciences GCB and [‡]Department of Infectious Diseases and Pathobiology, Vetsuisse-Faculty, Institute of Animal Pathology ITPA, Bern, CH*

Introduction

African Swine Fever (ASF) is a devastating viral disease affecting domestic pigs and wild boars worldwide. Since its re-emergence in Europe in 2007, the disease has spread across large parts of Europe and Asia, causing massive economic losses for the pig industry. In both domestic pigs and wild boars ASF is typically lethal but clinical signs can vary depending on virus strain and host factors. The causative agent, African swine fever virus (ASFV), is a large double-stranded DNA virus with 24 known genotypes and different strains of varying pathogenicity.

Materials and Methods

Here, we report the gross pathological findings and virus quantification from several experimental infections with two highly virulent (Armenia 2008, Georgia 2007) and one moderately virulent (Estonia 2014) isolates in both regular farm pigs and SPF pigs.

Results

Regardless of the route of infection, the two highly virulent strains caused death of all animals within 6-8 days after infection, with classical pathologic lesions including splenomegaly, haemorrhagic lymph nodes and pleural and pericardiac effusions. The infection with Estonia 2014 resulted in 50% lethality, with the classical pathological lesions in animals that succumbed to the disease. Interestingly, the organs of the animals that recovered from ASF showed no visible lesions at day 28 post infection but still exhibited remarkably high viral loads.

Conclusions

The results highlight the need for continued monitoring and targeted surveillance strategies to effectively mitigate the risk of ASFV transmission, especially in regions where outbreaks of the disease have occurred.

Poster Abstracts Veterinary Pathology

LIVESTOCK

46 | TORQUE TENO SUS VIRUS: AN INNOCENT BYSTANDER OR A TRUE EMERGING VIRUS PATHOGEN IN SWINE FARMS?

M. Polinas*, **S. Hawko***, **S. Dei Giudici†**, **P.P. Angioi†**, **A. Alberti***, **E. Antuofermo***, **A. Oggiano†** and **G.P. Burrari***

**Department of Veterinary Medicine, University of Sassari and †Department of Animal Health, Istituto Zooprofilattico Sperimentale della Sardegna, Sassari, IT*

Introduction

Torque teno sus virus (TTSuV, Anelloviridae) is a non-enveloped circular ssDNA virus detected in pigs worldwide and suspected to be involved in several swine diseases as a primary or as opportunistic pathogen. This work aimed at detecting TTSuV in different swine age categories from an intensive pig farm in Sardinia (Italy) with respiratory signs including dyspnea.

Materials and Methods

Tissue samples from the lung, heart, liver, spleen, kidney, intestine, mediastinal, and mesenteric lymph nodes of 10 adult pigs, 10 post-weaning pigs, and 9 piglets were macroscopically and histologically evaluated. RT-PCR was performed to detect TTSuV and Sanger sequencing to characterize viral strains in a subset of samples.

Results

TTSuV was detected in 100% of swine with higher viral loads in adults compared to post-weaning and piglets, and lowest mean cycle thresholds in lungs and spleen ($P < 0.05$). TTSuV1 and TTSuV2k strains were identified. Sanger sequencing of TTSuV1-positive samples showed the highest homology with strains detected in Brazil and South Korea, while TTSuV2k was 98% similar to strains isolated in China. Histologically, infected animals showed moderate diffuse chronic histiocytic and lymphoplasmacytic interstitial pneumonia in 60% of adults, in 100% of post-weaning, and in 100% of piglets. Other tested viruses, including PCV2 and PRRSV, were detected with low viral loads.

Conclusions

The results indicate that TTSuV may play a role in lung swine disease, but further studies are needed to clarify if this Anellovirus represents an innocent bystander or plays a synergistic role with other swine pathogens.

Poster Abstracts Veterinary Pathology

LIVESTOCK

49 | INTRALESIONAL NON-ACID-FAST MYCOBACTERIUM BOVIS PHENOTYPES IN THE LYMPH NODES OF NATURALLY-INFECTED CATTLE

C. Pigoli*, **E. Brambilla†**, **L.R. Gibelli***, **G.L. Alborali***, **M.G. Zanoni***, **M.B. Boniotti***, **F. Prisco‡** and **V. Grieco†**

**Istituto Zooprofilattico Sperimentale della Lombardia e dell'Emilia-Romagna, Brescia, IT, †Dipartimento di Medicina Veterinaria e Scienze Animali, Università degli Studi di Milano, Lodi, IT and ‡Dipartimento di Medicina Veterinaria e Produzioni Animali, Università degli Studi di Napoli Federico II, Napoli, IT*

Introduction

In human tuberculosis (TB), dormant mycobacteria, which are non-acid-fast (AF) bacilli with reduced metabolism and multidrug resistance, have been associated with the latent form of the disease. So far, the presence of intralesional non-AF mycobacteria in bovine TB (bTB) has been poorly investigated. The objective of this study was to investigate the presence of intralesional non-AF *Mycobacterium bovis* (M.bovis) phenotypes in lymph nodes (LNs) of naturally infected cattle.

Materials and Methods

Two hundred and fifty formalin-fixed and paraffin-embedded LNs from cattle with confirmed M. bovis infection were evaluated. Of these, LNs containing at least one granuloma with more than 20 AF bacilli were subjected to a protocol involving photobleaching treatment and enzymatic antigen unmasking, followed by combined Auramine-O immunofluorescence (AO-IF) staining. Negative controls included a bovine lung with *Trueperella pyogenes* (a non-AF bacterium)-induced lesions and a microbiologically negative calf lymph node.

Results

Of the 250 LNs, twenty-four were selected for the combined AO-IF staining, and non-AF (AO-IF+) bacilli were identified in all of them. Specifically, numerous non-AF bacilli were detected in the necrotic core of the granulomas, while rare non-AF bacilli were occasionally visible inside Langhans-type multinucleated giant macrophages.

Conclusions

This study demonstrates the presence of intralesional non-AF M. bovis phenotypes in the LNs of naturally infected cattle, providing new insights into bTB pathogenesis. Further research is needed to understand the significance of non-AF bacilli phenotypes in the context of bovine TB, their potential impact on public health, and the potential role of bTB in studying latent human TB.

Poster Abstracts Veterinary Pathology

LIVESTOCK

64 | DISCOVERY OF A NOVEL PORCINE BASTROVIRUS ASSOCIATED WITH NON-SUPPURATIVE ENCEPHALITIS IN PIGS

N. Wildi*, **S. Bagatella†,***, **K. Dawson***, **C. Gurtner†** and **T. Seuberlich***

**Division of Neurological Sciences, Department of Clinical Research and Veterinary Public Health and †Institute of Animal Pathology, Department of Infectious Diseases and Pathobiology, Vetsuisse Faculty, University of Bern, Bern, CH*

Introduction

Non-suppurative meningoencephalitis in pigs is often caused by viral infections. Three growing-finisher pigs from two farms showing neurological signs were submitted for post-mortem examination. Histopathological examination revealed a severe lympho-histiocytic meningoencephalomyelitis. Further PCR testing failed to identify any routinely tested virus as the cause of the meningoencephalitis. The study aimed to resolve the cause of the non-suppurative meningoencephalomyelitis through a high-throughput sequencing approach, since the histopathological pattern was consistent with a viral infection.

Materials and Methods

We extracted RNA from fresh brain tissue of the affected pigs and subjected it to high throughput sequencing. After obtaining a complete bastrovirus genome, we used this data to design a probe for in situ hybridization (ISH).

Results

Histopathological examination revealed a severe non-suppurative meningoencephalomyelitis extending from the spinal cord to the cerebrum in all three pigs. The grey matter was mainly affected. Sequencing revealed the sequence of a small virus with similarities to hepeviruses for the open reading frame (ORF) 1 and similarities to astroviruses for the ORF2, which is a feature of bastroviruses. ISH staining showed viral RNA within a few neurons in the spinal cord of all pigs.

Conclusions

Our study demonstrates the presence of a porcine bastrovirus in neurons of the CNS in combination with non-suppurative meningoencephalitis in three pigs. Bastroviruses are found in human and porcine faecal samples. To date, no association with disease has been described. However, the similar hepeviruses and astroviruses are known to cause non-suppurative encephalitis, especially in immunocompromised individuals.

Poster Abstracts Veterinary Pathology

LIVESTOCK

94 | STRAIN DIVERSITY IN CAPRINE PARATUBERCULOSIS-CORRELATION OF MYCOBACTERIUM AVIUM SSP. PARATUBERCULOSIS GENOTYPES WITH MORPHOLOGICAL LESIONS

M. Rasper-Hössinger^{*}, S. Scherrer[†], R. Stephan[‡] and F. Seehusen^{*}

^{}Institute of Veterinary Pathology, [†]Institute for Food Safety and Hygiene, Section of Veterinary Bacteriology and [‡]Institute for Food Safety and Hygiene, Vetsuisse Faculty, University of Zurich, Zurich, CH*

Introduction

Paratuberculosis is an infection with *Mycobacterium avium* ssp. *paratuberculosis* (MAP) causing chronic enteritis in domestic ruminants worldwide. In goats, paratuberculosis is mainly caused by the C (cattle)-type MAP and to a lesser extent by the S (sheep)-type. We characterised ten Swiss caprine MAP isolates by mycobacterial interspersed repetitive units and variable number tandem repeats (MIRU-VNTR) profiling as well as single nucleotide polymorphism assay (SNP) and correlated these with histological lesions.

Materials and Methods

Testing for MAP was performed by qPCR targeting IS900 and F57. Strain diversity of MAP was determined by applying the MIRU-VNTR typing method to classify different INRA Nouzilly MIRU-VNTR (INMV) profiles. C- and S-type strains were differentiated by SNPs based on PCR and enzymatic restriction. DNA gyrases *gyrA* and *gyrB* were sequenced for differentiation between MAP types I, II, and III. Histological scoring of intestinal lesions was performed as described previously.

Results

All goats showed moderate to severe lymphohistiocytic and plasmacytic mucosal infiltration in duodenum, jejunum and ileum. The Ziehl-Neelsen stain revealed no to moderate numbers of acid-fast bacilli. The histological lesions were scored as diffuse multibacillary/3b or diffuse lymphocytic paucibacillary/3c. MIRU-VNTR profiling identified "new" strains (INMV218/220) and "classic" strains (INMV1), belonging to S- (INMV218/220) and C-types (INMV1), accordingly.

Conclusions

Histological scoring of lesions did not reveal any obvious differences between S- and C-type and INMV strains in Swiss goats. However, detection of MAP by PCR proved to be a reliable approach to the identification of infected animals regardless of the histological lesion type.

Poster Abstracts Veterinary Pathology

LIVESTOCK

96 | INFLAMMATORY CELL PHENOTYPING AND EPITHELIAL PROLIFERATION IN PORCINE LAWSONIA INTRACELLULARIS INFECTION

M. Weber, G. Rosato and F. Seehusen

Institute of Veterinary Pathology, Vetsuisse Faculty, University of Zurich, Zurich, CH

Introduction

Infection of pigs with *Lawsonia intracellularis* (*L. intracellularis*) causes the so-called porcine proliferative enteropathy (PPE), leading to major economic losses worldwide. The main objectives of this retrospective study were to compare the current gold standard detection method of *L. intracellularis* (Warthin-Starry stain) to *L. intracellularis* immunohistochemistry (IHC) and to immunophenotype the intestinal inflammatory infiltrate.

Materials and Methods

Forty-two cases of PPE were selected from the archive. HE-stained intestinal samples were evaluated for presence and distribution of several histological parameters. Furthermore, *L. intracellularis* antigen expression was detected immunohistochemically which allowed a categorisation of animals with low (group 1), moderate (group 2), or high numbers of *L. intracellularis* (group 3). Immunophenotyping of inflammatory cells including regulatory T cells (Tregs) and evaluation of proliferation (Ki67 expression) was performed in selected cases.

Results

Histologically, the hallmark lesion was hyperplasia of crypt enterocytes which was detected in almost every animal. The number of Ki67-positive cells was significantly higher in group 3 compared to group 1 and 2. The major inflammatory cell populations were macrophages and T lymphocytes. Furthermore, a colocalization of *L. intracellularis* antigen and the macrophage marker Iba1 was detected. Tregs were detected in every group in the mucosa (mainly group 1) and in the ileal lymphoid tissue (mainly groups 2 and 3).

Conclusions

The bacterial load correlated with the severity of histological lesions. The immunomodulatory effects of the detected Tregs may affect the proliferation and spread of bacteria.

Poster Abstracts Veterinary Pathology

LIVESTOCK

97 | EVALUATION OF TWO RECOMBINANT VIRAL-VECTORED VACCINES AGAINST ORF VIRUS IN SHEEP

Á. Gómez*, A. Rodríguez-Largo*, I. Echeverría†, L. Puzol†, I. Moncayola†, L. Arriazu†, A. Calero†, E. Pérez*, N. Calvo-Sánchez*, I. Glaria†, M. Nazabal‡, I. Hualde‡, L. Luján* and R. Reina†

*Department of Animal Pathology, University of Zaragoza, Zaragoza, ES and †Institute of Agrobiotechnology, CSIC-Government of Navarra and ‡Navarra Institute of Technology and Food Industry, INTIA, Pamplona, ES

Introduction

Orf virus (ORFV), a member of the genus Parapoxvirus, is the causative agent of Contagious Ecthyma (CE), a disease responsible for severe economic losses in small ruminants worldwide. Mortality rarely exceeds 1% but morbidity may reach 100%. Currently, commercial vaccines are based on attenuated strains of ORFV that elicit short-lived protection and can reverse to virulence, highlighting the need for new vaccine prototypes against this common viral infection. This study evaluated the safety and protective efficacy of two recombinant Sendai virus (rSeV-GFP)-based vectors in sheep after challenge with wild ORFV.

Materials and Methods

Two rSeV-GFP expressing ORFV B2L (rSeV-GFP-B2L) and ORFV 059 (rSeV-GFP-059) proteins were constructed and used in an in vivo challenge. Four groups of 11 adult sheep each were inoculated intranasally with culture media (control group), rSeV-GFP, rSeV-GFP-B2L or rSeV-GFP-059, respectively. In each group, 5/11 sheep were boosted intranasally and 6/11 subcutaneously. Specific ORFV antibody production was evaluated by ELISA based on protein ORFV 109. After immunization, experimental groups were challenged intradermally with wildtype ORFV. Pathologic examinations were performed.

Results

After challenge, anti-ORFV antibodies were exclusively observed in animals inoculated with rSeV-GFP-059. Macroscopic and microscopic results revealed the absence of lesions compatible with CE in animals immunized with rSeV-GFP-059. In contrast, 50% of the control group, 20% of rSeV-GFP group and 63.6% of rSeV-GFP-OB2L group showed CE associated lesions.

Conclusions

rSeV-GFP-059 seems to provide complete protection, likely driven by antibody production, against experimental wildtype ORFV challenge, making it a promising candidate viral vector-based vaccine against ORFV infection.

Acknowledgements: Funded by ECTICONA (PC0080-0081). Government of Navarra.

Poster Abstracts Veterinary Pathology

LIVESTOCK

100 | PINNAL NECROHAEMORRHAGIC DERMATITIS WITH VASCULITIS AND INTRALESIONAL BACTERIA IN RABBITS

G. De Zan*, **G. De Zottis***, **I. Brunner†**, **N. Genero***, **M. Rustico†**, **F. Agnoletti*** and **M. Cocchi***

**Istituto Zooprofilattico Sperimentale delle Venezie and †Cargill s.r.l.-Animal Nutrition, IT*

Introduction

Episodes of peculiar skin lesions targeting the ear pinna have been sporadically recorded in different farms of commercial fattening rabbits. The pinnae appeared as reddish/haemorrhagic, thickened and oedematous with the development, within a few days, of necrosis and pinnal deformation. The aim of the study was to determine the pathomorphological features of these lesions and verify the possible presence of associated bacterial infections.

Materials and Methods

Ten subjects collected during 5 episodes manifested in 3 different farms were submitted for post-mortem examination. Samples of the affected pinnae were submitted to routine histopathological (n=8) and bacteriological (n=9) procedures.

Results

Lesions were bi- or monolateral, affected pinnae showed multifocal to diffuse dark red discolouration. Macroscopically, variably severe inflammatory lesions were seen, including crusts, ulcers and diffuse severe thickening of the pinna due to oedematous, exudative and haemorrhagic changes up to the development of large, sharply demarcated areas of ulceration/necrosis. In 2 subjects this had resulted in dry necrosis with tissue sloughing and distortion of the pinna. Additional findings included mucopurulent oculonasal discharge, purulent otitis, abscesses/cellulitis and (fibrino)purulent (pleuro)pneumonia. Histologically, the main findings were serocellular crusts, pustules, ulcers, heterophilic dermal infiltration with haemorrhages and necrosis, dermal fibrosis and presence of intralesional Gram-negative coccobacilli. In addition, non-leukocytoclastic vasculitis with thrombosis, septic thrombosis, fibrinoid necrosis and occasional perivascular bacterial aggregates was observed. *Pasteurella multocida* was isolated from the affected pinnae and/or from adjacent purulent lesions (7/9).

Conclusions

This peculiar necrohaemorrhagic pinnal inflammation associated with vasculitis may represent an unusual form of cutaneous pasteurellosis.

Poster Abstracts Veterinary Pathology

LIVESTOCK

105 | SWINE CONJUNCTIVITIS DUE TO THE NOVEL SPECIES MYCOPLASMA SP.1654_15 IN ITALY

M. Cornaggia*, **G. De Zan***, **D. Vio***, **M. Ustulin***, **G. Sandri†**, **V. Righetti***, **G. Nai***, **I. Rossi*** and **M. Merenda***

**Istituto Zooprofilattico Sperimentale delle Venezie and †Soc. Ag. La Pellegrina Spa, IT*

Introduction

Conjunctivitis is a common condition in swine herds. Besides the role of irritating environmental substances, it could be a manifestation of ocular infection with *Chlamydia* spp. or *Mycoplasma* (M.) *hyorhinis*, as well as a consequence of respiratory or systemic viral diseases. A novel, highly specialized *Mycoplasma* species closely related to *M. hyorhinis* and tentatively named *Mycoplasma* sp. 1654_15, has recently been associated with episodes of swine conjunctivitis in Germany (Hennig-Pauka et al., 2020). This study investigated *M. hyorhinis* strains previously isolated in clinical conjunctivitis samples in Italy for the presence of this novel species.

Materials and Methods

Five *M. hyorhinis* strains collected in 4 swine herds were submitted to amplification and sequencing of U1-U5 segments of operons *rrnA* and *rrnB* of 16S rRNA genes. In addition, they were also analyzed by the PCR protocol of Hennig-Pauka et al. (2020).

Results

The observed conjunctivitis was bilateral and severe, with oedema and watery/mucous discharge. 16S rDNA product sequencing displayed 99.33% to 99.91% homology with *Mycoplasma* sp. 1654_15 and species identification has been confirmed by PCR.

Conclusions

The results confirm the likely pathogenic role of *Mycoplasma* sp. 1654_15 as a causative agent of conjunctivitis in swine. Given the capacity of a rapid adaptation to new ecologic niches and the parasitic behaviour of mycoplasmas, monitoring is crucial in order to prevent and limit their spread. Being closely related to *M. hyorhinis*, in the case of a rapid diagnostic screening, a specific PCR method would be required to adequately distinguish these two *Mycoplasma* species.

Poster Abstracts Veterinary Pathology

LIVESTOCK

120 | ANTEMORTEM DIAGNOSIS OF CAPRINE PARATUBERCULOSIS BY FAECAL PCR IN RELATION TO HISTOPATHOLOGICAL LESIONS

E. Párraga-Ros^{*}, C. Muñoz-Hernández^{*}, J. Seva^{*†}, A. Buendía^{*}, J. Sánchez^{*} and J.A. Navarro^{*}

^{}Anatomy and Comparative Pathology Department, Mare Nostrum Excellence Campus. University of Murcia and [†]Murcian Institute of Biosanitary Research (IMIB-Arrixaca), ES*

Introduction

Paratuberculosis (PTB) is a widely distributed disease caused by *Mycobacterium avium subsp. paratuberculosis* (Map). The antemortem diagnosis of Map-excreting animals is necessary to control PTB, especially in ruminants, hence a reliable PCR protocol for faeces would be useful. We aimed to determine the PTB prevalence in discarded goats and analyzed the association between faecal PCR and histopathological lesions.

Materials and Methods

Necropsy was performed on 21 goats over 3 years old and faeces, ileocecal valve, terminal ileum, mesenteric and ileocecal lymph nodes were sampled. For histopathological examination, tissue samples were fixed (10% formaldehyde), routinely processed and stained with HE and Ziehl-Neelsen. The histopathological lesions were classified as previously described in the literature. For PCR, DNA was extracted from frozen faecal and tissue samples and real-time PCR (qPCR) for the detection of the Map-specific f57 gene was performed.

Results

PTB was diagnosed in 71.4% of the goats by any of the tests used: 53.3% by both histopathology and faecal qPCR, 33.3% only by histopathology, and 13.3% were only positive by qPCR on tissues but not faeces. The 40% of affected animals that were positive in the faecal qPCR mainly exhibited advanced and multibacillary lesions. However, not all animals with mild and paucibacillary lesions were faecal qPCR positive.

Conclusions

PTB affected a high percentage of discarded goats without apparent clinical digestive signs. The faecal qPCR was highly specific but not very sensitive to detect animals with mild lesions and low bacterial load.

Poster Abstracts Veterinary Pathology

LIVESTOCK

128 | ALPACA PATHOLOGY IN IRELAND: 13 YEARS OF SURVEILLANCE

S.A. Mignacca*, S. Salgado†, M. Wilson†, M. Sheahan†, M. McElroy†, S. Fagan†, M. Casey†, J. Moriarty†, S. McGettrick†, A. Johnson† and C. Sánchez-Miguel‡

*Pathology Division, Department of Agriculture Food and the Marine and †Department of Agriculture Food and the Marine, IE and ‡Department of Agriculture, Food and the Marine, Ireland, IE

Introduction

Keeping of new world camelids is becoming more popular in Europe. This work reports the main causes of alpaca alpaca (*Lama pacos*) mortality in Ireland, based on the passive surveillance within the Department of Agriculture, Food and the Marine (DAFM) Veterinary State Laboratories (Ireland).

Materials and Methods

Archival data was retrieved on alpaca necropsies from January 2010 to December 2022 within the DAFM laboratories. Data available included anamnesis and clinical signs, gross findings, and ancillary laboratory results on samples selected for further investigation. Where multiple pathological processes were recorded, only the main one was included in the analysis.

Results

131 animals from 61 farms were submitted (34 males, 47 females, 50 not recorded; ages ranging from stillborn to a 19 years). The main pathological process was recorded in the following body systems: systemic (37%); digestive (35%) (of which 48% were hepatic); respiratory (4%); musculoskeletal, circulatory, and genitourinary/abortion (2% each); neuro-sensory and integument (1% each); 12% of cases were inconclusive and 4% unsuitable. For the suitable cases, the aetiologies identified were bacterial, parasitic, nutritional, traumatic/mechanical, toxic, metabolic, and congenital in 44%, 20%, 4%, 2%, 1%, 2% and 1%, respectively. Two per cent had multiple aetiologies, whilst in 20% an aetiology was not identified. The main causes of death were *Mycobacterium bovis* and *Fasciola hepatica* infections (24% and 12%, respectively).

Conclusions

Bovine TB in alpacas could pose a public health issue, especially considering these animals are often reared for rural tourism or as pets, therefore in close contact with people.

Poster Abstracts Veterinary Pathology

LIVESTOCK

131 | DIFFERENTIAL DIAGNOSIS OF ACUTE POST-VACCINAL MENINGOENCEPHALITIS IN SHEEP (ACUTE PHASE OVINE ASIA SYNDROME)

N. Calvo-Sánchez*, **A. Rodríguez-Largo***, **Á. Gómez***, **E. Pérez***, **M. Pérez†** and **L. Luján***

**Animal Pathology and †Anatomy, Embriology and Animal Genetics, Universidad de Zaragoza, Zaragoza, ES*

Introduction

Acute sterile meningoencephalitis in sheep can occur as a post-vaccine side reaction and is linked to the presence of aluminium (Al)-adjuvant in vaccines. The condition was described 10 years ago, after massive mandatory vaccination against bluetongue virus. It is included in the so-called ovine autoimmune/inflammatory (ASIA) syndrome. This acute form of this syndrome occurs 2-6 days after vaccination, with a morbidity of less than 1%. It is characterized by acute neurological signs. The acute signs usually resolve spontaneously but some individuals die. This condition still occurs today, after the use of other sheep vaccines containing Al.

Materials and Methods

A review of three cases diagnosed as post-vaccine acute sterile meningoencephalitis in sheep during recent years was carried out. A list of differential diagnoses was prepared, considering clinical picture, gross lesions and microscopic findings. Relevant diseases included were acute coenurosis, listeriosis, septicaemic meningoencephalitis, cerebrocortical necrosis, visna and scrapie.

Results

The acute form of the ovine ASIA syndrome was not associated with relevant gross lesions. Microscopic findings included severe subarachnoid oedema and a moderate to severe meningitis consisting of a mixed inflammatory infiltrate located predominantly in the deepest zone of the encephalic sulci. Bacterial agents were not isolated.

Conclusions

Ovine acute post-vaccine meningoencephalitis (acute phase, ovine ASIA syndrome) needs to be included in the differential diagnoses of acute neurological signs in sheep. Histopathology, together with a detailed anamnesis including vaccination with Al-containing vaccines and the exclusion of other causes, are essential to reach the diagnosis.

Poster Abstracts Veterinary Pathology

LIVESTOCK

140 | IMPACT OF SWINE ENTERIC CORONAVIRUSES IN THE INTESTINAL BARRIER: A HISTOPATHOLOGICAL AND IMMUNOHISTOCHEMICAL APPROACH

I. Ruedas Torres^{*}, H. Puente[†], K. Fristikova^{*}, H. Argüello[†], A. Carvajal[†] and J. Gómez-Laguna^{*}

^{}Department of Anatomy and Comparative Pathology and Toxicology, Pathology and Immunology Group (UCO-PIG), UIC Zoonosis y Enfermedades Emergentes (ENZOEM), International Agrifood Campus of Excellence (ceiA3), Faculty of Veterinary Medicine, University of Córdoba, Córdoba, ES and [†]Department of Animal Health, Faculty of Veterinary Medicine, University of León, León, ES*

Introduction

Swine enteric coronaviruses, such as porcine epidemic diarrhea virus (PEDV) or transmissible gastroenteritis virus (TGEV), have risen concern for the porcine industry due to the increase in their virulence, their recombination capacity, and the emergence of new variants. This study aimed to compare the impact of three different strains of swine enteric coronaviruses in the small intestine of infected piglets, focusing on the pathology and main components of the intestinal barrier, including the number of goblet cells, and the expression of IgA and FoxP3.

Materials and Methods

Twenty-four piglets were divided into 4 experimental groups and orally inoculated with 3 ml of sterile medium (control group) or each of two G1b PEDV strains and one recombinant TGEV-PEDV or Swine enteric coronavirus (SeCoV) (infected groups). At 3 and 6 days post-infection (dpi), 3 animals from each group were humanely euthanized. Duodenum, jejunum and ileum samples were taken for histopathological and immunohistochemical studies.

Results

Severity of lesions was evidenced in the three infected groups and was correlated with the viral load in faeces and the frequency of viral antigen-positive cells. Moreover, more extensive cell death together with a high expression of FoxP3 was detected in the duodenum and jejunum of infected animals at 3 dpi.

Conclusions

The results suggest an induction of FoxP3 cells in the small intestine to control inflammation and damage, mainly of epithelial cells, caused by viral replication. Further studies should determine the role of these cells during swine enteric coronavirus infections.

Poster Abstracts Veterinary Pathology

LIVESTOCK

180 | IS ALUMINUM REPLACEABLE IN VACCINES? A SHEEP MODEL FOR NEW BIODEGRADABLE VACCINE ADJUVANTS

E. Pérez*, **Á. Gómez***, **A. Rodríguez-Largo***, **N. Calvo-Sánchez***, **B. Parra Torrejón†**, **J.M. Delgado-López‡**, **J. Ortego§**, **Heath MD¶**, **Kramer MF¶**, **V. Sebastián***, **J. Santamaría***, **R. Reina***, **M. Pérez^Δ** and **L. Luján***

**Department of Animal Pathology, †Department of Inorganic Chemistry, University of Granada, ‡Department of Inorganic Chemistry, University of Granada, Granada, ES, §CISA-INIA-CSIC, Madrid, ES ¶Bencard Adjuvant Systems, Allergy Therapeutics Plc, *Institute of Nanoscience and Advanced Materials of Aragon (INMA), *Institute of Agrobiotechnology, CSIC-Government of Navarra and ^ΔDepartment of Anatomy, Embryology and Genetics, University of Zaragoza, Zaragoza, ES*

Introduction

Aluminum hydroxide (Al) is used as a non-biodegradable adjuvant in human and veterinary vaccines. It is associated with local reactions at the injection site (IS) and can cause neurological and autoimmune-inflammatory symptoms. Calcium phosphate nanoparticles (CPNP) and L-tyrosine crystals (MCT) are alternative biodegradable adjuvants that have been tested in mice with promising results.

Materials and Methods

Five groups of 6 lambs were used, the experiment lasted until 133 dpi. Three groups were vaccinated with inactivated bluetongue virus serotype 4 (BTV4) adjuvanted with Al, CPNP or MCT, respectively. Another group was inoculated with non-adjuvanted virus (NAV) and another with PBS. Inoculation protocols included subcutaneous vaccination and revaccination at 21 days. Serum was collected weekly for ELISA and for viral neutralization at 119 dpi. Periodic palpation of the injection site (IS) was undertaken. Necropsy included sampling of IS and other tissues.

Results

ELISA revealed higher levels of circulating antibodies in animals vaccinated with CPNP and NAV than with Al or MCT. There were no differences in neutralizing antibody levels between vaccinated groups. No systemic reactions were detected in any group. Subcutaneous local reactions were short-lived for CPNP, MCT and NAV groups. At postmortem, CPNP and MCT did not generate any detectable subcutaneous reaction. Only the Al group demonstrated local subcutaneous granulomas (8/12; 66.7%).

Conclusions

CPNP, MCT and NAV induce an immune response comparable to Al, without the generation of long-lasting local tissue reactions. Further research is warranted to establish their potential for veterinary and human vaccines.

Acknowledgements: Funded by grant RTI2018-096172-B-C33 from MICINN

Poster Abstracts Veterinary Pathology

LIVESTOCK

196 | HISTOPATHOLOGICAL ASSESSMENT OF THE INTESTINAL BARRIER IN BROILERS TREATED WITH A PHYTOGENIC OREGANO RICH ESSENTIAL OIL AND CHALLENGED WITH EIMERIA SPP.

I. Stylianaki^{*}, S. Dokou[†], M. Silva Samos[‡], T. Mantzios[§], I. Panitsidis[¶], V. Tsiouris[§], I. Giannenas[¶] and N. Papaioannou^{*}

^{}Pathology, [†]Animal Nutrition, [‡]Pathology, School of Veterinary Medicine, University of Leon, ES and [§]Unit of Avian Medicine, Clinic of Farm Animals and [¶]Laboratory of Nutrition, School of Veterinary Medicine, Aristotle University of Thessaloniki, GR*

Introduction

Maintaining the complex intestinal barrier composed of intestinal microbiota, enteric epithelial cells and mucosal immunity is crucial for the poultry industry. Histology, histomorphometry, and immunohistochemistry for Claudin-3 and CD3 represent robust tools to investigate these parameters. This study evaluated the intestinal barrier profile in broilers infected with *Eimeria* spp. and treated with a phytogetic oregano-rich essential oil (OEO) compared to salinomycin.

Materials and Methods

288 male broilers were randomly allocated to four groups: Non-infected control (A), infected control (B), infected treated with salinomycin (C), and infected treated with OEO (D). Infection was done with 3.5×10^4 *E. acervulina*, 7.0×10^3 *E. maxima*, and 5.0×10^3 *E. tenella* oocysts, respectively. On day 35, muscle samples were analyzed for malondialdehyde (MDA) and protein carbonyl (PCO) levels. Tissue samples from duodenum, jejunum and ileum were processed and stained with HE and immunohistochemistry for CD3 and Claudin-3. A scoring system by Ruggeri et al. (2014) was used for the histopathological evaluation. The number of CD3+ cells in epithelium and lamina propria, and Claudin-3 distribution and intensity were evaluated morphometrically, using the QuPath 0.4.3 programme. Additional assessments included body weight gain, and gross intestinal lesions.

Results

Group A demonstrated optimal health parameters. Groups C and D showed mirroring values and exhibited a significantly improved antioxidant status, performance and Claudin-3 expression, and less intense intestinal lesions than Group B.

Conclusions

Our results indicate that both OEO and salinomycin improve the intestinal barrier in broilers infected with *Eimeria* spp, but the modulation warrants further research.

Poster Abstracts Veterinary Pathology

LIVESTOCK

218 | COMPARATIVE STUDY OF GROSS LESIONS IN PIGS INOCULATED WITH A GLAESSERELLA PARASUIS TBPBY167A MUTANT-BASED VACCINE AND CHALLENGED WITH SPANISH CLINICAL ISOLATES OF G. PARASUIS

A. González Fernández, M. Petrocchi Rilo, M.J. García Iglesias, C.B. Gutiérrez Martín and S. Martínez Martínez

Animal Health, University of León, León, ES

Introduction

Glaesserella parasuis (*Gp*) is a Gram-negative bacillus which causes Glässer's disease (GD), being responsible for high morbidities and/or mortalities in pig intensive farms. Vaccination is considered the best choice to prevent and control GD. This study tested the effectiveness of a vaccine based on a *Gp* TbpB^{Y167A} mutant in colostrum-deprived piglets challenged with four Spanish clinical isolates each belonging to one serovar.

Materials and Methods

The experiment was conducted on 38 piglets. Two immunizations with the mutant were delivered (days 15 and 30) by a needle-free device to the oral subepithelial space of randomly chosen 20 of 38 pigs. Then, five of the vaccinated pigs and four or five of the non-vaccinated ones were randomly assigned to four groups, and challenged 15 days after the second vaccination with a sublethal dose (1×10^6 - 10^7 CFU/mL) of one Spanish clinical strain belonging to one of serovars 1 (group I, n=9), 4 (group II, n=9), 5 (group III, n=10), or 7 (group IV, n=10).

Results

The highest severity of GD was seen for serovar 7 and the lowest for serovar 4. The main differences in lesions according to serovar were polyserositis in serovar 1 (100% in controls, 40% in vaccinated pigs), arthritis in serovar 4 and pericarditis in serovar 5 (50% in controls, absence in vaccinated pigs), hepatic and pulmonary haemorrhage in serovar 7 (60% in controls, 20% in vaccinated pigs).

Conclusions

The effectiveness of TbpB^{Y167A}-based vaccine varied according to the serovar, but always decreasing gross lesions in vaccinated pigs.

Acknowledgements: This investigation was supported by project /AEI/10.13039/501100011033, "Agencia Estatal de Investigación", "Ministerio de Ciencia e Innovación", Spanish Government.

Poster Abstracts Veterinary Pathology

MISCELLANEOUS

3 | CONGENITAL IDIOPATHIC MEGAESOPHAGUS IN A 5 WEEK OLD FEMALE GORDON SETTER PUPPY

C.B. Becker and H.E. Jensen

Veterinary and Animal Sciences, University of Copenhagen, Frederiksberg C, DK

Introduction

Megaesophagus (oesophageal ectasia) occurs in several species, including dogs, cats, horses and ruminants, causing regurgitation and decreased growth. The disease is either congenital or acquired. In most species, the pathogenesis of the congenital condition remains rather obscure. However, in dogs a link to an organ specific sensory dysfunction has been documented, causing a defect in the distention sensitive vagal afferent system innervating the esophagus.

Materials and Methods

A 5 week old Gordon Setter puppy with congenital idiopathic megaesophagus (CIM) was examined clinically and pathologically by means of contrast radiography, necropsy and histopathology. Neurons within the myenteric plexus of the oesophageal wall were visualised immunohistochemically using a polyclonal anti-peripherin antibody.

Results

Antemortem weight stagnation was found and contrast radiography revealed esophageal dilation occupying the majority of the thoracic cavity, with ventral displacement of the heart and lung. These findings were confirmed at necropsy. Histological examination revealed diffuse oesophageal muscular atrophy, and mucosal erosions with underlying mononuclear inflammation. A marked decrease/absence of ganglionic cells within the myenteric plexus was shown immunohistochemically.

Conclusions

In the present CIM case, alongside oesophageal muscular atrophy, mucosal erosions and inflammation, a noticeable reduction of the myenteric plexus with a marked reduction and segmental absence of ganglionic cells (aganglionosis) was observed. These observations are comparable to findings in CIM in Friesian foals, and in oesophageal achalasia and Hirschsprungs disease in humans.

Poster Abstracts Veterinary Pathology

MISCELLANEOUS

11 | THE PRESENCE OF THYMUS DETECTABLE AT NECROPSY IN ADULT CATS WITH HYPERTROPHIC CARDIOMYOPATHY

I. Dolka*, **D. Jankowska†**, **S. Skiba†** and **M. Czopowicz‡**

**Department of Pathology and Veterinary Diagnostics, †The Scientific Society of Veterinary Medicine Students and ‡Division of Veterinary Epidemiology and Economics, Institute of Veterinary Medicine, Warsaw University of Life Sciences (SGGW), Warsaw, PL*

Introduction

The thymus undergoes age-associated atrophy (thymic involution) and is no longer detectable at 1 year in most cats. Otherwise, thymic tissue remains plastic and retains potent regenerative capacity, and a hyperplastic or persistent/residual thymus in adults may be associated with hyperthyroidism or autoimmune disorders. Hypertrophic cardiomyopathy (HCM) is a life-threatening feline cardiac disease. Hypertrophic cardiomyopathy (HCM) is a life-threatening feline cardiac disease. However, the mechanism underlying these conditions are not fully understood. The purpose of the present study was to investigate the relationship between HCM and the presence of thymus detectable at necropsy in adult cats.

Materials and Methods

Necropsy and histopathology records of 153 cats (of these, 72 had died of HCM) necropsied between 2016 and March 2023 were retrospectively reviewed. Inclusion criteria were age ≥ 2 years, complete demographic data, and information on the presence/absence of thymic tissue at necropsy.

Results

Thymic tissue was detected in 23 cats, without evidence of neoplasm. It was significantly more frequent in cats with HCM (20/72) than in cats without HCM (3/81; $p < 0.001$). Thymus was significantly more often present in castrated, pedigree, younger and heavier cats, and HCM was significantly more frequent in male, castrated, pedigree and heavier cats. Controlled for potential confounders the presence of thymus proved to be independently associated with HCM ($p = 0.010$).

Conclusions

The results show that cats with HCM often have remnant thymic tissue. Further studies are necessary to better understand the potential link between thymic involution and HCM in cats.

Poster Abstracts Veterinary Pathology

MISCELLANEOUS

43 | NECROTIZING MENINGOENCEPHALITIS IN A MALTESE DOG

S. Nešić*, **N. Andrić†**, **I. Vučićević*** and **S. Aleksić Kovačević***

**Department of Pathology and †Department of Equine, small animal, poultry and wild animal diseases, Faculty of veterinary medicine, University of Belgrade, Belgrade, RS*

Introduction

Necrotizing meningoencephalitis (NME) is a fatal, non-infectious inflammatory disease of unknown aetiology in dogs. It is considered a breed specific disease and has only been reported in selected breeds including Pug, Pekingese, Chihuahua, Maltese, Coton de Tulear, Shih Tzu, Papillon, and Boston Terrier.

Materials and Methods

The brain of a 20-month-old female Maltese dog submitted for necropsy was fixed in 10% neutral formalin for 72 hours. Transverse sections (4-5 mm) of the frontal cortex, parietal cortex, thalamus, cerebellum, and medulla oblongata were prepared, grossly examined, and further formalin fixed, then routinely processed. HE stained sections (5 µm) were prepared and examined.

Results

Grossly, multiple asymmetrical small foci of malacia were found in the cerebral hemispheres. Microscopic examination revealed necrotic changes in the brain parenchyma, together with perivascular lymphocytic cuffing. Perivascular cuffs were noticed in the meninges and grey and white matter of the frontal and parietal lobes. The perivascular cuffs were abundant and consisted of lymphocytes and plasma cells. Microscopically, perivascular oedema, reactive astrogliosis, satellitosis, and neuronophagia were also observed in the damaged tissue.

Conclusions

The localization of the changes is consistent with the clinical findings. The type of changes are relevant for the differential diagnosis in relation to other necrotic encephalitis conditions. This case underlines that the occurrence of NME-related seizures is associated with a poor outcome. Considering the multifactorial aetiology of NMO, additional molecular research will be valuable to determine the potential infectious agent.

Acknowledgements: The study was supported by the Ministry of Science, Technological Development and Innovation of the Republic of Serbia (Contract number 451-03-47/2023-01/200143)

Poster Abstracts Veterinary Pathology

MISCELLANEOUS

72 | FIRST PATHOLOGICAL REPORT OF SUCCESSFUL TRANSCATHETER PULMONARY VALVE IMPLANTATION IN A CLIENT-OWNED DOG

G. Terrade*†, M. Le Dudal†, N. Borenstein*, V. Chetboul‡§, A. Morlet*, L. Behr*, Y. Lamari*, T. Malnoe*, P. Bruneval¶ and L. Fiette*

**Veranex preclinical services (formerly known as IMMR), 75014 Paris, FR, †Unité d'Histologie et d'Anatomie Pathologique, Laboratoire d'anatomo-cytopathologie, Biopôle Alfort and ‡Unité de Cardiologie, Centre Hospitalier Universitaire Vétérinaire d'Alfort (CHUVA), Ecole Nationale Vétérinaire d'Alfort, 94704 Maisons-Alfort, FR, §U955, Equipe 03, INSERM (Institut national de la santé et de la recherche médicale), 94010 Créteil, FR and ¶Department of Pathology, Hôpital Européen Georges Pompidou, Assistance Publique-Hôpitaux de Paris, 75015 Paris, FR*

Introduction

A Beagle dog was diagnosed with severe congenital valvular pulmonic stenosis in 2016 at one year of age and underwent balloon pulmonary valvuloplasty two months later. 22 months after the procedure, echocardiography revealed severe pulmonary regurgitation, severe right ventricular and atrial dilation. Despite medical therapy, cardiac dilation worsened and a transcatheter pulmonary valve was implanted in December 2018. The Melody™ bioprosthetic valve (Medtronic Inc., Minneapolis, MN, USA) quickly resolved the right heart dilation. Mitral myxomatous valvular degeneration was detected in 2021, with left-sided congestive heart failure that worsened during the last year of the dog's life. Euthanasia was decided in February 2023 and the dog was submitted for necropsy. Here we describe long-term changes after implantation of a pulmonary stented valve in one dog, and assess the benefits of such procedure.

Materials and Methods

Ex-vivo imaging of the stents and bioprosthetic cusps was performed using an x-ray cabinet. Histopathological evaluation of formalin-fixed paraffin- and resin-embedded samples of the implanted device, bioprosthetic cusps and adjacent tissues was performed using standard cardiovascular stains and immunohistochemistry.

Results

Four years after its implantation, the device was still in place, functional and no significant cusp or stent alterations were observed.

Conclusions

Transcatheter pulmonary valve implantation was successfully performed in a dog. The bioprosthetic valve was still functional at the time of the animal's death. This case provides a proof-of-concept that such a procedure can be performed in dogs with severe pulmonary valve disease and significantly improves the animal's quality of life.

Acknowledgements: This work was funded by Veranex Preclinical Services and Ecole Nationale Vétérinaire d'Alfort. The intervention was made possible by 'Fondation Un Cœur' (Fondation de France).

Poster Abstracts Veterinary Pathology

MISCELLANEOUS

75 | STENOTIC NASOPHARYNGEAL DYSGENESIS AND SUSPECT MUSCULAR DYSTROPHY IN A JACK RUSSELL TERRIER

S. Degl'innocenti*, **W. West***, **M. Pascual Moreno†** and **A. Ortiz***

**Veterinary Pathology, University of Nottingham - School of Veterinary Medicine and Science, Sutton Bonington, GB and †Dick White Referrals, GB*

Introduction

Stenotic nasopharyngeal dysgenesis is a rare condition in dogs, characterised by abnormal development of the nasopharynx, with thickening of the soft palate and irregular attachment to the pharyngeal wall. Muscular dystrophies are a group of inherited, degenerative myopathies that are typically noninflammatory and often X-linked. Here we describe the macroscopic and histopathological findings in a case of stenotic nasopharyngeal dysgenesis associated with suspect muscular dystrophy (MD) in a 4-year and 7-month-old Jack Russell Terrier dog.

Materials and Methods

A complete post-mortem examination was carried out and samples of soft palate, oesophagus, and diaphragm were formalin-fixed and routinely processed for histopathology. Five-micron sections were stained with H&E and Masson's trichrome stain.

Results

The dog presented with a chronic history of inability to swallow, dysphagia with episodes of cyanosis while eating, and poor body condition. Biochemistry revealed markedly increased levels of creatine kinase. CT scan revealed nasopharyngeal dysgenesis associated with multifocal, oesophageal and diaphragmatic thickening, which was confirmed during post-mortem examination. The remaining main organs and body systems were macroscopically unremarkable. Histologically, oesophagus, diaphragm, and soft palate showed changes consistent with chronic degenerative myopathy, characterised by myofiber atrophy, degeneration and loss, with fibrosis, hypertrophy and regeneration, fibrofatty replacement and multifocal mineralisation. These changes are compatible with a form of MD.

Conclusions

Macroscopic and histopathological findings are consistent with a case of stenotic nasopharyngeal dysgenesis accompanied by a form of MD. To the authors' knowledge, this is the first report of nasopharyngeal dysgenesis associated with MD in dogs.

Poster Abstracts Veterinary Pathology

MISCELLANEOUS

87 | EVALUATION OF PROCALCITONIN IMMUNOHISTOCHEMISTRY AS A POST-POSTMORTEM DIAGNOSTIC MARKER FOR SEPSIS IN DOGS

B. De Jonge[†] and K. Chiers[†]

[†]Department of Pathobiology, Pharmacology and Zoological Medicine, Ghent University Faculty of Veterinary Medicine, Merelbeke, BE

Introduction

Sepsis is defined as systemic inflammatory response syndrome (SIRS) secondary to infection. SIRS represents a dysregulated generalized hyperinflammatory state of the body, which can be caused by numerous infectious and non-infectious causes. Sepsis is typically caused by bacterial haematogenous dissemination and is a common cause of death in domestic animals. Postmortem diagnosis is however often not straightforward when gross and histological lesions are not convincing. Procalcitonin (PCT) is a biomarker for sepsis in humans. A preliminary study showed that immunohistochemistry for PCT can possibly serve as a diagnostic marker for sepsis in humans. The objective of this study was to evaluate if procalcitonin immunohistochemistry can be used as a diagnostic marker for sepsis in dogs.

Materials and Methods

Cases ($n = 8$) were dogs diagnosed with sepsis based on histological detection of multiorgan suppurative inflammation with intralesional bacteria. The controls ($n = 12$) comprised 8 dogs with death due to pancreatitis or massive hepatic necrosis (non-infectious SIRS), and 4 dogs which died from acute trauma (no SIRS). In all cases, lung, liver and kidney were subjected to immunohistochemistry for procalcitonin.

Results

Of the examined tissues, only the liver showed promising results, with 75% sensitivity and 81.1% specificity. Staining was seen in the cytoplasm of hepatocytes. When only dogs with non-infectious SIRS were taken into account, the specificity was 71.4%.

Conclusions

The results indicate that procalcitonin immunohistochemistry can be used as a diagnostic tool in the post-mortem diagnosis of sepsis.

Poster Abstracts Veterinary Pathology

MISCELLANEOUS

90 | SEGMENTAL CAUDAL VENA CAVA ANEURYSM WITH THROMBOSIS IN A ONE-YEAR-OLD BRACCO ITALIANO DOG (CANIS LUPUS FAMILIARIS)

M. Pereira, S. Hilton, A. Ortiz and A. Morey Matamalas

Veterinary Pathology Service, University of Nottingham, GB

Introduction

In veterinary and human medicine, caudal vena cava (CVC) aneurysms are very rare and usually incidentally detected due to complications such as thrombosis or pulmonary embolism. CVC aneurysms are generally defined as vascular anomalies and referred to, in the veterinary literature, as segmental aplasia, with or without arteriovenous shunting, causing a dynamic obstruction potentially leading to sudden death. Here we describe the macroscopic and histopathological findings in a case of canine CVC aneurysm.

Materials and Methods

A one-year-eight-month-old female entire Bracco Italiano dog (*Canis lupus familiaris*) with a history of ataxia, loss of consciousness and sudden death was submitted for post-mortem examination (PME), followed by histopathological evaluation of formalin-fixed, paraffin-embedded tissues stained with haematoxylin-eosin.

Results

PME identified a focal marked segmental dilation of the abdominal vena cava, with intraluminal venous thrombi. Histologically, there was irregular thickening of the tunica media with elastic fibre loss and mild diffuse thickening of the tunica intima. The adventitia showed increased collagen and tortuous vasa vasorum. Other relevant findings included multi-organ multifocal haemorrhages, mild renal proximal tubular necrosis and mild midzonal hepatocellular degeneration. Moderate haemopericardium, pleural and peritoneal effusions and moderate pulmonary oedema were also present.

Conclusions

The macroscopic and histopathological findings in this case are consistent with a CVC aneurysm. Histological changes were compatible with compensatory mechanisms secondary to dilation. The primary cause for the aneurysm was unclear. Although aneurysms can present with arteriovenous shunting, this was not identified in this case. Death likely resulted from venous blood stasis and circulatory shock.

Poster Abstracts Veterinary Pathology

MISCELLANEOUS

108 | CHRONIC PROGRESSIVE LYMPHOEDEMA AND CHORIOPTIC MANGE: COINCIDENTAL COPIES OR CAPTIVATING CONNECTIONS?

M. Brys and K. Chiers

Laboratory of Veterinary Pathology, Department of Pathobiology, Pharmacology and Zoological Medicine, Faculty of Veterinary Medicine, Ghent University, Merelbeke, BE

Introduction

Chronic Progressive Lymphoedema (CPL) is a frequently observed condition in heavy draft horse breeds with abundant limb feathering. However, the underlying aetiology and pathogenesis of CPL remain poorly understood. Chorioptes bovis has been hypothesised as potential exacerbating factor or even potential causative agent. While CPL has traditionally been considered exclusive to equines, similar macroscopic and histological lesions resembling CPL have been observed in other animal species. Notably, Suffolk sheep with chronic chorioptic mange have shown comparable gross lesions. This raises questions about whether sheep are also susceptible to an underlying CPL syndrome or if the Chorioptes mite plays a pivotal role in the pathogenesis of CPL. With this study, we aimed to determine the macroscopic and histological similarities between CPL in Belgian draft horses and distal limb alterations in Suffolk sheep affected by chorioptic mange.

Materials and Methods

A comprehensive post-mortem examination, including macroscopic, histological, and immunohistochemical analyses, was conducted on a Suffolk ram with chorioptic mange and a Belgian draft horse with CPL.

Results

Gross examination of both animals revealed large skinfolds on all limbs with excessive hyperkeratosis, skin scaling, and an increase in limb diameter. Histological examination identified a superficial perivascular dermatitis with severe epidermal hyperplasia.

Conclusions

The remarkable similarity of lesions associated with chorioptic mange and CPL indicate that these mites may play a relevant role in the pathogenesis of CPL.

Poster Abstracts Veterinary Pathology

MISCELLANEOUS

115 | IN DONKEY, ARE UTERINE AND BLOOD EOSINOPHILS ASSOCIATED?

A. Radar Chafirovitch*, **M. Quaresma***, **G. Ferreira-Dias†**, **J. Miró‡** and **M.d.A. Pires***

**Animal and Veterinary Investigation Center (CECAV) e AL4Animals, ECAV,, Universidade Trás os Montes e Alto Douro, Vila Real, PT, †2CIISA, AL4Animals, Faculty of Veterinary Medicine, Faculty of Veterinary Medicine, Lisbon University, Lisboa, PT and ‡3Equine Reproduction Service, Department of Animal Medicine and Surgery, Autonomous University of Barcelona, Barcelona, Barcelona, ES*

Introduction

In donkeys, in contrast to mares, endometrial eosinophil infiltrates are abundant and might not have a deleterious effect on fertility whereas in mares, the presence of inflammatory cells and collagen in the endometrium, is likely associated with infertility. The study aimed to relate blood and endometrium eosinophil counts in Burro de Miranda donkeys.

Materials and Methods

Venous blood samples and endometrial biopsies were obtained from fourteen Burro de Miranda (2-16 years). Ten high-power microscopic fields per slide were photographed and evaluated with ImageJ® software for endometrial eosinophil counts. A leukogram was performed in a commercial laboratory.

Results

According to the haemograms of other European donkey breeds, none of the 14 jennies evaluated exhibited eosinophilia, with average cell counts from 0.51×10^9 to 1.14×10^9 cells/mL. In contrast, eosinophils were detected in the endometrium of 8/14 animals, with an average of 94.3 to 117.6 cells/10 fields, present in both stratum compactum and spongiosum, varying between 1 and 539 eosinophils. There was no association between blood and uterine eosinophil count ($P=0.361$, $R^2=0.529$) and no age effect on blood or endometrium eosinophil count ($p>0.05$). However, endometrium eosinophil count increased in categories IIB and III compared to IIA according to the Kenney and Doig classification ($p=0.03$).

Conclusions

In the donkey, peripheral blood eosinophils appear to have a tropism for the uterus. Since they are present even in young and dewormed donkeys, they might be physiological in this species. The underlying mechanisms and the potential relevance of eosinophils for reproduction in eosinophils warrants further studies.

Acknowledgements: Associação para o Estudo e Protecção do Gado Asinino. Funding: supported by the projects UIDB/CVT/00772/2020 and LA/P/0059/2020 funded by the Portuguese Foundation for Science and Technology (FCT). Ariana Radar Chafirovitch is also supported by the grant UI/BD/150839/2021 (FCT)

Poster Abstracts Veterinary Pathology

MISCELLANEOUS

132 | FELINE HYPERTROPHIC CARDIOMYOPATHY: PHENOTYPICAL AND FUNCTIONAL CHANGES IN CARDIOMYOCYTES

L. Schurna^{*†}, J. Monné Rodríguez^{*}, J. Joshua[‡], G. Monteith[‡], F. Prisco^{*}, S. Fonfara[‡] and A. Kipar^{*}

^{}Institute of Veterinary Pathology and [†]Center for Clinical Studies, Vetsuisse Faculty, University of Zurich, Zurich, CH and [‡]Department of Clinical Studies, University of Guelph, Guelph, CA*

Introduction

Feline hypertrophic cardiomyopathy (fHCM) is the most frequently diagnosed cardiomyopathy in domestic cats. While we know that fHCM is associated with myocardial remodelling, the relevant underlying pathogenic processes are still poorly understood. The present study aimed to determine molecular phenotypic changes in cardiomyocytes that could highlight pathogenic mechanism in fHCM.

Materials and Methods

The hearts of 15 cats with clinically confirmed fHCM (11 male, 4 female) and 31 control cats were subjected to RT-PCRs for a range of markers indicative of cardiomyocyte functional alterations and adaption, the upregulation of which was indicated in a recent RNA sequencing study of our group (IGF1R, IRS1, PI3K, MRAS, B-RAF, MFN2, GATA4, GATA6, MEF2C, VEGFA, TSP1). For each gene, a TaqMan-based two-step RT-qPCR protocol was established.

Results

In general, marker expression was highest in young control cat hearts, and increasing age correlated with a decrease in expression regardless of sex. However, expression of factors influencing angiogenesis (VEGFA, TSP1) and hypertrophy related MFN2 was significantly higher in fHCM cats regardless of sex while expression of markers for other hypertrophy and foetal genes as well as intercellular signaling genes (ITGA10, ITGAM) were upregulated in male fHCM cats only.

Conclusions

The results confirm upregulation of a range of markers in fHCM compared to healthy hearts, with certain sex-related differences in fHCM. There is evidence of adaptive attempts (hypertrophy and dedifferentiation), and increased signal transduction and cross talk, most pronounced in male cats which are known to be predisposed to fHCM.

Poster Abstracts Veterinary Pathology

MISCELLANEOUS

136 | OVARIOHYSTERECTOMY AS A POTENTIAL TRIGGER FOR ACQUIRED SKIN FRAGILITY SYNDROME IN A JUVENILE CAT

V. Castiglioni*, **P.C. Giancristofaro[†]** and **J.J. Van der Lugt[‡]**

**IDEXX Laboratories Italia S.r.l., Novara, IT, [†]Veterinari Associati Dr. Giancristofaro e Di Giovanni, IT and [‡]IDEXX Laboratories, NL*

Introduction

Acquired skin fragility syndrome (ASFS) is a very rare syndrome described in middle-aged or older cats, with no breed or sex predilection. The condition is characterized by fragile and thin skin, severely damaged by minor trauma, with no evidence of hyperextensibility. Its pathogenesis is not known, but it is most commonly associated with iatrogenic or naturally-occurring hyperglucocorticoidism, diabetes mellitus, excessive usage of progestational compounds, in conjunction with severe liver disease, phenytoin administration, feline dysautonomia and/or nephrosis. Idiopathic cases are reported. Here we describe a case of ASFS following routine ovariohysterectomy in a juvenile cat without any clinical diseases and speculate on its pathogenesis.

Materials and Methods

A 10-month-old female mixed breed cat from a colony was presented to a veterinary practice suffering from cutaneous thinning and lacerations. The cat tested FIV and FeLV negative. Clinical signs had started to develop 2 months after ovariohysterectomy. Cutaneous biopsies were submitted for histopathological evaluation.

Results

Histological lesions were characterized by a thin epidermis and dermal and adnexal atrophy, with attenuated and/or stretched pale collagen fibers, with a wispy appearance. Multifocally there were areas of ulceration associated with severe inflammation.

Conclusions

In this case, iatrogenic causes such as excessive use of glucocorticoids or progestational compounds were excluded based on anamnesis. Clinical history and haemogrammes and serum biochemical profiles did not support an underlying hyperadrenocorticism, diabetes mellitus or liver disease. Routine ovariohysterectomy could represent a possible trigger for the development of this spontaneous skin tearing.

Poster Abstracts Veterinary Pathology

MISCELLANEOUS

152 | BILATERAL GRANULOMATOUS AND NECROTIZING PANOPHTHALMITIS OCCURRING AFTER VACCINATION IN A DOG

C. Naranjo Freixa*, **M. Caro Suárez†**, **M. Sánchez Encinas‡**, **I. Rodríguez Piñeiro‡** and **F. Laguna Sanz†**

**Anatomic Pathology, IDEXX Laboratories, Barcelona, ES and †Ophthalmology Service and ‡Internal Medicine Service, Hospital Veterinario Puchol, Madrid, ES*

Introduction

Vaccine reactions are occasionally reported in dogs. Here we describe a case of bilateral granulomatous and necrotizing panophthalmitis in a dog occurring after vaccination.

Materials and Methods

Clinical history and diagnostic tests were reviewed, including complete physical and ophthalmic examination, CBC, biochemistry, serology, abdominal ultrasound, cytology and culture of aqueous and vitreous humor, and histopathology of both eyes.

Results

A 1 year and 9-month-old female intact Beagle dog was presented with bilateral blindness. It had been vaccinated with a pentavalent vaccine approximately 1 week prior to presentation. After complete ophthalmic examination a clinical diagnosis of bilateral panuveitis of presumed infectious origin was made. Biochemistry revealed a 20-fold increase in ALT and ALP and 7-fold increase in GGT. Serology for *Leishmania infantum*, *Ehrlichia canis*, *Anaplasma* spp and *Rickettsia* spp was negative. PCR for *Leptospira* spp on aqueous humor and PCR for *Anaplasma* spp and *Bartonella* spp on blood were also negative. Cytology and culture of the aqueous and vitreous humor did not reveal organisms. Microscopic examination showed bilateral granulomatous panophthalmitis, including severe granulomatous scleritis and extensive necrosis of the uvea. Special stains (Gram, PAS, Ziehl-Neelsen, Warthin Starry) and PCR for *Leptospira* spp performed on the paraffin block were negative. Liver values progressively normalized.

Conclusions

Granulomatous and necrotizing scleritis is suspected to have an immune-mediated origin and, in this dog, it occurred bilaterally and symmetrically shortly after vaccination, associated with extensive uveal necrosis. We hypothesize that the severe ocular lesions in this dog may have been related to the recent vaccination.

Poster Abstracts Veterinary Pathology

MISCELLANEOUS

166 | LEFT VENTRICULAR APICAL DIVERTICULUM WITH AORTIC THROMBOEMBOLISM IN A CAT

I. Constantin*, **A.F. Tăbăran***, **C. Cătoi***, **R. Pop*** and **I.C. Scurtu†**

**Veterinary Pathology and †Veterinary Internal Medicine, Faculty of Veterinary Medicine, Cluj-Napoca, RO*

Introduction

Left ventricular diverticulum (LVD) and aneurysm (LVA) are rare cardiovascular conditions in veterinary medicine, often associated with underlying cardiac pathological changes, such as cardiomyopathies or myocarditis. Here we present the gross and histological features of a case of left ventricular apical diverticulum in a female adult cat associated with aortic thromboembolism.

Methods

The feline subject was a 7-year-old domestic short-haired cat, who presented with clinical signs of cardiac dysfunction and respiratory distress. Postmortem examination revealed a 7x7 mm, well-demarcated, translucent, focal area of left ventricular apical thinning of the cardiac wall, with a narrow communication into the left ventricle (apical diverticulum). Associated with the cardiac changes, marked, diffuse cardiogenic pulmonary congestion and oedema and ileac-artery occluding thromboembolism were present. After complete fixation in 10% neutral buffered formalin, the heart was examined using the "four-chamber" technique. Histological sections from the heart were stained with H&E and Trichrome for comprehensive evaluation.

Results

Histologically, the apex showed all three layers of the heart with myocardial thinning, with minimal subendocardial fibrosis, and the presence of cardiomyocytes in the fibrous tissue.

Conclusions

The histopathological findings provide valuable insights into the pathological changes associated with LVD in feline patients, in which all the three components of the cardiac wall are present compared with the structure of the aneurysm. To our knowledge, this is the first description of a cardiac diverticulum in a cat.

Poster Abstracts Veterinary Pathology

MISCELLANEOUS

168 | MECONIUM ASPIRATION SYNDROME AS INDICATOR OF VITALITY AND PERINATAL ILLNESS STATUS IN FOALS

R.E. Tiu, G.L. Nicolae, A.A. Dobrin, R.I. Rizac, I.A. Popa and E. Ciobotaru-Pirvu

University of Agronomic Sciences and Veterinary Medicine Bucharest, Faculty of Veterinary Medicine, Bucharest, RO

Introduction

Meconium aspiration syndrome (MAS) is a respiratory disorder associated with low vitality or perinatal respiratory dysfunctions which can be diagnosed before parturition due to foetal asphyxia and gasping or during delivery. The presence of meconium in the alveoli or bronchioles indicates intrauterine meconium discharge into the amniotic fluid due to foetal distress, and subsequent surfactant inactivation and inflammation. The present study correlated MAS with gross lesions and concurrent infections in foals.

Methods

The study included ten cases of perinatal death. Standard necropsy was performed, followed by routine histopathology and PCR investigation for *Taylorella equigenitalis*, Equine Arteritis Virus, Equine Herpesvirus 1, *Streptococcus equi* and *Leptospira* spp.

Results

Gross examination revealed lesions resulting from dystocia and hypoxia (haemoperitoneum, subpleural haemorrhages, multiple organ congestion), diffuse or focally extensive pulmonary atelectasis, oedema and emphysema (n=2), acute epicarditis and pneumonia (n=1). Histologically, all foals exhibited aspirated meconium within pulmonary alveoli and bronchioles. Additional amniotic fluid was present in the alveoli (n=1). Mononuclear interstitial pneumonia (n=1), non-suppurative encephalitis (n=3), pulmonary oedema and emphysema (n=2) were histologically diagnosed. Two cases had allantoic epithelial cell hyperplasia with oedema, inflammatory cell infiltration, neovascularization, umbilical vasculitis and discrete acute funisitis. PCR testing identified *Streptococcus equi* (n=4) and *Leptospira* spp. (n=3).

Conclusions

The present study found evidence of bacterial challenge during gestation in a high proportion of foals (70%) with MAS. In conclusion, the presence of MAS associated or not with unspecific gross lesions of foal or placenta are highly suspicious of any aetiology that causes foetal distress.

Poster Abstracts Veterinary Pathology

MISCELLANEOUS

183 | HISTOLOGICAL AND IMMUNOHISTOCHEMICAL CHARACTERIZATION OF THE DONKEY (EQUUS ASINUS) MAMMARY GLAND

R. Jesus*, **A. Chafirovitch-Radar†**, **M.A. Pires^{‡,†}**, **R. Payan-Carreira§**, **M. Nóvoa¶**, **M. Quaresma†** and **A. Gama^{‡,†}**

**Escola de Ciências e Tecnologia, Universidade de Évora and †Animal and Veterinary Research Centre (CECAV) and Associate Laboratory for Animal and Veterinary Science (AL4Animals), ‡Department of Veterinary Sciences, School of Agrarian and Veterinary Sciences (ECAV), University of Trás-os-Montes e Alto Douro (UTAD), Vila Real, PT, §Comprehensive Health Research Centre, Veterinary Medicine Department, Escola de Ciências e Tecnologia, Universidade de Évora, Évora, PT and ¶Associação para o Estudo e Proteção do Gado Asinino, Miranda do Douro, PT*

Introduction

A comprehensive characterization of the donkey mammary gland (MG) histology can support the investigation of pathological processes affecting this organ, such as mastitis and proliferative lesions. Given that scarce information is available on this topic, the present study aimed to evaluate the histomorphological characteristics of the asinine MG.

Materials and Methods

Sixty-five MGs collected from jennies (0 to 37 years; mean 17.9) during post-mortem examination were formalin-fixed and processed for histopathology. Immunohistochemistry was performed on sixteen samples using anti-cytokeratin AE1/AE3, α -smooth muscle actin, p63, calponin and vimentin antibodies.

Results

Donkey MGs presented a structural organization comparable to horses, with two paired mammary complexes exhibiting distinct histological morphologies (prepubertal, inactive, fully developed lactating and involuting MG). Mineralized concretions (psammoma bodies) were frequently observed (n=30; 46.1%). MGs from 10 adult jennies (15.4%) presented the following alterations: papillomatosis, characterized by intraductal epithelial papillary projections, associated with duct ectasia (n=2; 3.1%); cystic apocrine metaplasia, characterized by cystically dilated ducts lined by benign apocrine epithelium (n=1; 1.5%) and sebaceous and apocrine metaplasia (n=6; 9.2% and n=3; 4.6%, respectively), with multiple alterations found in two animals. The immunohistochemical markers showed expression patterns similar to other species, confirming these cell markers as suitable phenotypical markers in donkeys.

Conclusions

This study presents a histological characterization of donkey MGs, confirming the morphological and immunohistochemical similarities with other mammals, especially mares. We believe that comparative studies on the pathology of MG focusing on donkeys may provide new insights on mammary tumourigenesis, with potential application to other species.

Acknowledgements: This work was financed by national funds through FCT-Portuguese Foundation for Science and Technology, within the scope of the projects UIDB/CVT/00772/2020 (CECAV) and LA/P/0059/2020 (AL4Animals) and PhD grant UI/BD/150839/2021 (ARC).

Poster Abstracts Veterinary Pathology

MISCELLANEOUS

201 | VANIN-1 IS EXPRESSED IN THE AIRWAY EPITHELIUM OF HORSES AND HAS A HIGHER ABUNDANCE IN THE MUCUS OF HORSES WITH SEVERE EQUINE ASTHMA COMPARED TO HEALTHY HORSES

K. Landmann^{*}, F. Bartenschlager^{*}, B. Kuropka[†], C. Weise[†], H. Gehlen[‡], A. Zeyner[§], A.D. Gruber^{*}, C.L. Schnabel[¶] and L. Mundhenk^{*}

^{}Institute of Veterinary Pathology, [†]Core Facility BioSupraMol and [‡]Equine Clinic, Freie Universität Berlin, Berlin, DE, [§]Institute of Agricultural and Nutritional Sciences, Martin Luther University Halle-Wittenberg, Halle, DE and [¶]Emmy Noether Junior Research Group, Institute of Immunology, Leipzig University, Leipzig, DE*

Introduction

Hypersecretion and mucus plugging are hallmarks of equine asthma (EA), one of the most important respiratory diseases of horses. However, the proteins in the mucus with compositional changes in EA and their characteristics are widely unknown. The genomic characteristic and the tissue and cellular expression pattern of a molecule which was abundantly detected in the mucus of horses with severe EA (SEA) for the first time was further investigated in healthy horses (HH).

Materials and Methods

In a landscaping approach, the proteome of the airway mucus of HH (n=9) and horses with SEA (n=10) was analysed using liquid chromatography tandem mass spectrometry. A molecule which was massively found in the mucus of SEA was genomically characterized in silico and the tissue and cellular expression pattern in the airways was analysed in HH (n=3) via RT-qPCR or in situ hybridization, respectively.

Results

Vanin-1 was found abundantly in the mucus of horses affected by SEA compared to HH. It is one of three vanin genes in the equine genome. All members were found to be expressed in the airway lining epithelium and submucosal glands along the respiratory tract, with Vanin-1 being predominantly expressed in tracheal as well as bronchial ciliated epithelial and goblet cells.

Conclusions

Vanin-1 is one of three members of a family which are expressed in the equine respiratory tract. It is a highly abundant protein in the mucus of horses with SEA. Its role in SEA will be further investigated.

Poster Abstracts Veterinary Pathology

MISCELLANEOUS INFECTIOUS DISEASE

20 | COMPLICATIONS ENCOUNTERED IN LETHAL EUROPEAN BABESIOSIS

D. Huber*, **B. Artuković***, **M. Hohšteter***, **L. Medven Zagradišnik***, **D. Vlahović***, **I. Mihoković Buhin***, **A. Gudan Kurilj***, **J. Habuš†** and **I.C. Šoštarčić-Zuckermann***

**Department of Veterinary Pathology and †Department of Microbiology and Infectious Diseases, Faculty of Veterinary Medicine University of Zagreb, Zagreb, HR*

Introduction

Canine babesiosis is an important emerging vector-borne diseases of worldwide distribution. Reported pathologic findings of this disease include haemolytic anaemia with jaundice, bilirubin and haemoglobin deposition in tissues, splenomegaly, haemorrhages and pulmonary oedema. Here we report pathological findings so far not described in European canine babesiosis.

Materials and Methods

The study included 31 dogs that had died due to babesiosis, proven by the detection of merozoites within erythrocytes but not lymphocytes, in cytological and histological specimens. In all dogs, leptospirosis was excluded by a microscopic agglutination test, and the most common bacterial infections were excluded with a Gram stain.

Results

All dogs showed signs of haemolytic disease, and eight dogs exhibited changes consistent with disseminated intravascular coagulation. Three dogs suffered from fibrinous pleuritis accompanied by multifocal to confluent rhabdomyolysis of intercostal muscles, with intralesional vascular thrombi in one dog. Ten dogs showed severe alveolar oedema with alveolar haemorrhage, and seven dogs exhibited a multifocal to coalescing, necrotic mixed cellular myocarditis. Fibrinous peritonitis was seen in five dogs, in three of these this was accompanied by acute necrotic pancreatitis.

Conclusions

Acute pancreatitis and rhabdomyolysis have so far only been reported in association with African canine babesiosis, which is presumed to be the most pathogenic form of babesiosis. Other changes, i.e. pleuritis, alveolar oedema with haemorrhage and myocarditis, have so far not been associated with canine babesiosis at all. The results emphasise that even though *Babesia* parasites primarily affect erythrocytes, babesiosis represents a multi-systemic disease affecting all organs and tissues.

Poster Abstracts Veterinary Pathology

MISCELLANEOUS INFECTIOUS DISEASE

92 | UNUSUAL PATHOLOGICAL FINDINGS IN A HORSE INFECTED WITH TAPEWORM ANOPLOCEPHALA PERFOLIATA

D. Stankevica*, **D. Gorbacevska***, **J. Vanaga†** and **A. Kalnina‡**

**Preclinical institute, Faculty of Veterinary Medicine, †LBTU Veterinary clinic, Faculty of Veterinary Medicine and ‡Institute of Food and Environmental Hygiene, Faculty of Veterinary Medicine, Latvia University of Life Sciences and Technologies, Jelgava, LV*

Introduction

Anoplocephala perfoliata is described as the most prevalent tapeworm infecting horses associated with different types of colic. The parasites frequently attach to the wall of the caecum and ileum, leading to mechanical obstruction of the intestine, damage of the gut mucosa, hypertrophy of the intestinal circular muscle layer as well as ileal impaction or intussusception.

Materials and Methods

A 6 year old female horse was sent for postmortal examination after it was euthanized due to anorexia, depression and progressive weight loss. Blood analysis showed mild anaemia. Full gross and histological examination and parasitological examination of the intestinal parasites was performed.

Results

Necropsy of the horse showed severe emaciation and severe tapeworm infestation of the jejunum, with multiple ulcerations and haemorrhages of the intestinal wall but only few tapeworms in the caecum. Parasitological examination of the jejunal specimens identified more than 100 tapeworms belonging to the species *Anoplocephala perfoliata*. Morphological investigation also revealed serous atrophy of body fat tissue and gelatinous transformation of the femoral bone marrow. Histological examination showed mucosal atrophy of the jejunum and mild lymphocytic enterocolitis without eosinophil infiltration.

Conclusions

Pathological findings of the horse included changes not typically associated with *Anoplocephala perfoliata* infestation, such as severe jejunal infestation instead of the typical localization of the parasite in the ileocaecal region. Mild intestinal inflammatory changes with absence of eosinophils could be explained by the bone marrow atrophy and hence reduced haematopoiesis.

Poster Abstracts Veterinary Pathology

MISCELLANEOUS INFECTIOUS DISEASE

153 | DOWN-REGULATION OF THE MICROBICIDAL PROFILE OF M1 MACROPHAGES BY ENCEPHALITOOZON CUNICULI

F.T. Camargo Konno^{*†}, J.G. Xavier^{*}, A.M. Alvarez-Saraiva^{*}, E.C. Pérez^{*}, D.D. Spadacci-Morena[‡] and M.A. Lallo^{*}

^{}Patologia Ambiental e Experimental, Universidade Paulista-UNIP, [†]Universidade Paulista and [‡]Departamento de Fisiopatologia, Instituto Butantan, São Paulo, BR*

Introduction

Microsporidia infect vertebrates and invertebrates and are recognized as opportunistic agents in individuals with immunological deficiencies. Although the activity of CD8+ T lymphocytes is essential to eliminate microsporidia, macrophages are attributed a fundamental role in innate immunity and in the activation of acquired immunity. For some infectious agents, the polarization of macrophages to the M1 and M2 profiles is fundamental in defining the course that the infection will take. This study aimed to evaluate in vitro the activity of macrophages modulated for the M1 and M2 profiles in encephalitozoonosis.

Materials and Methods

Murine bone marrow macrophages (BMD) previously differentiated were polarized in M1 with recombinant IFN- γ +LPS and in M2 with IL-4 for 24 hours and challenged with *E. cuniculi* at a 2:1 ratio for 5, 10 and 24 hours, for determination of the phagocytic index, nitric oxide and cytokine production, and cell phenotyping.

Results

Macrophages polarized to M1 showed high expression of CD40+, iNOS, CD80/86 and MHC. However, we observed a decrease in CD40+ expression in M1 macrophages challenged with *E. cuniculi*. Infection by *E. cuniculi* determined a significant decrease in CD206+ expression by M2 macrophages, once again indicating the ability to modulate the phenotype of these cells induced by the presence of the pathogen. Additionally, the phagocytic index of *E. cuniculi* spores was lower in M1 compared to M2 macrophages.

Conclusions

The microsporidia *E. cuniculi* was able to modulate the microbicidal phenotype of M1 macrophages by decreasing CD40 and iNOS expression over time of infection.

Poster Abstracts Veterinary Pathology

MISCELLANEOUS INFECTIOUS DISEASE

154 | CROTOXIN MODULATES THE M1 PROFILE OF MACROPHAGES INFECTED WITH ENCEPHALITOZOON CUNICULI

C.G. Nascimento de Oliveira*, **J.G. Xavier***, **A.M. Alvares-Saraiva***, **E.C. Pérez***, **D.D. Spadacci-Morena†**, **S.C. Sampaio†** and **M.A. Lallo***

**Patologia Ambiental e Experimental, Universidade Paulista-UNIP and †Departamento de Fisiopatologia, Instituto Butantan, São Paulo, BR*

Introduction

Crotoxin (CTX), a bioactive extract from the snake *Crotalus durissus terrificus*, demonstrated the ability to modulate the profile of macrophages infected with *Leishmania amazonensis*, with increased phagocytic capacity and elimination of intracellular parasites. Microsporidia are opportunistic, obligate intracellular fungi that infect vertebrates and invertebrates, having demonstrated the ability to modulate the macrophage profile. The aim of this study was to evaluate the effects of crotoxin on the viability of spores of the microsporidian *Encephalitozoon cuniculi*, as well as on the microbicidal activity of macrophages in vitro.

Materials and Methods

Peritoneal adherent cells (APerC), obtained from peritoneal washings of BALB/c mice, were infected with spores of *E. cuniculi* and treated with CTX for 3 h. The profile and viability of macrophages, cytokine production and microbicidal activity were assessed as parameters.

Results

Macrophages infected with *E. cuniculi* and treated with CTX showed an increase in the M1 profile, more necrosis and increased production of cytokines TNF- α and IL-6. Also, the spores obtained from these macrophages had a reduced proliferative capacity.

Conclusions

The results indicate that CTX modulated macrophages infected with *E. cuniculi* differentiate towards the M1 profile, with increased production of pro-inflammatory cytokines and greater microbicidal activity. This suggests the potential of macrophages to modulate the fungistatic and/or fungicidal activity against *E. cuniculi*.

Poster Abstracts Veterinary Pathology

MISCELLANEOUS INFECTIOUS DISEASE

182 | INTERSTITIAL PNEUMONIA ASSOCIATED WITH EHV-5 IN THREE ADULT DONKEYS: PATHOLOGICAL AND MOLECULAR FINDINGS OF THE FIRST CASES IN ROMANIA

D.L. Hodor*, **A.G. Negoescu***, **C. Toma***, **A. Mureşan†**, **C. Molnar†**, **C. Cătoi*** and **M. Taulescu***

**Pathology and †Internal Medicine, University of Agricultural Sciences and Veterinary Medicine, Cluj-Napoca, RO and ‡Transylvania Arabians, RO*

Introduction

Equine herpesviruses (EHV) play a significant role as pathogens in both horse and donkey populations, leading to substantial economic losses. EHV-5 is a member of the equine gammaherpesviruses subfamily, along with EHV-2 and EHV-7 and is significantly associated with equine multinodular pulmonary fibrosis (EMPF), a distinct form of progressive interstitial pulmonary fibrosis in horses. This study documented the first occurrence of chronic respiratory disease associated with EHV-5 in donkeys in Romania.

Materials and Methods

In an ecological donkey farm with a herd of 140 donkeys, 8 animals showed respiratory signs including long-term dyspnoea. Three donkeys died and were sent for postmortem examination. Samples (lung tissue and mediastinal lymph node) were collected for cytological, histopathological and PCR (EHV-1, EHV-4, EHV-5) analyses.

Results

The macroscopical lesions in affected donkeys consisted of lungs that failed to collapse and showed a diffuse rubbery-firm texture with visible rib imprints and a micronodular aspect on the cut surface. Histologically, the lungs exhibited severe multifocal to coalescing interstitial pneumonia with multinucleated syncytial cells, mild fibrosis, pneumocyte type 2 hyperplasia, and alveolar histiocytosis. Mediastinal lymph nodes showed severe reactive lymphoid hyperplasia and severe infiltration with macrophages and syncytial cells. PCR identified EHV-5 in all examined animals.

Conclusions

EHV-5 infection showed gross and histological lesions consistent with interstitial pneumonia and no distinctive features indicative of other herpesvirus infections. Molecular analysis confirmed EHV-5 infection in all examined cases. To authors' knowledge, this is the first report in Romania of EHV-5-associated interstitial pneumonia in donkeys.

Poster Abstracts Veterinary Pathology

MISCELLANEOUS INFECTIOUS DISEASE

189 | MASS SPECTROMETRY IMAGING (MALDI-MSI) AS A MOLECULAR HISTOLOGY APPLICATION FOR CHARACTERIZING PULMONARY LESIONS CAUSED BY PRRSV-1 STRAINS OF DIFFERENT VIRULENCE

J. Sánchez-Carvajal*, **I. Rodríguez-Gómez***, **I. Ruedas-Torres***, **F. Pallarés***, **L. Carrasco***, **E. Chicano-Gálvez†** and **J. Gómez-Laguna***

**Anatomy and Comparative Pathology and Toxicology, Faculty of Veterinary Science, University of Cordoba and †IMIBIC/UCO/HURS, Córdoba, ES*

Introduction

Porcine Reproductive and Respiratory Syndrome Virus (PRRSV) is a significant viral pathogen that affects swine populations worldwide. This study applied MALDI-MSI as a molecular histology tool to determine the peptide signature of the lungs of piglets infected with PRRSV-1 strains of different virulence.

Materials and Methods

A total of 52 piglets were divided into 3 groups: (i) control group (n=12), (ii) piglets infected with the low-virulence PRRSV-1 strain 3249 (n=20), and (iii) piglets infected with the virulent PRRSV-1 strain Lena (n=20). Animals were sacrificed at 1, 3, 6, and 8 days post-infection (dpi). For the MALDI-MSI study, each three animals euthanised at 6 and 8 dpi were selected based on clinical signs, macroscopic and microscopic lesions, and viral load.

Results

We found 190 proteins to be differentially expressed between the control and infected groups, with statistical significance (ANOVA; $P < 0.025$). Using sparse PLS Discriminant Analysis (sPLS-DA) based on the protein intensity profiles, a clear differentiation was observed between the experimental groups and sacrifice dates, confirming the analysis' stability. Ontology analysis revealed that the differentially expressed proteins were associated with signaling pathways related to "posttranscriptional gene expression regulation," "mRNA catabolic processes," "exocytosis," and "neutrophil degranulation." Hub proteins, including C3 and C4a complement components, apolipoprotein A and B, and ISG15, were identified as central players in protein-protein interaction networks during PRRSV-1 infection at the lung level.

Conclusions

MALDI-MSI enables a proteomic approach for the detection of novel peptides potentially associated with different observed lesion patterns in piglets infected with PRRSV-1.

Acknowledgements: JMSC and IRT are supported by a "Margarita salas" contract from the Spanish Ministry of Universities. This work was supported by the Spanish Ministry of Economy and Competitiveness (#AGL2016-76111-R and PID2019-109718GB-I00).

Poster Abstracts Veterinary Pathology

MISCELLANEOUS INFECTIOUS DISEASE

206 | CHARACTERIZATION OF AQUAPORIN-4 EXPRESSION IN THE BRAINS OF DOGS WITH CANINE LEISHMANIASIS

G.G. Jussiani, E.D. Frigério, R.M.B. de Aquino, M.E.E. Marchioni, M.A.I. Zoccoler and G.F. Machado

School Of Veterinary Medicine, São Paulo State University, UNESP, Araçatuba, BR

Introduction

Aquaporin-4 (AQP4) is a water channel protein expressed in astrocytes that has been associated with several neuroinflammatory conditions. The objective of this study was to assess whether AQP4 expression in astrocytes is affected during canine leishmaniosis (CanL).

Materials and Methods

We used formalin-fixed, paraffin-embedded blocks, cut at 5 µm thickness, of twenty brains of dogs diagnosed with CanL, which presented mild to pronounced inflammatory changes in the nervous tissue, such as meningitis, choroiditis and/or presence of perivascular cuffs, determined in HE stained sections. Immunohistochemical stain was performed using primary antibodies specific for AQP4, GFAP (Glial Fibrillary Acidic Protein) and CD3 (T lymphocytes) in order to characterize the distribution of AQP4, astrocytes and inflammation within the brain. Microscopic description and semiquantitative evaluation of the expression and intensity of AQP4 immunoreaction were conducted in standardized areas of the brain, including cortex, hippocampus, subependymal and perivascular regions.

Results

AQP4 immunoexpression was most intense in the subpial and subependymal regions of all dogs and co-localized with GFAP staining. The intensity of the labeling was gradually fading towards the neuropil. We observed increased perivascular marking particularly in the regions where there were perivascular cuffs, associated with T lymphocytes, but there was no significant correlation between inflammation and AQP4 labeling intensity.

Conclusions

Since it is known that there are alterations in the blood-brain barrier during CanL, the pattern of increased perivascular AQP4 expression may suggest the participation of astrocytes in the modulation of inflammation in brain leishmaniosis, regulating water homeostasis.

Poster Abstracts Veterinary Pathology

NEW METHODS, NEW TECHNOLOGY, TEACHING

80 | A SURVEY OF THE ECVF MEMBERSHIP ON KNOWLEDGE, ATTITUDES, AND ACCESS TO NEW TECHNOLOGIES IN VETERINARY PATHOLOGY

J. Williams*, **J. Monné Rodríguez†**, **R. Kuiper‡**, **I. Berenguer Veiga†**, **V. Herder§** and **L. Stimmer¶**

**Pathobiology and Population Sciences, Royal Veterinary College, London, GB, †Roche Pharma Research and Early Development, Pharmaceutical Sciences Pathology Chapter, Roche Innovation Center Basel, CH, ‡Section Aquatic Biosecurity Research, Norwegian Veterinary Institute, Ås, NO, §MRC, University of Glasgow Centre for Virus Research, Glasgow, GB and ¶HISTOMICS-Platform for experimental histology, Paris Brain Institute-INSERM, Paris, FR*

Introduction

The ECVF Innovation and New Technologies Task Force was established to inform learning activities of the profession in the ever-evolving techniques used in modern pathology. This survey was conducted to guide future knowledge sharing activities relating to new technologies in veterinary pathology, and to deepen our understanding of how technology is influencing the profession.

Materials and Methods

We asked 14 questions through a Google Forms survey that was open to the community from 28/04/23-15/05/23 to establish a demographic of the study population including location and area of work. Further questions asked about access to technologies and attitudes towards learning about them.

Results

The survey received 100 responses from 13 countries. Respondents predominantly worked within academia, diagnostics, and pharmaceuticals (45%, 34% and 9% respectively). Technologies to which pathologists had a high rate of direct access included digital slide scanners (51%), online digital pathology image sharing platforms (43%), and digital image analysis software (42%). A high proportion of respondents (72%) had limited knowledge of natural language models such as chatGPT. Respondents rated educational content offered by the task force highly (median 7.5/ 10) and a high importance on learning about new technologies (median 9/10)

Conclusions

This survey gave important insights into the breadth of technologies to which pathologists have direct access. It also showed task force efforts to share knowledge about new technology are well received. We will continue to share new developments with the community. In the surveyed population, learning about new relevant technologies is regarded as highly important.

Poster Abstracts Veterinary Pathology

NEW METHODS, NEW TECHNOLOGY, TEACHING

82 | IMPACT OF LONG AND SHORT TERM CRYOPRESERVATION ON INTACTNESS OF PRECISION CUT LUNG SLICES

J. Krüger*, **S. Lockow***, **S. Becker***, **F. Freise†** and **W. Baumgärtner***

**Department of Pathology and †Department for Biometry, Epidemiology and Information Processing, University of Veterinary Medicine Hannover, Hanover, DE*

Introduction

Precision cut lung slices (PCLS) are ex vivo cell cultures, representing the organotypic 3D architecture of the lower respiratory tract. They were used successfully to study various infectious diseases and toxic effects, avoiding animal experiments. Public interest in animal welfare and EU legislation are increasing the need for more research into alternative methods like PCLS. Though it was shown that PCLS can be cryopreserved for several days, a detailed investigation on long-term cryopreservation is still missing.

Materials and Methods

Slices of agarose filled lungs from ferrets and pigs were screened for their base ciliary activity. After slowly cooling the PCLS to -80°C , they were stored in liquid nitrogen for 7 and 70 days. The non-cryopreserved control group was evaluated at 3 and 7 days post slicing and the cryopreserved tissues were evaluated at the corresponding time points after thawing. The ciliary activity of the PCLS was measured and a lactate dehydrogenase (LDH) assay was performed for functional analysis and viability. Degenerative changes were assessed using hematoxylin-eosin stained slices, immunohistochemistry and scanning electron microscopy.

Results

Cryopreserved PCLS displayed reduced ciliary activity compared to controls regardless of the time of storage in liquid nitrogen. LDH levels were lower in cryopreserved PCLS, which could be due to a reduced number of viable cells after cryopreservation. Pathomorphological changes included cell death and swelling in both cryopreserved and non-cryopreserved PCLS.

Conclusions

Though cryopreservation caused reduced basal ciliary activity and viability, cryopreserved PCLS still represent a useful tool to study infectious disease and toxic effects.

Acknowledgements: Funded by the Federal State of Lower Saxony (zukunfft.niedersachsen), R2N.

Poster Abstracts Veterinary Pathology

NEW METHODS, NEW TECHNOLOGY, TEACHING

193 | A BIO-INFORMATIC INVESTIGATION OF CATS' SUSCEPTIBILITY TO CORONAVIRUSES-DERIVING EPITOPES

M. Buonocore^{*†}, D. De Biase[†], D. Sorrentino[‡], A.M. D'Ursi[†], S. Papparella^{*}, A. Giordano[§] and O. Paciello^{*}

**Department of Veterinary Medicine and animal production, University of Naples "Federico II", Naples, IT, †Department of Pharmacy, University of Salerno, Fisciano, IT, ‡Department of Pharmacy, University of Salerno, IT and §Sbarro Institute for Cancer Research and Molecular Medicine, Temple University, Philadelphia, US*

Introduction

The mechanisms underlying the susceptibility to SARS-CoV-2 infection in humans and animals are still elusive, but a recent study demonstrated that different Class I/II human leukocyte antigen (HLA) alleles might define an individual susceptibility to SARS-CoV-2. Similarly, several studies suggested that the Feline Leukocyte Antigen (FLA) plays a pivotal role in the transmission of viruses to cats. With this study, we explored a novel bio-informatic approach in order to predict which FLA-I allele might be correlated with transmissibility potential and enhanced immunogenic response in domestic cats infected with FCoV and SARS-CoV-2.

Materials and Methods

We performed epitope mapping of amino acids deriving from SARS-CoV-2, FeCV and FIPV glycoproteins using the online server NetMHCpan 4.1 and predicted their affinities for different alleles of the three main loci in class I FLAs. The predicted complexes with the most promising affinities were then subjected to molecular docking and molecular dynamics simulations with HPepDock.

Results

Several epitopes were uniquely expressed by the examined proteins but others were only found on glycoproteins belonging to SARS-CoV-2. Moreover, alleles in the FLA-I H and E loci were responsive to epitopes deriving from replicase and spike proteins of the analyzed coronaviruses.

Conclusions

Our data provide a basis to further explore the interaction between the feline immune system and peptide vaccines able to prevent untreatable viral diseases. Moreover, our investigation may be used as a valid approach to predict other viral glycoproteins potentially immunogenic in a wide number of species.

Poster Abstracts Veterinary Pathology

NEW METHODS, NEW TECHNOLOGY, TEACHING

210 | COMPARISON OF DIGITAL COUNTING METHODS FOR KI67 STAINED MAST CELL TUMORS

N. Hungerbühler, P. Grest and C. Krudewig

Institute of Veterinary Pathology (IVPZ), University of Zürich, Zürich, CH

Introduction

Automated analysis of Ki67 expression is more and more commonly used in the daily routine diagnostics and prognostics of canine mast cell tumors. The purpose of this study was to compare different methods within the same tumour cohort and to find a practicable approach for the daily diagnostic routine.

Materials and Methods

FFPE tissue from 78 archived canine mast cell tumors served as material. Routinely Giemsa and Ki67 stained slides were scanned and aligned using Visiopharm® for selection of tumour tissue. Ki67 positive nuclei were counted on the whole slide (output: % of total nuclei) using different methods followed by construction of a heat map. Positive cells were then counted in the hot spots according to published literature for manual and automated counting.

Results

The workflows allowed standardised collection and comparison of the Ki67 index. Alignment of Giemsa and Ki67 stained slides was useful for the detection of tumour tissue. No significant differences were found between counting of positive cells within the whole tumor with/without exclusion of artefacts. Whole tumour counting correlated best with % positive cells per area concerning cases above the threshold. Visual control of the hot spots appeared necessary to avoid that melanophages and blood vessels might lead to false positives.

Conclusions

This study underlines the need of a standardized approach for the automated Ki67 counting in mast cell tumors, which allows comparison of different methods with fewer resources. Examination of a larger cohort is now needed to compare the different methods.

Poster Abstracts Veterinary Pathology

TUMOUR PATHOLOGY

2 | FATAL RHABDOMYOSARCOMA IN A ONE-YEAR-OLD DOG: A CASE REPORT

S. Turchetto*, **I. Mikinac†** and **H. Aupperle-Lellbach***

**Pathology Department, LABOKLIN GmbH & Co. KG, Bad Kissingen, DE and †AniCura Aachen GmbH, Aachen, DE*

Introduction

Rhabdomyosarcomas (RMSs) are malignant mesenchymal neoplasms of skeletal myocytes, characterized by variable locally aggressive behaviour and metastatic rate. Canine RMSs occur particularly in young animals and are most frequently documented in the larynx. This case report describes an aggressive and uncommonly localized subcutaneous RMS in a young dog with widespread metastases.

Materials and Methods

A 8-month-old Leonberger was presented with a mass on the forehead. Two months later, the dog developed hepatic, ovarian, and renal masses. Advanced imaging, histopathology, and immunohistochemistry were performed.

Results

Imaging revealed a 5 cm in diameter osteolytic mass on the forehead. Microscopically, infiltrative neoplasms composed of spindle-shaped to round cells arranged in streams and sheets, associated with areas of necrosis were found at the forehead and in the organs. Marked anisocytosis and anisokaryosis, multinucleated neoplastic cells, and more than 20 mitoses/10 HPF were seen. The neoplastic cells were strongly positive for desmin but smooth-muscle-actin and pan-cytokeratin negative. A diagnosis of embryonal RMS with widespread metastases was made.

Conclusions

This case represents a very uncommon, aggressive subcutaneous RMS with a poor outcome. The visceral masses were noticed after the subcutaneous lesion and were interpreted as metastases. Nevertheless, a multicentric RMS cannot be ruled out. RMS should be included in the differential diagnoses for subcutaneous masses in young dogs. Given the unfavourable prognosis, a thorough clinical examination is necessary, to permit complete resection and lymph node and distant organ evaluation in search for metastases.

Poster Abstracts Veterinary Pathology

TUMOUR PATHOLOGY

6 | GENE EXPRESSION PROFILING ON FORMALIN-FIXED, PARAFFIN-EMBEDDED (FFPE) CANINE TUMOUR TISSUE-HOW DO LEXOGEN'S QUANTSEQ 3' AND NANOSTRING'S NCOUNTER COMPARE?

A.F.H. Haake*, **A.K. Langenhagen***, **S. Andreotti†** and **A.D. Gruber***

**Institute of Veterinary Pathology and †Bioinformatics Solution Center, Freie Universität Berlin, Berlin, DE*

Introduction

The QuantSeq and nCounter technologies are contemporary high throughput screening methods for transcriptome analyses. QuantSeq generates whole transcriptome libraries from the 3'-end and nCounter is an RNA hybridisation assay which allows approximately 800 genes to be analysed. As both technologies enable analyses using short sequences, they are well suited for FFPE material. Here, the two methods were compared on multiple levels using analyses of two different canine tumour types.

Materials and Methods

25 FFPE samples from 21 dogs were selected from archival cases. RNA from 10 hepatoid gland adenomas and 15 apocrine gland anal sac adenocarcinomas was extracted and analysed with QuantSeq and the nCounter Canine IO Panel. Normalisation and differential gene expression analysis ensued and the Pearson correlation coefficient was calculated.

Results

Of the 830 nCounter genes, 821 genes were found in the QuantSeq data. A sample-wise count correlation of 0.86 was ascertained. The gene-wise count correlation was 0.74, however there was a much larger distribution of correlations depending on the expression levels of individual genes. A correlation of 0.84 was determined for the log2FoldChange values. A total of 182 significantly differentially expressed genes (sDEG) for nCounter and 201 for QuantSeq were calculated; an overlap of 141 sDEG was found (Jaccard index: 0.58).

Conclusions

Despite the platforms' technological differences, the very strong to moderately strong correlations on the different levels investigated show that the data can be used for reciprocal validation of results. Both methods generated overall similar findings when comparing the overlapping subset of investigated genes.

Poster Abstracts Veterinary Pathology

TUMOUR PATHOLOGY

8 | TOPOISOMERASE II ALPHA IMMUNOEXPRESSION AS A POTENTIAL PREDICTOR OF ANTHRACYCLINE CHEMOTHERAPY IN CATS WITH INJECTION-SITE SARCOMA

W. Łopuszyński*, **K. Bulak***, **A. Śmiech***, **A. Puła*** and **A. Marcinowska†**

**Department of Pathomorphology and Forensic Veterinary Medicine, University of Life Sciences, Lublin, PL and †University Centre of Veterinary Medicine, University of Agriculture, Krakow, PL*

Introduction

Feline injection-site sarcomas (FISSs) are mesenchymal tumours that develop in cats following vaccination or injection with various medications. FISSs appear to be moderately chemosensitive, and the use of adjuvant or neoadjuvant anthracycline chemotherapy has been proposed to complement surgery. Unfortunately, there are no specific indications for the use of anthracyclines in individual patients. Topoisomerase II α (TOPII α) is a key enzyme in DNA replication and a molecular target for TOPII α inhibitors, including the most commonly used anthracyclines such as doxorubicin and epirubicin. This study aimed to evaluate the expression of TOPII α in FISSs, considering the suitability of this assessment for the selection of patients for the treatment with TOPII α inhibitors.

Materials and Methods

Samples of formalin-fixed paraffin-embedded FISSs were immunohistochemically labeled with anti-TOPII α antibody. The number of positive cells and the intensity of the reaction were taken into account in order to assess TOPII α .

Results

TOPII α expression was evident in neoplastic fibroblasts in all cases, although differences in the number of positive cells and the intensity of the reaction were shown. Moreover, differences were observed between individual cases. These were independent of the anatomical location of tumours.

Conclusions

It can be assumed that FISSs with elevated level of TOPII α immunoreactivity might respond better to anthracycline chemotherapy than tumours with low immunoreactivity of this enzyme. Therefore, it can be hypothesized that the assessment of TOPII α immunoreactivity in FISSs may represent a predicting factor for adjuvant or neoadjuvant treatment with drugs interfering with TOPII α function, including doxorubicin and epirubicin.

Poster Abstracts Veterinary Pathology

TUMOUR PATHOLOGY

13 | INTERSPECIES SIMILARITIES BETWEEN CANINE AND HUMAN MAMMARY CANCER

M. Levkut^{*}, V. Tancoš[†], M. Kovalík[‡] and L. Plank[§]

^{}Morphological discipline, University of Veterinary Medicine and Pharmacy and [†]Institute of Pathology, UPJŠ and Louis Pasteur University Hospital, Košice, SK, [‡]Anima Groups, Veterinary Hospital Anima Vets, Žilina, SK and [§]Pathological anatomy, Jessenius Faculty of Medicine, Comenius University, Bratislava, SK*

Introduction

Mammary cancer is characterized by variability of histopathological characteristics and in options of therapeutic management. This study determined interspecies similarities between canine and human mammary cancer with respect to innovative predictive and prognostic tumour markers.

Materials and Methods

Surgical resection specimens with diagnosed spontaneous primary mammary cancer (MA) obtained from 100 female canine patients were included. Histopathological grading was performed using the Nottingham/modified Bloom-Richardson system. For IHC, antibodies against carbonic anhydrase IX (CAIX), human epidermal growth factor receptor 2 (HER2), smooth muscle actin (SMA), and Ki67 (indicator of cell proliferation) were used.

Results

As in humans, CAIX positivity in tumour cells in canine MA significantly correlated with higher levels of HER2 immunoreactivity ($P = 0.001$), and increased tumour grade ($P < 0.001$). The percentage of SMA positive cases was significantly higher ($P = 0.002$) in the group of mammary carcinomas with CAIX positivity compared to the tumours that were CAIX negative. The Ki67-determined proliferative activity did not differ significantly between CAIX positive and CAIX negative tumours.

Conclusions

Canine mammary gland carcinomas may represent valuable animal models for the study of hypoxic signalling pathways involved in mammary carcinogenesis in humans.

Acknowledgements: The study was supported by National grant agency VEGA number 1/0107/21.

Poster Abstracts Veterinary Pathology

TUMOUR PATHOLOGY

14 | COMPARISON OF IMMUNOHISTOCHEMICAL EXPRESSION OF CYCLOOXYGENASE-2 (COX-2) BETWEEN CANINE AND EQUINE MELANOMAS

J. Pimenta^{*†}, J. Prada^{*†}, A. Garcia[‡], F. Queiroga^{*†}, I. Pires^{*†} and M. Cotovio^{*†}

^{}Veterinary Sciences Department and [†]CECAV-Veterinary and Animal Research Centre, University of Trás-os-Montes e Alto Douro, Vila Real, PT and [‡]Veterinary Hospital +Ani+, Maia, PT*

Introduction

Equine melanoma has a benign behavior (mass growth without vertical invasion, rare metastatic spread). Canine melanoma is highly invasive with high metastatic rates. COX-2 is an enzyme implicated in tumour proliferation, angiogenesis and invasion. This study compared its immunohistochemical expression in canine and equine melanomas and correlated the expression with the clinical behaviour of these tumors.

Materials and Methods

38 equine and 31 canine melanomas were immunohistochemically stained for COX-2 and scored for the extent of expression in 0) negative; 1) 1-19%; 2) 20-50%; 3) >50% and intensity of labelling in 0-negative, 1-weak, 2-moderate, 3-strong. A final score was calculated multiplying extension by intensity of labelling with <6 being classified as weak and ≥6 as strong expression.

Results

Among the equine melanomas were 26.3% with high COX-2 whereas 39% of the canine melanomas exhibited high COX-2 expression. There was a statistically significant difference between species ($p=0.021$) regarding the COX-2 final score, with horses presenting more scores of low expression (<6) and dogs presenting more scores of high expression (≥6) but also more negative tumors. However, there were no significant differences in equine (3.37 ± 2.51) and canine (3.71 ± 3.15) COX-2 final score means ($p=0.778$).

Conclusions

Equine melanomas show less expression of COX-2, which agrees with their less invasive behaviour. COX-2 in canine melanomas varies more between absent or very high expression. COX-2 might act differently and have a major role in proliferation in equine melanomas, contributing to mass growth, while it might play a role in invasion and metastasis in canine melanomas.

Acknowledgements: This work was supported by the projects UIDB/00772/2020 and LA/P/0059/2020 funded by the Portuguese Foundation for Science and Technology (FCT).

Poster Abstracts Veterinary Pathology

TUMOUR PATHOLOGY

19 | CLINICAL AND PATHOLOGICAL FEATURES AND OUTCOME OF A HOOF MELANOMA IN AN ANDALUSIAN BAY GELDING

F. Bulnes^{*}, K. García-Álamo[†], D. Argüelles[‡], I. Rodríguez-Gómez[§], G. Herrera[§], E. Hernández[‡] and E. Mozos[§]

^{}Department of Large Animal Surgery, Veterinary Teaching Hospital Universidad de Córdoba, [†]Department of Large Animal Surgery, Veterinary Teaching Hospital Universidad de Córdoba and [‡]Department of Large Animal Surgery and Medicine and [§]Department of Anatomy, Comparative Pathology and Toxicology, University of Córdoba, Córdoba, ES*

Introduction

Melanomas involving the horse foot are poorly described. Their diagnosis was usually established based on signalement and postmortem examination. Here we describe the clinical and histopathological features of a hoof melanoma with dermo-epidermal activity.

Materials and Methods

A 12-year-old bay Andalusian gelding presented with lameness of the right forelimb and history of recurrent abscesses involving the lateral aspect of the hoof wall. When a keratoma removal was performed, a poorly defined plaque-like pigmented lesion, 2 x 2 x 0.4 cm in size, was found lateral at the coronary band, extending to the proximal lamellar tissue. A partial resection of the hoof wall was performed, and a biopsy submitted for histopathology. Six months after surgical resection and chemotherapy, new biopsies were taken.

Results

A melanocytic tumour, characterised by small nests of large polygonal or epithelioid cells infiltrating the basal and suprabasal epidermis, the dermo-epidermal junction, and the superficial dermis, was observed. The cells exhibited euchromatic nuclei, prominent nucleoli, moderate pleomorphism and mitotic index and variable amounts of melanin in the cytoplasm. There were numerous peritumoural macrophages. The immunophenotype of the tumour cells was PNL2+++ , S100++ , AE1-AE3-. A diagnosis of melanoma with dermo-epidermal activity was made. The later biopsies showed partial tumour regression and healing.

Conclusions

A melanoma with dermo-epidermal activity has not yet been reported in horses. The classification and prognostic factors of equine melanomas remain insufficient and more clinical, pathological, and molecular data are needed, taking the classification of human melanomas as an example.

Acknowledgements: This work has been funded by the Andalusian Research Groups PAIDI AGR262 and Equine Sport Medicine AGR011

Poster Abstracts Veterinary Pathology

TUMOUR PATHOLOGY

21 | DEVELOPMENT OF A RADIORESISTANT CANINE GLIOMA CELL LINE

R.F. Strefezi*†, L.Y. Pang† and D.J. Argyle†

**Laboratório de Oncologia Comparada e Translocacional, Faculdade de Zootecnia e Engenharia de Alimentos, Universidade de São Paulo, Pirassununga, BR and †The Royal (Dick) School of Veterinary Studies and Roslin Institute, Edinburgh, GB*

Introduction

Malignant gliomas are aggressive brain tumours that affect humans and dogs. The prognosis for this disease is poor in both species, despite surgical, chemo and radiotherapeutic treatments. Radiotherapy is an important treatment modality for brain tumours but its efficacy is mostly limited by radioresistance, which is believed to be mediated by tumour-initiating cells that are able to recapitulate the tumour. The objective of this research was to establish a canine radioresistant glioma cell line for future studies on radioresistance.

Materials and Methods

Canine glioma cells (J3T, ATCC, Middlesex, UK) were cultured in Dulbecco's modified Eagle's medium supplemented with 10% foetal bovine serum and 1% penicillin/streptomycin. After receiving an initial dose of 7 Gy, the cells were treated with incremental doses of 1 Gy. Colony formation, cell viability and migration assays were used to compare the irradiated cells (J3T-RR) with the parental cell line (J3T) to confirm radioresistance.

Results

During 21 weeks, J3T-RR cells were submitted to a total dose of radiation of 112 Gy. The J3T-RR cell line showed higher resistance in colony formation assays after exposure to a single radiation dose of up to 6 Gy ($p < 0.0001$). J3T-RR cell migration was also faster ($p < 0.0001$) and cell viability was higher ($p < 0.0001$) than in the parental J3T cell line when exposed to radiation doses up to 5 Gy.

Conclusions

We have successfully generated a radioresistant canine glioma cell line that will be useful for mechanistic studies and the development of rational treatments against radiation resistance in cancer.

Acknowledgements: Fundação de Amparo à Pesquisa do Estado de São Paulo (grant #2019/27144-9).

Poster Abstracts Veterinary Pathology

TUMOUR PATHOLOGY

23 | SIGNET-RING CARCINOMA IN AN ILE-DE-FRANCE EWE

N. Caliskan*, **R. Ducatelle†**, **F. Smeets‡** and **S. Roels***

**Pathology, Laboratory Dierengezondheidszorg Vlaanderen (DGZ), Torhout, BE, †Pathobiology, Pharmacology and Zoological Medicine, Ghent University, Faculty of Veterinary Medicine, Merelbeke, BE and ‡Pathology, Association Régionale de Santé et d'Identification Animale (ARSIA), Ciney, BE*

Introduction

Signet-ring carcinoma represents a subclass of intestinal adenocarcinomas in domestic animals. This histological subtype has only been reported sporadically in sheep.

Materials and Methods

Full necropsy was performed on a 4-year-old Ile-de-France ewe. The owner had noted progressive weight loss over a period of several months. Samples were collected and processed for histology. Sections were routinely stained with HE and periodic acid-Schiff (PAS).

Results

During necropsy, multiple thickenings alongside the serosa of the small intestine, also affecting the intestinal wall itself, and within the mesentery were observed. The lesions ranged from numerous small pinpoint, whitish and firm serosal nodules to diffuse circumferential thickening of the intestinal wall with partial luminal occlusion. Histology confirmed an infiltrative neoplastic process. The neoplastic cells, forming haphazardly arranged tubules and islands, were surrounded by a pronounced scirrhous reaction in some areas. A large number of the neoplastic epithelial cells were filled with cytoplasmic PAS positive material (mucin). The neoplastic cells occasionally surrounded lakes of mucus. Disseminated within the neoplasm were rounded and enlarged neoplastic cells with vacuolated amphophilic cytoplasm compressing the nucleus (signet ring cells). Lymphatic or vascular invasion was not observed.

Conclusions

The diagnosis of a primary signet-ring carcinoma within the small intestinal tract was made. In sheep, they tend to be highly infiltrative and may show regional nodal involvement. Animals are also at risk of developing peritoneal carcinomatosis. There is ongoing debate on potential developmental predisposing factors in sheep, but due to chronic wasting, there is an economic importance.

Poster Abstracts Veterinary Pathology

TUMOUR PATHOLOGY

25 | EXPRESSION OF MATRIX METALLOPROTEINASES -2, -9, -13, -14 IN CANINE MAMMARY CARCINOMA

O.M. Hritcu*, **F. Daraban Bocaneti†**, **T. Soare‡**, **R.I. Rizac§**, **M. Militaru§** and **A.S. Pasca***

**Pathology and †Infectious Diseases, Iasi University of Life Sciences, ‡Pathology, University of Agronomic Sciences and Veterinary Medicine of Bucharest, Iasi, RO and §Pathology, University of Agronomic Sciences and Veterinary Medicine of Bucharest, Bucharest, RO*

Introduction

Mammary carcinomas are among the most frequent canine tumours, generally characterized by poor prognosis. Matrix metalloproteinases are enzymes that reorganize the extracellular matrix to increase its permeability for cells. They are frequently expressed in malignant tumours, allowing for higher invasiveness and neoangiogenesis.

Materials and Methods

Twelve canine mammary carcinoma samples (one per patient) were harvested, fixed in a 10% formalin solution, embedded in paraffin, sectioned at 3 µm and subjected to the Masson trichrome stain or immunohistochemical staining for MMP-2, MMP-9, MMP-13 and MMP-14. Immunoreactivity was scored as follows: negative, + weak, ++ moderate, +++ strong positivity.

Results

All MMPs were expressed in all samples, both in the cytoplasm of mammary epithelial and stromal cells, with variable expression intensity. MMP-2: 2 (16.7 %) weak, 5 (41.65 %) moderate and 5 (41.65%) strong; MMP-9: 2 (16.7%) weak, 6 (50%) moderate and 4 (33.3%) strong; MMP-13: 2 (16.7%) weak, 4 (33.3%) moderate and 6 (50%) strong; MMP-14: 4 (33.3%) weak, 6 (50%) moderate and 2 (16.7%) strong.

Conclusions

The expression of MMP-2, MMP-9 and MMP-13 detected in carcinomas may suggest a possible link to the permeabilization of basal membranes and invasive behaviour. Moreover, MMP-13 is known to promote cancer growth, invasion, metastasis and angiogenesis, while MMP-14 has been linked to cancer cell motility and tumour growth. The expression of the aforementioned MMPs in mammary carcinomas may be a helpful indicator of future tumour development and prognosis.

Acknowledgements: This research was funded by Iasi University of Life Sciences.

Poster Abstracts Veterinary Pathology

TUMOUR PATHOLOGY

33 | RETROSPECTIVE EPIDEMIOLOGICAL ANALYSIS OF CANINE MAST CELL TUMOURS SUGGESTS AGE AND BREED AS RISK FACTORS

J. Catarino^{*†}, K. Pinello[‡], J. Niza-Ribeiro[‡], J. Santos^{*†}, R. Payan-Carreira^{§¶}, J. Reis[‡] and P. Faísca^{*†}

^{}Faculty of Veterinary Medicine, Lusófona University and [†]DNATECH, Lisbon, PT, [‡]Vet-OncoNet, Department of Population Studies, School of Medicine and Biomedical Sciences (ICBAS), Porto, PT, [§]Comprehensive Health Research Centre (CHRC) and [¶]Department of Veterinary Medicine, Evora University, Évora, PT and [‡]CISAS & IPVC, Polytechnic Institute of Viana do Castelo, Viana do Castelo, PT*

Introduction

Mast cell tumors (MCT) are among the most common malignant tumours in dogs, however, information about risk factors is sparse. The current study aimed to identify risk factors associated with the development of MCTs.

Materials and Methods

A retrospective study was undertaken on MCTs diagnosed at the DNAtch Veterinary Laboratory between 2017 and 2021. Data on age, sex, breed, anatomical location, and postal code of the requesting clinic was collected from 905 MCTs. Descriptive and inferential analyses were performed. Incidence Risk (IR) and Relative Risk (RR) were calculated using the canine population registered in the Portuguese companion animal registry system (SIAC).

Results

The mean age at diagnosis was 8.3SD=2.9 years. For sex, there was no predilection and no differences in the mean ages. Mixed-breed dogs were most frequently affected (n=309, 34.1%) followed by Labrador Retriever (197, 21.7%), Boxer (67, 6.7%), and French Bulldog (64, 6.0%). The latter had the lowest mean age (6.83SD=2.5) while Beagles had the highest (10.3SD=2.3, p<0.05). Regarding anatomical location, MCTs were most frequently diagnosed in the skin of the hindlimb (136, 15.0%). Scrotal MCTs showed a statistically significant tendency to occur in older animals (p=0.01) when compared to other locations. Using SIAC's population, an annual IR of 9.3 cases of MCTs/10,000 dogs was calculated. Compared to mixed-breed dogs, Boxers had the highest RR (7.1, p<0.001) followed by Shar-pei (6.3, p<0.001) and Golden Retrievers (5.9, p<0.001).

Conclusions

These results suggest age and breed as risk factors for the development of canine MCT.

Poster Abstracts Veterinary Pathology

TUMOUR PATHOLOGY

38 | AUTOPHAGY MARKERS IN CANINE MAST CELL TUMOURS

G.P.Vicente*, **L. Della Salda†** and **R.F. Strefezzi***

**Laboratório de Oncologia Comparada e Translacional, Faculdade de Zootecnia e Engenharia de Alimentos, Universidade de São Paulo, Pirassununga, BR and †Facoltà di Medicina Veterinaria, Università degli Studi di Teramo (UNITE), Teramo, IT*

Introduction

Mast cell tumours (MCT) are frequent malignant neoplasms in dogs. The diagnosis is based on cytological and histopathological examination, which also provides valuable prognostic information. However, more precise prognostic markers are needed to improve the treatment and survival of the patients. Autophagy is a catabolic process that contributes to cancer cell survival, senescence, immune evasion and recurrence. Beclin-1 and LC3B are proteins that are responsible for the elongation of the autophagosome and thus can be used to evaluate autophagy. The current study investigated the occurrence of autophagy in MCTs and evaluated it as a potential prognostic indicator.

Materials and Methods

Beclin-1 and LC3B expression was evaluated in MCT samples using immunohistochemistry (IHC), transmission electron microscopy (TEM) and immunoelectron microscopy (IEM). An anti-Beclin-1 antibody (clone OT11F1) was used for IHC and IEM and an anti-LC3B antibody for IHC. Secondary antibody for IEM was a 10 nm⁻¹ globulin goat anti-mouse-gold particle complex.

Results

Thirty-one samples were evaluated for Beclin-1 expression and 43 for LC3B expression. Beclin-1 presented two immunostaining patterns: diffuse cytoplasmic or granular perinuclear. TEM confirmed the presence of autophagic vacuoles in MCT cells and IEM revealed that Beclin-1 was present in different locations. LC3B staining patterns were diffuse cytoplasmic or granular. Dogs with MCTs that showed a granular LC3B expression pattern had a shorter survival time ($p=0.0409$).

Conclusions

Beclin-1 and LC3B are expressed by canine MCTs with variable intensity and staining patterns. The results suggest that LC3B expression can serve as a prognostic marker for the disease.

Acknowledgements: Fundação de Amparo à Pesquisa do Estado de São Paulo (FAPESP, grants #2020/10582-0, #2021/02772-7 and #2021/14065-3); Conselho Nacional de Desenvolvimento Científico e Tecnológico (CNPq) (grant #303748/2021-4).

Poster Abstracts Veterinary Pathology

TUMOUR PATHOLOGY

52 | DECORIN EXPRESSION IN INFLAMMATORY AND NON-INFLAMMATORY CANINE MAMMARY CARCINOMAS

B.A. Gouveia^{*†}, F.R. Ramos^{*}, I.K.L. Silva^{*}, L.B. Paskoski^{*}, R.O. Vasconcelos[‡], J.G. Xavier[§] and R.F. Strefezi^{*}

^{}Laboratório de Oncologia Comparada e Translacional, Faculdade de Zootecnia e Engenharia de Alimentos, Universidade de São Paulo, Pirassununga, BR, [†]Departamento de Patologia, Faculdade de Medicina Veterinária e Zootecnia, Universidade de São Paulo and [‡]Serviço de Patologia Veterinária, Departamento de Patologia, Reprodução e Saúde Única, Faculdade de Ciências Agrárias e Veterinárias, UNESP, Jaboticabal, BR and [§]Universidade Paulista (UNIP), São Paulo, BR*

Introduction

Mammary gland tumours are frequent in bitches, and among them, inflammatory mammary carcinoma (IMC) stands out for malignancy. IMCs are characterised by rapid and invasive growth and are highly metastatic both in dogs and humans. Decorin (DCN) is an extracellular matrix (ECM) protein that influences several cellular pathways, controlling tumorigenesis and regulating tumoural growth and metastasis in murine IMC models. However, there are only a few studies on this subject in the canine species. This research aimed to evaluate DCN expression in IMCs and non-inflammatory mammary carcinomas (NIMC).

Materials and Methods

Forty-one cases of NIMC and 28 of IMC were subjected to immunohistochemistry to detect DCN using a rabbit polyclonal anti-DCN primary antibody (NBP1-57923, Novusbio[®]). Five images from random high-power fields (40x objective) and from 5 hot spots were captured from intratumoural areas for each case. Immunostaining was evaluated in scores regarding the percentage of the ECM-positive area and intensity.

Results

The most frequent histological subtypes were solid-type carcinoma and comedocarcinoma (6/28, 21.4% each) among the IMCs, and complex carcinoma (17/41, 41.5%) in the NIMCs group. We observed lower expression of DCN in IMCs compared with NIMCs, both in random and hot spot evaluations considering the scores for area ($p=0.0015$ and $p=0.0002$, respectively) and intensity ($p=0.0006$ and $p=0.0003$, respectively).

Conclusions

IMCs express lower levels of DCN than NIMCs. These results suggest that DCN may have important roles in canine mammary carcinomas and be a potential prognostic marker for the disease.

Acknowledgements: Fundação de Amparo à Pesquisa do Estado de São Paulo (grants #2021/14542-6 and #2020/10582-0); Conselho Nacional de Desenvolvimento Científico e Tecnológico - CNPq (grant #303748/2021-4); CAPES (código de financiamento 001).

Poster Abstracts Veterinary Pathology

TUMOUR PATHOLOGY

54 | A RARE CASE OF ILEOCECAL MALIGNANT PERIPHERAL NERVE SHEATH TUMOUR IN A CAT

H. Fattahian*, **H. Azarabad†**, **N. Mansouri*** and **K. Mansouri***

**Clinical sciences, Islamic Azad University, Science and Research branch, Faculty of specialized veterinary sciences and †Patholgy, Hamidreza Fattahian small animal hospital, Tehran, IR*

Introduction

The most common feline intestinal neoplasms are lymphoma, adenocarcinoma, and mast-cell tumour respectively. Malignant peripheral nerve sheath tumours (MPNST) are a rare entity in old cats. This report aims to add to the limited diagnostic and therapeutic data available in the veterinary literature by describing a rare case of ileocecal MPNST.

Materials and Methods

A 12-year-old spayed female debilitated domestic short-hair cat was brought in to investigate vomiting, lethargy, and anorexia. Haematology and serum biochemistry were within normal limits. Ultrasonography revealed heterogeneous peritoneal effusion. An exploratory laparotomy was performed for further diagnostic and therapeutic purposes. At surgery, after aspiration of a copious amount of serosanguineous fluid, a firm, well-circumscribed round mass was unveiled in the ileocecal area extending to the adjacent mesentery. The intramural mass was obstructing almost the entire gastrointestinal lumen. Surgical resection and end-to-end anastomosis were performed. The cat recovered uneventfully and was discharged a few hours later. Cytological (peritoneal fluid) and histological and immunohistochemical examinations (mass) were undertaken.

Results

Peritoneal fluid cytology showed a mixture of inflammatory and reactive mesothelial cells. Histology revealed large hypocellular and hypercellular areas composed of uniform spindle cells with wavy to buckled nuclei. Immunohistochemically, the tumour cells exhibited strong and diffuse positive staining for S-100 and vimentin.

Conclusions

The histopathologic and immunohistochemical features were consistent with MPNST. The patient remained well with no pertaining clinical signs 3 months after the initial diagnosis. Reports describing malignant visceral PNST in cats are scant, therefore, the prognosis and optimal treatments are not fully determined.

Poster Abstracts Veterinary Pathology

TUMOUR PATHOLOGY

55 | POORLY DIFFERENTIATED CERVICAL RHABDOMYOSARCOMA IN AN ADULT DOG

H. Fattahian*, **H. Azarabad†**, **K. Mansouri*** and **N. Mansouri***

**Clinical sciences, Islamic Azad University, Science and Research branch, Faculty of specialized veterinary sciences and †Patholgy, Hamidreza Fattahian small animal hospital, Tehran, IR*

Introduction

Soft tissue sarcomas make up approximately 80% of sarcomas in dogs, the most common of which are haemangiosarcoma, fibrosarcoma, peripheral nerve sheath tumour, and histiocytic sarcoma. Rhabdomyosarcoma (RMS) accounts for only 0.1 % of all canine sarcomas. This report presents a unique case of concomitant occurrence of stump pyometra and rhabdomyosarcoma arising from the uterine cervix.

Materials and Methods

A 7-year-old female mongrel, ovariectomized 6 years ago, was presented for evaluation of prolonged serosanguineous vaginal discharge, galactorrhea and vulvar swelling. Abdominal ultrasound revealed bilateral remnant cystic ovaries and a caudal abdominal lesion with abundant echogenic content. Exploratory laparotomy revealed a mass, approximately 12x8 cm in diameter, containing suppurative malodorous discharge in the location of uterus, adhering to the serosa of the urinary bladder. The mass was removed surgically and submitted for histopathologic analysis.

Results

Microscopically, the mass was composed of trabeculae of round cells that formed an alveolar-like appearance with fibrovascular septa. Mitotic figures and areas of tumour necrosis were present. Immunohistochemical evaluation demonstrated cytoplasmic expression of desmin and vimentin. The owner refused chemotherapy and CT-scan to rule out lung metastasis.

Conclusions

Based on the histopathologic and immunohistochemical findings, the tumour was diagnosed as alveolar rhabdomyosarcoma. To date, the patient survived but vaginal discharge persisted. The relative rarity of this tumour makes diagnosis, clinical prognosis, and treatment difficult.

Poster Abstracts Veterinary Pathology

TUMOUR PATHOLOGY

61 | DETECTION OF FELINE VIRAL LEUKAEMIA PROVIRUS DNA BY REAL-TIME PCR IN PARAFFIN EMBEDDED TISSUE OF FELINE LYMPHOMAS DIAGNOSED IN A REFERENCE LABORATORY IN MEXICO CITY, FROM 2006 TO 2018

D. Rivera-Colín*, **J.M. Pérez-Eriquez***, **R. Alonso-Morales†**, **J.P. Pintor-Ríos†** and **L.P. Romero-Romero***

**Departamento de Patología and †Departamento de Genética y Bioestadística, Facultad de Medicina Veterinaria y Zootecnia, Universidad Nacional Autónoma de México, Mexico City, MX*

Introduction

Feline leukaemia virus (FeLV) integration into the genome of infected cats can be associated with the development of neoplasms. A retrospective study of feline lymphomas was performed to detect the FeLV provirus by qPCR, in order to determine the correlation between its presence in neoplastic tissue, the anatomical location of the lymphoma, and the age at presentation.

Materials and Methods

Feline lymphomas previously diagnosed in the Department of Pathology of the FMVZ-UNAM between 2006 and 2018 were classified according to their anatomical location. DNA was extracted (DNeasy blood & tissue, Qiagen®, Germany) from paraffin embedded tissue samples and a qPCR performed to detect the U3-LTR region of FeLV, a conserved exogenous provirus segment (FIND-IT Feline Leukemia SuperMix, Molecular Biologies®, BioTecMol, Mexico). Results were interpreted with Rotor-Gene Q Series Software 2.3.1.

Results

A total of 77 feline lymphoma cases were found in the study period, 16/77 (20.77%) were positive for FeLV provirus; 11 of these occurred in cats under 2 years of age and were classified as mediastinal (6), multicentric (4) and alimentary (1). A statistically significant correlation was found between anatomical location and presence of FeLV provirus ($P=0.001$). There was also a statistical correlation between the presence of FeLV provirus and the age of the animal ($P = 0.000067$); geriatric animals were all negative for FeLV.

Conclusions

This study indicates a significant association between the presence of the FeLV provirus and lymphomas in cats under 2 years of age, and with mediastinal and multicentric anatomical location.

Poster Abstracts Veterinary Pathology

TUMOUR PATHOLOGY

62 | SYSTEMIC AMYLOIDOSIS SECONDARY TO SPINDLE CELL SARCOMA IN A PATIENT WITH NEPHROTIC SYNDROME

D. Rivera-Colín*, **B. González-Jiménez***, **B.L. Gómez-Montes†**, **G. Ramírez-Díaz***, **J. Aguilar-Bobadilla†**, **J. Quiroz-Mercado†**, **P.A. Moya-Bautista*** and **A. Reyes-Matute***

**Departamento de Patología and †Hospital Veterinario de Especialidades, Facultad de Medicina Veterinaria y Zootecnia, Universidad Nacional Autónoma de México, Mexico City, MX*

Introduction

Here we describe the clinical-pathological aspects of systemic amyloidosis and nephrotic syndrome in a dog with a concurrent liver sarcoma.

Materials and Methods

An 8-year-old male castrated crossbreed dog was presented to the FMVZ-UNAM Teaching hospital with abdominal distension and proteinuria. Blood count, clinical chemistry, ultrasound and an incisional renal biopsy were performed. Due to worsening of clinical signs, euthanasia was elected and a complete post mortem and a histological examination were carried out.

Results

Clinically, the dog presented with ascites, hypertension and hyperechoic lesions in the liver. Laboratory tests showed non-regenerative anaemia, hypercholesterolaemia, hypoproteinaemia and severe proteinuria. The renal biopsy showed glomerular amyloidosis. During the following 5 months the patient received treatment to control hypertension and thrombosis and was supplemented with oral albumin but deteriorated progressively and euthanasia was elected. The post mortem examination revealed systemic amyloidosis, a spindle cell sarcoma in the liver, and pulmonary thrombosis. The amyloid was resistant to permanganate treatment prior to the Congo red stain, which was consistent with AA amyloidosis.

Conclusions

Although AA amyloidosis is associated with systemic inflammation, it is known that patients with malignant neoplasms may develop high levels of serum amyloid A (SAA) leading to systemic amyloidosis. Information on the association between cancer and amyloidosis is scarce, but it is possible that liver sarcomas might represent a source of amyloid. In the present case, pulmonary thrombosis was likely related to loss of proteins through the kidney due to vascular leakage as a consequence of amyloid deposition.

Poster Abstracts Veterinary Pathology

TUMOUR PATHOLOGY

63 | COMPARATIVE ANALYSIS OF CANINE LYMPHOMAS DIAGNOSED AT THE DEPARTMENT OF VETERINARY PATHOLOGY, FACULTY OF VETERINARY MEDICINE, UNIVERSITY OF ZAGREB

M. Hohšteter*, L. Medven Zagradišnik*, M. Matasović†, I.C. Šoštarčić-Zuckermann*, B. Artuković*, D. Huber*, D. Vlahović* and A. Gudan Kurilj*

**Department of Veterinary Pathology, Faculty of Veterinary Medicine, University of Zagreb and †Vet Point, Veterinary Practice, Zagreb, HR*

Introduction

Lymphomas are the most common canine haematopoietic tumours. This research presents the analysis of canine lymphomas diagnosed at the Department of Veterinary Pathology, Faculty of Veterinary Medicine, Zagreb (DVP). The aim was to gain insight into the incidence and characteristics of canine lymphoma in Croatia.

Materials and Methods

The research included records of the cytological (CY), histopathological (HP), immunocytochemical (ICC) and immunohistochemical (IHC) examinations of the DVP in the period 2009-2021.

Results

Lymphoma was diagnosed in 1.1% of dogs by CY, HP, and confirmed by ICC/IHC, and was suspected in 0.72% (without ICC/IHC confirmation). The majority of dogs (54%) were 5-9 years old; 60.7% were males, and 39.9% were females. Regarding breed, 26.0% were crossbreeds, while 74.0% were purebred, most frequently Bouvier des Flandres (40%), Bullmastiff (6.9%), Shar Pei (6.5%), and Samoyed (4.9%). The Maltese (0.5%), West Highland and Yorkshire terriers (0.7%) had the lowest share of lymphoma. According to the anatomical location, the most common were multicentric (17.4%), and the rarest extranodal lymphoma (1.2%). Immunophenotyping was performed in 31.4%, and 50.0% were B-cell, 43.4% T-cell, 5.3% T-cell-rich B-cell and 1.3% non-T non-B cell lymphomas.

Conclusions

The distribution of lymphomas regarding age, sex and breed corresponds to the literature. As in the literature, B-cell lymphomas were most prevalent but with a lower percentage. However, immunophenotyping of a larger number of lymphomas would probably increase the proportion of B-cell lymphomas. Owners should be encouraged to agree to immunophenotyping for accurate diagnosis, allowing a more accurate prognosis and therapy.

Poster Abstracts Veterinary Pathology

TUMOUR PATHOLOGY

65 | TWO ATYPICAL CASES OF FELINE RESTRICTIVE ORBITAL MYOFIBROBLASTIC SARCOMA (FROMS) INITIALLY PRESENTING AS ORAL MASSES

S. Gasparini*, **C. Stefanello†**, **A. Costa‡**, **L. Negro‡** and **L. Nordio***

**Pathology division, †Odontostomatology division and ‡Diagnostic and Interventional Radiology Division, San Marco Veterinary Clinic and Laboratory, IT*

Introduction

Feline restrictive orbital myofibroblastic sarcoma (FROMS) is an entity with a progressive clinical course and a poor prognosis, despite a morphology characterized by well-differentiated neoplastic spindle cells resembling reactive fibroblasts. FROMS typically arises as thickening of the orbit and midfacial region, and, in late stages, involves the contralateral eye up to the entire face, often extending into the oral cavity. We describe two cases of FROMS initially presenting as oral masses.

Materials and Methods

Two female European short-haired cats, aged 7.5 years (case 1) and 16 years (case 2), were presented with gingival masses involving the maxillae, without ocular involvement. CT scan to confirm the clinical localization and surgical biopsies were performed; biopsies were analyzed by histology and immunohistochemistry.

Results

Histologically, both cases were characterized by a proliferation of bundles of spindle cells with mild atypia. In both cases, neoplastic cells were diffusely vimentin-positive, and multifocally S100-, GFAP- and NGFR-positive but smooth muscle actin-, desmin-, Melan-A- and PNL2-negative. A suspicion of FROMS was issued in both cases. The masses enlarged until they filled the orbit, involving the entire face (in case 1 within one year, in case 2 within two months), leading to the spontaneous death of case 1 due to anorexia.

Conclusions

The results suggest that FROMS can manifest with oral swelling as first clinical presentation: despite the term "orbital myofibroblastic sarcoma", FROMS should be considered as differential diagnosis for oral masses in cats, and caution should always be exercised even with well-differentiated mesenchymal proliferations.

Poster Abstracts Veterinary Pathology

TUMOUR PATHOLOGY

77 | UTERINE TORSION IN A RABBIT WITH UTERINE ADENOCARCINOMA

F. Seixas^{*,†}, R. Sargo^{‡,*}, C. Cardoso[§], F. Loureiro^{¶,*}, L. Sousa[¶], F. Silva^{*,‡}, L. Lourenço^{*} and M. Pires^{*,‡}

[†]CECAV - Animal and Veterinary Research Centre, [‡]AL4AnimalS-Associate Laboratory for Animal and Veterinary Sciences, [‡]Veterinary Hospital, University of Trás-os-Montes and Alto Douro (UTAD) Vila Real, [§]Veterinary Hospital, University of Trás-os-Montes and Alto Douro and [¶]Veterinary Hospital, ^{*}AL4AnimalS - Associate Laboratory for Animal and Veterinary Sciences and ^{*}Veterinary Sciences Department, University of Trás-os-Montes and Alto Douro (UTAD), Vila Real, PT

Introduction

Uterine torsion is rarely reported in rabbits, mainly described in cases of pregnancy, hydrometra, or metritis; it may be promoted by the existence of uterine masses, fetal retention, congenital deformities and abdominal trauma, among other factors. Herein, we report a case of uterine horn torsion associated with uterine adenocarcinoma.

Materials and Methods

A 7-year-old female rabbit pet was consulted due to apathy. The clinical exam revealed poor body condition, dehydration, and hypotension. An X-ray showed a mass in the uterine region and multiple pulmonary metastatic nodules. A presumptive diagnosis of metastatic uterine adenocarcinoma was proposed. After stabilization, the rabbit went home on palliative care, where it remained stable until it was found dead two weeks later.

Results

The necropsy revealed poor body condition, ascites, and an extensive mass in the right uterine horn that showed torsion. Pulmonary metastasis, pleural carcinomatosis, and metastasis in the liver, lymph nodes and kidney were observed. Macroscopically we observed a pale, intraluminal mass, measuring 6x1.5x1.5 cm, occupying the uterine lumen. Microscopically, neoplasia uterine adenocarcinoma sheets or tubular arrangement of neoplastic cells, hyalin change of the stroma, and necrosis was observed. The metastases and the primary tumour had similar microscopic features.

Conclusions

Uterine adenocarcinoma is a common tumor in pet rabbits over 4 years old. In the present case, it had led to uterine torsion, a rare condition that results in infarction of the affected structure and, if not reversed, usually has a fatal outcome.

Acknowledgements: This work was supported by the projects UIDP/CVT/00772/2020 and LA/P/0059/2020 funded by the Portuguese Foundation for Science and Technology (FCT).

Poster Abstracts Veterinary Pathology

TUMOUR PATHOLOGY

84 | HISTOLOGICAL CLASSIFICATION AND MOLECULAR CHARACTERIZATION OF FELINE HODGKIN-LIKE LYMPHOMAS (HLL)

S. Dell'Aere*, G. Foiani[†], M. Vascellari[†], F. Tiracorrendo*, G. Ghisleni[‡], A. Rigillo[§], E. Melchiotti[†], A. Carminato[†], C. Zamboni* and P. Roccabianca*

**Department of Veterinary Medicine and Animal Sciences, University of Milan, Lodi, IT, [†]Laboratory of Histopathology, Istituto Zooprofilattico Sperimentale delle Venezie, Legnaro, IT, [‡]BiEsseAscil Diagnostic Laboratory, Milano, IT and [§]San Marco Diagnostic Laboratory, Veggiano, IT*

Introduction

Hodgkin lymphomas comprise a group of miscellaneous lymphoid tumours containing large neoplastic lymphoid cells admixed with reactive cells. Hodgkin-like lymphoma (HLL) has been described in cats and rarely in other species. This study describes morphological, phenotypical, and molecular features of feline HLL, enabling the differentiation from mixed non-HLL.

Materials and Methods

Twenty-one feline nodal lymphomas with mixed morphology and a presumptive diagnosis of HLL were collected (2006-2023). Samples were subjected to routine histology, immunohistochemistry (anti-CD3, -CD20, -CD30, -PAX-5), and clonality assessments.

Results

HLL was confirmed in 12/21 cases while 9/21 were non-HLL. Cats with HLL were domestic short haired (9/12) and Maine Coon (3/12), the F/M ratio was 1 and the mean age was 7.6 years. HLL histological subtypes included lymphocyte-rich (6/12), mixed cellularity (2/12), and nodular sclerosis (2/12). In 2/12 cats the HLL subtype could not be assigned. Distinctive morphological findings included: colliquative necrosis, reactive background lymphocytes, and variable proportions of large neoplastic cells. Reed-Sternberg/Hodgkin cells were always found while Pop-Corn cells were rare. Reed-Sternberg/Hodgkin cells consistently expressed CD30, and variably expressed CD20 and PAX-5. Most non-HLL were CD30 negative. Clonal IGH rearrangement was detected in 8/12 HLL and 8/9 non-HLL. Lineage infidelity with TCRG rearrangement was observed in 3 HLL.

Conclusions

Differentiation between HLL and non-HLL with mixed morphology may be challenging. Necrosis, Reed-Sternberg/Hodgkin cells, CD30 expression were the most useful features for HLL diagnosis. Clonality assessment confirmed a B cell origin of feline HLL but is not useful to differentiate HLL from non-HLL with mixed morphology.

Poster Abstracts Veterinary Pathology

TUMOUR PATHOLOGY

85 | LIMITATIONS OF THE CURRENT EQUINE MELANOCYTIC TUMOUR CLASSIFICATION

A. Malá*, **M. Škorič***, **A. Kopecká†**, **L. Frgelecová*** and **A. Angelova***

**Department of Pathological Morphology and Parasitology and †Equine Clinic, University of Veterinary Sciences Brno, Brno, CZ*

Introduction

Equine melanocytic tumours (EMT) are frequent in older grey horses. They are described as variously pigmented neoplasias, mainly located on the ventral tail and in the perineum, which can progress into generalised disease. Histopathologically, EMT can be divided into four types: melanocytic naevus (MN), dermal melanoma/melanomatosis (DM/DMT) and anaplastic malignant melanoma (AMM). However, recent studies suggest that this classification does not sufficiently reflect the biological behaviour of these tumours. This study aimed to classify EMTs diagnosed by routine HE staining with the aid of immunohistochemistry (IHC).

Materials and Methods

The submitted samples were fixed in 10% neutral buffered formalin, paraffin embedded, cut and stained with HE and by immunohistochemistry for PNL 2, S100 protein, vimentin, Ki-67 and RACK1.

Results

EMTs from thirty horses were examined. The majority of the affected horses were grey, only three had other coat colours (black, perlino, chestnut). Twelve EMTs were classified as DM/DMT, eleven as MN and two as AMM. Five cases could not be classified. They originated from three horses with a single or multiple tumours which showed characteristics of both MN and DM/DMT and two horses with early stage of the disease.

Conclusions

The relatively high proportion of unclassified EMTs (3 out of 30 cases, 10%) indicate the need for improving/extending of the current classification.

Acknowledgements: This research was financed by the grant IGA VETUNI 110/2022/FVL.

Poster Abstracts Veterinary Pathology

TUMOUR PATHOLOGY

88 | EXPRESSION OF SOX-10 AND TYRP-1 IN FELINE MELANOMA

M. Orlandi, C. Brachelente, M. Sforza, L. Mechelli, A. Lo Giudice and I. Porcellato

Department of Veterinary Medicine, University of Perugia, Perugia, IT

Introduction

In cats, melanomas represent a diagnostic challenge for pathologists, especially when amelanotic. To date, immunohistochemical diagnostic panel is based on specific melanocytic markers (Melan-A and PNL-2), and a non-specific but sensitive marker (S100). In human medicine, SOX-10 has been reported as a sensitive marker for the detection of lymph node micrometastases of melanoma. TYRP-1, an enzyme involved in melanogenesis, has recently been used as a specific melanocyte marker in humans and dogs. The aim of this study was to evaluate the cross-reactivity and expression of SOX-10 and TYRP-1 antibodies in feline normal tissues and melanocytic tumours.

Materials and Methods

Thirty-one cases of ocular and non-ocular melanomas confirmed by histopathology and by immunolabelling for Melan-A and/or PNL-2 were selected and tested with antibodies against SOX-10 and TYRP-1.

Results

Cross-reactivity of the antibodies was confirmed. Nuclear SOX-10 expression in normal tissues was seen in epidermal, subepidermal, hair bulb, iris stromal melanocytes and in dermal nerve structures. In melanomas, nuclear expression of SOX-10 was detected in ocular (11/12), oral (6/7) and cutaneous (12/12) sites. TYRP-1 cytoplasmic immunolabelling in normal tissues was observed in epidermal and bulbar melanocytes and in the pigmented epithelium of the iris and its stroma. Its expression was positively correlated with the degree of tumour pigmentation and was observed in ocular (9/12), oral (3/7) and cutaneous (4/12) melanomas.

Conclusions

This study demonstrated cross-reactivity of SOX-10 and TYRP-1 antibodies in non-neoplastic and neoplastic feline melanocytes. Potential prognostic use of these marker has to be tested in a larger cohort study.

Poster Abstracts Veterinary Pathology

TUMOUR PATHOLOGY

91 | MIRNA PROFILES IN DOGS WITH SPLENIC ANGIOSARCOMA

C. Zamboni*, **G. Avallone†**, **P. Roccabianca***, **L.G. De Matos***, **Y. Dadi***, **P. Valenti‡**, **F. Ceciliani*** and **C. Lecchi***

**Department of Veterinary Medicine and Animal Sciences (DIVAS), University of Milan, Lodi, IT, †Department of Veterinary Medical Sciences (DIMEVET), University of Bologna, Bologna, IT and ‡Clinica Veterinaria Malpensa, Anicura, Samarate, IT*

Introduction

MiRNAs are small single-stranded non-coding RNAs involved in cellular processes epigenetically modulating mRNA transcription in diverse disorders. MiRNAs can be significantly dysregulated in cancer and function as tumour promoters or suppressors. This study assessed miRNA profiles in formalin-fixed, paraffin-embedded canine splenic angiosarcomas (CSAS) by next-generation sequencing.

Materials and Methods

Twenty-four samples were included, specifically 12 CSAS (6 stage II and 6 stage III) and 12 corresponding autologous normal splenic tissue (ANST) samples.

Results

The expression of 20 miRNAs was significantly differentially expressed (DE) in CSAS compared with ANST: 15 were up- and 5 were downregulated; dividing CSAS by clinical stage, the expression of DE-miRNAs was as follows: 53 DE-miRNAs (27 up- and 26 downregulated) in CSAS vs ANST stage II, 84 DE-miRNAs (34 up- and 50 downregulated) in CSAS vs ANST stage III, 11 DE-miRNAs (8 up- and 3 downregulated) in stage II vs stage III CSAS, 6 upregulated miRNAs in stage II vs stage III ANST.

Conclusions

The results suggest the involvement of detectable miRNAs in the epigenetic regulation of CSAS. Furthermore, differences between miRNA profiles in stage II and stage III CSAS and in ANST of dogs with stage II and stage III tumours were found. These findings suggest a possible higher tendency/predisposition of canine splenic tissue to angiosarcoma development. Future analyses including additional cases of CSAS and normal splenic tissues from dogs without CSAS are warranted to confirm these results.

Poster Abstracts Veterinary Pathology

TUMOUR PATHOLOGY

99 | A CASE OF FELINE GASTROINTESTINAL EOSINOPHILIC SCLEROSING FIBROPLASIA EXTENDING TO THE LIVER

M. Orlandi*, **F. Abramo†**, **V. Habermass†**, **E. Gori†** and **V. Marchetti†**

**Private Veterinary Laboratory "MyLav", Passirana di Rho - Milan, IT and †Department of Veterinary Sciences, University of Pisa, Pisa, IT*

Introduction

Feline gastrointestinal eosinophilic sclerosing fibroplasia (FGESF) has been described as an inflammatory disease characterised by eosinophilic infiltration and fibroplasia affecting the gastrointestinal tract. A recent report of this entity outside the gastrointestinal tract, in the nasal mucosa and its draining lymph nodes, introduced the more general term FESF. Here we describe histopathological changes compatible with FESF in the liver of a cat with a previous diagnosis of the enteric form.

Materials and Methods

An 8-year-old male DSH cat was presented with diarrhoea and hyporexia. A diagnosis of FGESF had been made two months previously and the cat treated with prednisolone and cyclosporine without response. Clinical examination revealed a decreased body condition, the haematobiochemical profile was unremarkable, except for high serum amyloid-alpha. Ultrasonography showed an enlarged liver with abnormal echostructure and multiple masses; the jejunal lymph nodes were enlarged and hypoechoic. Laparoscopic biopsies of the liver lesions and lymph nodes were taken for histopathology.

Results

On histopathology examination, the liver parenchyma was almost entirely occupied by nodular lesions consisting of infiltrating bundles/whorls of fibrotic tissue intermingled with fibroblasts, hypersegmented neutrophils, eosinophils, macrophages, lymphocytes and a few mast cells. Multifocal aggregates of lymphoid cells were present. The jejunal lymph nodes showed the same lesions as the liver. Picrosirius red staining confirmed the presence of diffuse sclerosing fibroplasia in both affected sites. Despite therapy, the cat died one month after diagnosis.

Conclusions

To the authors' knowledge, this is the first report of FGESF progressing to the liver, with fatal outcome.

Poster Abstracts Veterinary Pathology

TUMOUR PATHOLOGY

113 | TUMOUR IMMUNE MICROENVIRONMENT (TIME) IN BPV1-POSITIVE EQUINE SARCOIDS

L. De Paolis*, **I. Porcellato†**, **S. Mecocci†**, **C. Pigoli‡**, **L. Mechelli†**, **V. Montemurro***, **K. Cappelli†**, **C. Eleni§**, **L.R. Gibelli‡**, **C.G. De Ciucis¶***, **F. Fruscione***, **M. Pezzolato***, **C. Brachelente†**, **C. Cocumelli§**, **B. Passeri‡**, **R. Gialletti†**, **A. Ghelardi*** and **E. Razzuoli***

**National Reference Center of Veterinary and Comparative Oncology (CEROVEC), Istituto Zooprofilattico Sperimentale del Piemonte, Liguria e Valle d'Aosta (IZSPLV), Genoa, IT,*

†Department of Veterinary Medicine, University of Perugia, Perugia, IT, ‡Laboratorio d'Istologia patologica, Istituto Zooprofilattico Sperimentale della Lombardia ed Emilia-Romagna (IZSLER),

Milan, IT, §Anatomia patologica e Istopatologia, Istituto Zooprofilattico Sperimentale del Lazio e Toscana (IZSLT), Rome, IT, ¶Department of Public Health, Experimental and Forensic

*Medicine, University of Pavia, Pavia, IT, †Department of Veterinary Science, University of Parma, Parma, IT and *UOC Ostetricia e Ginecologia, Azienda USI Toscana Nord-Ovest, Massa, IT*

Introduction

Equine sarcoid is the most commonly diagnosed cutaneous neoplasm in horses, representing up to 90% of all skin tumours. Clinically, it can occur as a single or multiple fibroblastic, wart-like and locally aggressive lesions. Although the aetiology is multifactorial, Bovine Papillomaviruses (BPVs) types 1, and less commonly 2, are most likely involved in sarcoid pathogenesis. Despite many efforts to develop an effective therapy, there is still no treatment recognized as universally successful. The purpose of the study was to gain insight into the tumour immune microenvironment (TIME) of equine sarcoids, aiming at identifying possible prognostic factors or targets for future therapeutic approaches.

Materials and Methods

Thirty-five equine sarcoid samples were retrospectively selected and histopathologically re-evaluated. BPV1-DNA was detected by qPCR, and ISH was performed in order to evaluate E6/E7 oncogene expression at mRNA level. Expression of CD3, CD20, Iba1, CD204, CD163, and MUM1 was quantitatively assessed through IHC.

Results

All tested samples were positive for BPV1-DNA, while 24/35 (68.57%) expressed E6/E7 oncogenes. IHC showed that most tumours were immune-deserted or excluded, based on the presence of Tumor Infiltrating Lymphocytes (TILs). Intratumorally, the immune infiltrate was mostly composed of CD163+, CD204+ and Iba1+ macrophages. Conversely, the number of tumour infiltrating MUM1+ plasma cells and CD20+ and CD3+ lymphocytes was lower compared to CD163+, CD204+ and Iba1+ macrophages.

Conclusions

Our results suggest that sarcoids may be mostly "cold" tumours, characterized by a prominent macrophage infiltrate, without conspicuous lymphocytes and plasma cells infiltrating the neoplastic tissue.

Poster Abstracts Veterinary Pathology

TUMOUR PATHOLOGY

114 | EVALUATION OF CANINE AND FELINE TUMOURS IN MOROCCO: RESULTS OF A COUNTRY-WIDE EPIDEMIOLOGIC AND HISTOLOGIC STUDY

N. Laissaoui^{*,†}, D. Simon Betz[‡], Y. Millán[§], M. El Mrini[¶], N. Lamalmi[‡], N. Tligui[†] and R. Azrib^{*}

**Department of Medicine, Surgery and Reproduction and †Department of Veterinary Pathology and Public Health, Agronomy and Veterinary Institute Hassan II, Rabat, MA, ‡Independent Scientific Writing, Translation & Consultancy Clinical Oncology, Armsheim, DE, §Department of Comparative Pathology, Faculty of Veterinary Medicine, University of Córdoba, Córdoba, ES and ¶Department of Animal Health, National Office of Sanitary Safety of Food Products, Rabat, MA and ‡Departement of Pathology, Faculty of Medicine and Pharmacy, Mohammed V University, Rabat, MA*

Introduction

Cancer epidemiology is a valuable means of surveillance and understanding. Systematic veterinary data remain scarce for many countries. This work aimed to evaluate the occurrence, epidemiology and histopathologic characteristics of canine and feline neoplasias in Morocco.

Materials and Methods

In a prospective study (September 2020 to March 2023), 250 tumour samples were collected from veterinary clinics across five regions in Morocco and subjected to histopathological diagnosis. For each case, breed, age, sex, neuter status, geographic region, and tumour site were analyzed.

Results

Among the 250 tumours, 201 (80.4%) were from dogs and 49 (19.6%) from cats. The most common tumour location in dogs was the reproductive tract (n=74, 36.8%), followed by skin (n=55, 27.4%), and mammary gland (n=30, 14.9%). In cats, skin tumours were the most frequent neoplasms (n=27, 55.1%), followed by tumours of the mammary gland (n=10, 20.4%) and digestive tract (n=7, 14.3%). Most common canine histologic tumour types were transmissible venereal tumour (n=64, 31.8%) and mammary carcinoma (n=29, 14.4%). Squamous cell carcinoma (n=17, 34.7%) and fibrosarcoma (n=7, 14.3%) represented the most frequent feline neoplasms. Median age of dogs and cats at diagnosis was 7 and 10 years, respectively. Sex distribution was even in dogs (f:m=1:1.1), whereas in cats females were overrepresented (f:m=1.6:1). Most cats and about half of the dogs were mixed-breed.

Conclusions

Tumours in dogs and cats from Morocco show epidemiologic and histologic differences to populations from other countries, in part grounded in the high incidence of canine TVT and - possibly solar-induced - feline skin tumours.

Acknowledgements: Funding: National Center for Scientific and Technical Research (CNRST) (Grant no. 4IAV.2021, 2021)

Poster Abstracts Veterinary Pathology

TUMOUR PATHOLOGY

118 | TWO DIAGNOSTICALLY CHALLENGING HEMANGIOSARCOMAS IN DOGS GROWING INSIDE BLOOD VESSELS

S. Soto*, **S. Blatter***, **I. Cvitas***, **L. Peters†**, **J. Pfister‡** and **H. Pereira§**

**Institute of Animal Pathology and †Clinical Diagnostic Laboratory, Department of Clinical Veterinary Medicine, Vetsuisse Faculty, University of Bern, Bern, CH, ‡Veterinary Clinic Lausanne-Ecublens Anicura, Lausanne, CH and §Centre for Interdisciplinary Research in Animal Health (CIISA), Faculty of Veterinary Medicine, University of Lisbon, Lisbon, PT*

Introduction

Haemangiosarcomas are frequent malignant tumours in dogs usually affecting the parenchyma of solid organs. Rare cases growing inside blood vessels have been described. Here we report two diagnostically challenging canine haemangiosarcomas growing inside blood vessels.

Materials and Methods

Dog 1: 10 years, male entire Staffordshire bull terrier with a tumour in the left carotid artery. Cytological (Wright's Giemsa) and histological examination (HE stain) including immunohistochemistry (CD31, SMA, c-Kit) were performed. Dog 2: 8 years, male entire Labrador Retriever with crusting ulcerative skin lesions on the flank. Histological examination (HE stain) including immunohistochemistry (vimentin, pancytokeratin, CD18, CD3, CD20, CD79a, Pax-5, granzyme-B, synaptophysin, Melan-A, PNL-2 and CD31) were performed.

Results

Dog 1: Cytology showed abundant well-granulated mast cells and high numbers of slender spindle cells, interpreted as a mast cell tumour with reactive fibroplasia. Histology revealed a transmural, infiltrative, CD31-positive spindle cell tumour forming blood filled spaces with numerous well-granulated mast cells displaying a homogeneous cytoplasmic c-Kit stain, interpreted as an intravascular haemangiosarcoma with reactive mast cells. Seven months after excision the dog was clinically stable. Dog 2: Histologically, necrotic areas were present, reaching deep into the skin, caused by neoplastic cells occluding vessels. Neoplastic cells were negative for all markers except vimentin and CD31. The lesions were interpreted as metastases of an intravascular haemangiosarcoma. No primary tumour was detected clinically. The dog was euthanized.

Conclusions

These two diagnostically challenging cases show that haemangiosarcomas may grow exclusively within the wall of blood vessels, potentially causing skin necrosis instead of a mass lesion.

Poster Abstracts Veterinary Pathology

TUMOUR PATHOLOGY

126 | DISSEMINATED CUTANEOUS NON-EPITHELITROPIC B CELL LYMPHOMA ASSOCIATED WITH A FRACTURE SITE IN A CAT

M. Saravia-Castro*, **A. Reyes-Matute†**, **A. Cervantes-Arias‡** and **D.d.J. Ruiz-Castillo§**

**Diagnóstico Veterinario Alhambra, †Departamento de Patología and ‡Departamento de Medicina, Cirugía y Zootecnia para Pequeñas Especies, Facultad de Medicina Veterinaria y Zootecnia, Universidad Nacional Autónoma de México and §Hospital Veterinario de Alta Especialidad Delta, Mexico City, MX*

Introduction

Lymphomas associated with fracture sites are unusual in all species. Here we report the clinical-pathological aspects of a fracture site-associated lymphoma.

Materials and Methods

A 9-year-old neutered male cat presented with swelling of the left tarsus and a history of a fracture with a surgical metal implant 6 years prior. Samples were taken for cytology, histopathology and immunophenotyping. The response to treatment and the post-mortem findings of the subject were documented.

Results

Histology revealed a cutaneous lymphoma, with CD79a positive and weakly PAX5 positive neoplastic lymphocytes, as well as dispersed CD3 positive mature lymphocytes, leading to the diagnosis of a B cell lymphoma. The affected limb was amputated and 4 months later the patient presented swelling at the site of the amputation scar. Another biopsy was taken, leading to the same diagnosis. Chemotherapy was initiated with lomustine and prednisolone, however, due to severe myelosuppression and poor response to treatment, the protocol was changed to modified COP (vincristine, chlorambucil and prednisolone); the patient had progressive disease, rapidly declining, until euthanasia was elected. A necropsy was performed, and samples were taken from all organs which confirmed spread to lymph nodes, bone marrow, spleen, liver, and urinary bladder. Immunohistochemistry showed strong positivity for CD79a and weak positivity for PAX5 in all neoplastic processes.

Conclusions

This is one of the few complete reports of cutaneous non-epitheliotropic lymphoma associated with a fracture site in a cat. It is hypothesised that trauma, metal implants, and chronic inflammation play a role in oncogenic transformation.

Poster Abstracts Veterinary Pathology

TUMOUR PATHOLOGY

130 | INFLAMMATORY INFILTRATE IN THE FELINE MAMMARY GLAND: HEALTHY, NON-NEOPLASTIC, BENIGN AND MALIGNANT LESIONS

J. Rodrigues-Jesus^{*}, A.C. Figueira^{†,‡}, C. Marrinhas[§], G.N. Petrucci^{¶,‡}, H. Gregório[‡], F. Tinoco^{*}, A. Goulart^Δ, H. Felga, H. Vilhena, A. Canadas-Sousa^{*} and P. Dias-Pereira^{*}

^{}Department of Pathology and Molecular Immunology, School of Medicine and Biomedical Sciences, ICBAS-UP, University of Porto, [†]OneVet Veterinary University Hospital of Coimbra (HVUC), [‡]Department of Veterinary Medicine, Centre for Investigation Vasco da Gama (CIVG), Vasco da Gama University School and [§]OneVet Veterinary Hospital of Baixo Vouga (HVBV), Águeda, PT, [¶]OneVet Veterinary Hospital of Porto (HVP), [‡]AniCura Veterinary Hospital Centre (CHV) and ^ΔDra. Flora Tinoco Veterinary Clinic, Maia, PT, ^ΔOeste Veterinary Centre, Leiria, PT, Cat Clinic - Veterinary Clinic, Porto, PT, Department of Veterinary Medicine, Centre for Investigation Vasco da Gama (CIVG), Vasco da Gama University School / OneVet Veterinary University Hospital of Coimbra (HVUC), Coimbra, PT and Animal and Veterinary Research Centre (CECAV), University of Trás-os-Montes e Alto Douro / Associate Laboratory of Animal and Veterinary Sciences AL4AnimalS, PT*

Introduction

Inflammation is a frequent finding in feline mammary neoplasms. Recent research suggests that presence and location of tumour-associated inflammation might play a significant role in the clinical outcome of feline mammary carcinomas. The present study aimed at an overall assessment of inflammatory infiltrates in healthy, hyperplastic/dysplastic, benign and malignant lesions of the feline mammary gland.

Materials and Methods

Perilesional and intralesional inflammatory foci were evaluated in each lesion and categorized according to distribution (focal, multifocal or diffuse) and intensity (discrete, moderate or marked). A control group included queens without mammary changes.

Results

The study enrolled 178 queens, encompassing 75 (25.2%) hyperplasias/dysplasias and 223 (74.8%) tumours (8.1% benign; 91.9% malignant). Perilesional inflammation was observed in 268 (81.2%; 72% of non-neoplastic; 72.2% of benign; 98% of malignant). Hyperplasias/dysplasias and benign tumours displayed mostly focal to multifocal discrete perilesional inflammatory foci, whereas malignant tumours exhibited multifocal discrete to moderate foci. Most non-neoplastic and malignant lesions (76.7% and 87.8%, respectively) presented intralesional inflammatory infiltrates, while a considerably lower proportion of benign tumours (33.35%) did. Inflammatory foci were predominantly focal in hyperplasias/dysplasias and benign tumours, and multifocal in malignant neoplasms. Intralesional immune cells were mostly discrete, irrespective of biological behaviour. The control group comprised 167 individual mammary glands, 28.1% of which presented scant individually disperse periductal/peritubular immune cells.

Conclusions

Differences observed in the abundance and distribution pattern of inflammatory infiltrate in different types of feline mammary lesions suggest that this component may be an active player in neoplastic transformation and progression in this species.

Acknowledgements: This work was supported by Fundação para a Ciência e Tecnologia (FCT) through PhD fellowship ref. 2022.09644.BD, and projects UIDP/00772/2020 and LA/P/0059/2020.

Poster Abstracts Veterinary Pathology

TUMOUR PATHOLOGY

134 | RETROSPECTIVE STUDY OF SPINDLE CELL TUMOURS IN THE FACE OF CATS

S. Soto*, **S. Blatter***, **C. Krudewig†**, **M. Steck‡**, **S. Hobi§**, **N. Kühn¶**, **M. Ruetten***, **N. Ignatenko*** and **S. Rüfenacht^Δ**

**Institute of Animal Pathology, Vetsuisse Faculty, University of Bern, Bern, CH, †Institute of Veterinary Pathology and ‡Virology Institute, Vetsuisse Faculty, University of Zürich, Zürich, CH, §Department of Veterinary Clinical Sciences, Jockey Club College of Veterinary Medicine and Life Sciences, City University of Hong Kong, Hong Kong, HK, ¶Kühn Pathologie, Hünenberg / Zug, CH, *PathoVet, Tagelswangen, CH, *Tierarztpraxis Feldkirchen, DE and ^ΔDermaVet, Oberentfelden, CH*

Introduction

Spindle cell tumours in cats, including suspected feline sarcomas, are rarely examined using immunohistochemistry or tested for bovine papillomavirus. The present study applied these approaches in 30 feline spindle cell tumours of the face.

Materials and Methods

FFPE specimens of 30 feline spindle cell tumours affecting the face, 3 presenting as a crusty erosive/ulcerative lesion and the others as a mass, were examined using immunohistochemistry for vimentin, SOX-10, S-100, GFAP, NSE, periaxin, SMA, p63 and Melan-A, and PCR for bovine papillomavirus 14 (BPV14).

Results

Twelve tumours were diagnosed as feline sarcomas and 18 as spindle cell tumours based on their morphology. All were positive for vimentin and negative for Melan-A. From the suspected sarcomas, 5 were confirmed by PCR (BPV14 positive). Six of the 7 BPV14-negative tumours were positive for SOX-10 and S-100, some also for GFAP and NSE, compatible with peripheral nerve sheath tumour (PNST). The remaining one was negative for all markers except vimentin. All 18 spindle cell tumours were PCR negative for BPV14; 15 were positive for SOX-10 and 14 also for S-100, GFAP and/or NSE, compatible with PNST. Among the SOX-10 negative tumours was one positive for NSE (compatible with PNST) one positive for SMA (compatible with leiomyosarcoma) and one positive for S-100 and SMA, with doubtful diagnosis.

Conclusions

The results suggest that feline sarcomas are overdiagnosed based on morphology. Most of the wrongly diagnosed feline sarcomas appear to be PNSTs which we found to be frequent spindle cell tumours in the face in cats and although usually present as a mass, can also present as a crusty erosive/ulcerative lesion.

Poster Abstracts Veterinary Pathology

TUMOUR PATHOLOGY

139 | NORTHERN PORTUGUESE DOG LYMPHOMA IMMUNOPHENOTYPIC STUDY

N.R. Lima^{*.†}, M.J. Macedo^{*.†}, G. Silva[‡], E. Freire^{*.†}, M. Costa^{*.†}, M. dos Anjos Pires^{*.†}, A. Alves^{*.†}, A. Gama^{*.†}, L. Cardoso^{*.†} and F. Seixas^{*.†}

[†]Department of Veterinary Sciences, School of Agrarian and Veterinary Sciences (ECAV) and [‡]Animal and Veterinary Research Centre (CECAV), and Associate Laboratory for Animal and Veterinary Science (AL4Animals), University of Trás-os-Montes e Alto Douro (UTAD), Vila Real, PT and ^{}Institute of Biomedical Sciences Abel Salazar (ICBAS), University of Porto (UP), Porto, PT*

Introduction

Canine lymphoma (CL) is a common type of neoplasia that results from the uncontrolled proliferation of cells of the lymphoid system. CL is classified into B and T subtypes based on the histomorphology characteristics of dominant cell populations and their immunophenotyping. The aim of this study was to identify, by immunophenotypic analysis, the subtypes of lymphoid cells involved in the pathophysiology of CL that influence the treatment, prognosis, and natural history of this disease.

Materials and Methods

Eighty cases registered at the Histology and Pathology Laboratory of UTAD and morphologically diagnosed as CL were immunophenotyped using the immunohistochemical technique with anti-PAX-5 (anti-B-lymphocytes) and anti-CD3 (anti-T-lymphocytes) antibodies.

Results

CL was more common in males (61%), with a median age of 7 years, and the Doberman was the most affected breed, followed by the Labrador. Of the cases analysed, 38 were diagnosed as B cell lymphoma (47.5%) and 42 as T cell lymphoma (52.5%).

Conclusions

The results of this study differ from those reported in the literature, which indicate that dogs are more likely to contract B cell lymphomas. Although the aetiology of CL is unknown, these differences may be attributable to environmental and genetic factors. However, the results need to be confirmed by more extended epidemiological studies, including the use of molecular diagnostic methods.

Acknowledgements: To CECAV-UTAD, project UIDP/CVT/00772/2020, and to AL4Animals, project LA/P/0059/2020, both supported by FCT (Foundation for Science and Technology), Portugal. This work was funded by project "oneHcancer-One health approach in animal cancer", operation no.: NORTE-01-0145-FEDER-000078, co-funded by the European Regional Development Fund (ERDF) through NORTE 2020 (North Portugal Regional Operational Program 2014/2020).

Poster Abstracts Veterinary Pathology

TUMOUR PATHOLOGY

159 | CARTILAGE OLIGOMERIC MATRIX PROTEIN (COMP) EXPRESSION IN CANINE OSTEOSARCOMAS AND SPLENIC HAEMANGIOSARCOMAS

B. Passeri*, **E. Boiardi†**, **F. Armando‡**, **E. Negrotti***, **C. Bilotto†**, **M. Martano***, **C. Guarnieri***, **F.M. Martini*** and **R. Perris†**

**Veterinary Science and †Department of Chemical and Life Sciences and Environmental Sustainability, University of Parma, Parma, IT and ‡Pathology, University of Veterinary Medicine Hannover, Foundation, Hannover, DE*

Introduction

COMP is a pentameric, proteolysis sensitive macromolecule that serves as a primary constituent of the extracellular matrix (ECM) of cartilage and tendons. Unexpectedly, it has recently been discovered to be de novo expressed in a variety of human tumours of epithelial and mesenchymal origin making it a potential new target for monoclonal antibody therapy. In order to assess the potential translational application of this, this study investigated the COMP expression in 2 canine tumours with poor prognosis and limited successful treatment options, canine osteosarcoma (C-OSA) and canine splenic haemangiosarcoma (C-HS).

Materials and Methods

3 C-OSA and 3 C-HS were investigated by immunohistochemistry using a panel of anti-human COMP monoclonal antibodies (mAb). Osteosarcoma (D17) and fibroblast (A72) cell lines were also investigated in vitro by immunofluorescence and immunoblotting using the same antibodies.

Results

COMP mAbs yielded a cytoplasmic to membranous immunolabelling in a variable number of neoplastic cells in all tumours, in all conditions. Semiquantitative assessment showed higher numbers of COMP-expressing neoplastic cells in C-OSA samples. In both D17 and A72 cells COMP protein was also identified with COMP mAbs.

Conclusions

Canine osteosarcoma showed a marked reactivity with anti-human COMP mAbs. Future studies with an increased number of C-OSA investigating more in depth the diagnostic and prognostic role of COMP are warranted to elucidate the future potential of this novel treatment option.

Poster Abstracts Veterinary Pathology

TUMOUR PATHOLOGY

169 | TRANSCRIPTOME EVALUATION OF EQUINE SARCOID INFECTED BY BOVINE PAPILLOMAVIRUS TYPE-1

S. Mecocci*, **S. Capomaccio***, **I. Porcellato***, **L. De Paolis†**, **L. Mechelli***, **F. Fruscione†**, **R. Ratto***, **B. Passeri‡**, **R. Gialletti***, **M. Pepe***, **A. Ghelardi§**, **K. Cappelli*** and **E. Razuoli†**

**Department of Veterinary Medicine, University of Perugia, Perugia, IT, †National Reference Center of Veterinary and Comparative Oncology (CEROVEC), Istituto Zooprofilattico Sperimentale del Piemonte, Liguria e Valle d'Aosta (IZSPLV), Genoa, IT, ‡Department of Veterinary Science, University of Parma, Parma, IT and §UOC Ostetricia e Ginecologia, Azienda UsI Toscana Nord-Ovest, Massa, IT*

Introduction

Sarcoids are the most common skin tumours in horses and represent up to 90% (35-90%) of skin neoplasms in this species. They affect horses of all ages and both sexes and can occur as single or multiple lesions in different forms, ranging from small, wart-like lesions to large, ulcerated, fibrous growths. The entity is of high relevance for the veterinary field due to the high incidence, resistance to therapy and frequent recurrence. The aim of this work was to better understand the host-pathogen interaction by gaining knowledge on transcriptomic tumor microenvironment.

Materials and Methods

Twelve sarcoids, tested positive to BPV1 infection, and 12 healthy skin samples from subjects tested negative for the viral DNA, were submitted to high-throughput NGS for mRNAs and small RNAs. Differentially expressed genes (DEGs) and miRNAs in sarcoids vs controls were identified; then, miRNA targets were retrieved. Further analyses for Gene Ontology (GO) category enrichment were carried out.

Results

2415 up-regulated and 3620 down-regulated genes along with 66 up-regulated and 40 down-regulated miRNAs were found. The functional analyses for DEGs and miRNA showed several enriched GO categories for biological processes: for DEGs, cytokine and chemokine production, growth factors and collagen binding, cell adhesion and development, tissue morphogenesis and inflammatory and immune response; for miRNA, transcriptional modulations, cytoskeleton organization processes, DNA and RNA packaging and transport, and host-viral interaction.

Conclusions

Our data identified a great discrepancy of transcription between sarcoid lesions and healthy skin with an overall enrichment for processes related to infection and cellular transformation.

Poster Abstracts Veterinary Pathology

TUMOUR PATHOLOGY

172 | CHARACTERIZATION OF B7-H3 IMMUNOHISTOCHEMICAL STAINING IN CANINE PRIMARY APPENDICULAR OSTEOSARCOMA

D. Seelig^{*,†}, A. Armstrong^{†,†}, K. Demos-Davies[‡], A. Wolf-Ringwall^{*}, C. Johnson^{*}, S. Terezakis^{†,§}, C. Carlson^{*,†} and J. Lawrence^{†,†}

^{}Department of Veterinary Clinical Sciences, University of Minnesota, Saint Paul, US, [†]Masonic Cancer Center and [‡]Department of Veterinary Clinical Sciences, University of Minnesota, St. Paul, US and [§]Department of Radiation Oncology, University of Minnesota, Minneapolis, US*

Introduction

B7-H3 is a checkpoint ligand that attenuates anti-cancer immune responses by inhibiting T cell activation, proliferation and cytokine production. Overexpression of B7-H3 on tumors and tumor-associated macrophages has been linked to grade, invasion and prognosis in several human solid cancers. B7-H3 overexpression has been demonstrated in canine osteosarcoma cells, but little is known regarding its distribution within primary tumours. The objective of this study was to characterize B7-H3 expression by immunohistochemistry (IHC) in canine appendicular osteosarcoma.

Materials and Methods

Dogs with radiographic evidence of a primary appendicular bone tumour underwent limb amputation. Affected bones were collected and fixed in 10% neutral buffered formalin, decalcified with 10% EDTA, and processed for histopathologic evaluation and B7-H3 IHC. Select tumour sections were immunostained using a commercial B7-H3 antibody, the immunoreactivity was semi-quantitatively scored within the tumour cell, inflammatory cell, reactive bone, and reactive fibroplasia populations.

Results

Nine dogs with osteosarcoma were evaluated. There was widespread, but variable B7-H3 staining of tumour cells, with more intense staining in grade 3 tumours than grade 1 tumours. The surrounding reactive bone and fibroblastic tissue demonstrated sporadic and less intense B7-H3 staining. Intra- and peri-tumoural macrophages showed consistent weak B7-H3 expression, and tumour-associated endothelial cells demonstrated a variable reaction.

Conclusions

B7-H3 is broadly expressed in canine appendicular osteosarcoma, including in tumour cells, infiltrating macrophages, and tumour-associated endothelial cells, with decreased expression in reactive tissue. Because B7-H3 contributes to the immunosuppressive tumour microenvironment, understanding its distribution may impact therapeutic efforts to target this checkpoint protein.

Poster Abstracts Veterinary Pathology

TUMOUR PATHOLOGY

173 | SECONDARY MULTICENTRIC LARGE B CELL LYMPHOMA DEVELOPMENT AFTER INTESTINAL LARGE T CELL LYMPHOMA IN A DOG

C.C. Kuo*, **A.T.C. Liao***, **J.J. Lee†**, **H.Y. Wang‡**, **W.H. Huang‡** and **C.R. Jeng‡**

**Department and Institute of Veterinary Medicine, †Institute of Veterinary Clinical Science and ‡Institute of Molecular and Comparative Pathobiology, National Taiwan University, Taipei City, TW*

Introduction

In veterinary medicine, secondary malignant neoplasms are rarely reported in veterinary medicine. Here we present the case of a fourteen-year-old female spayed mixed-breed dog with primary intestinal T cell lymphoma that later developed secondary multicentric large B cell lymphoma.

Materials and Methods

The patient had undergone surgical resection of a small intestinal mass, which was diagnosed as intestinal large T cell lymphoma. After sixteen months of chemotherapy, the patient was diagnosed with multicentric B cell lymphoma. After one year of chemotherapy for multicentric lymphoma, necropsy was performed as the patient died of disease progression. Immunohistochemistry (IHC) for CD3, CD20, and PAX-5 was performed for lymphoid lineage determination, PCR for Antigen Receptor Rearrangements (PARR) to determine lymphoid clonality at different time points.

Results

Post mortem findings confirmed the diffuse large B cell lymphoma with multiple organ involvement, by histology, IHC and PARR examination. No evidence of intestinal T cell lymphoma was found. The survival time for intestinal T cell lymphoma and multicentric diffuse large B cell lymphoma were 931 and 319 days, respectively.

Conclusions

This case report suggests that secondary malignancy can develop after long-term chemotherapy. Biopsy and necropsy accompanied by IHC and PARR PCR are valuable for identify the primary and secondary lymphoid malignancies. Besides being the first report of secondary malignancy of multicentric B cell lymphoma after intestinal T cell lymphoma in a dog, it is also a rare report of long-term survival of an intestinal large T cell lymphoma.

Poster Abstracts Veterinary Pathology

TUMOUR PATHOLOGY

175 | TRIGEMINAL NERVE DESTRUCTION DUE TO ATYPICAL MALIGNANT CHEMODECTOMA METASTASIS IN A DOG

I. Stylianaki^{*}, A.L. Thomas[†], E. Chaitidis^{*}, L. Kakosimos[†], R.D. Baka[‡], M.N. Patsikas[§], Z.S. Polizopoulou[‡] and T. Poutahidis^{*}

^{}Pathology, [†]Companion Animal Clinic, [‡]Diagnostic Laboratory and [§]Laboratory of Diagnostic Imaging, School of Veterinary Medicine, Aristotle University of Thessaloniki, GR*

Introduction

Tumours of chemoreceptor organs (chemodectomas) are rare neoplasms primarily arising from the aortic and carotid bodies. Malignant chemodectomas often metastasize into the lungs, bronchial and mediastinal lymph nodes, liver, pancreas, and kidney. Here we report an unusual case of canine malignant chemodectoma with a trigeminal nerve-associated clinical manifestation.

Materials and Methods

A 13-year-old female, intact Doberman admitted to the Companion Animal Clinic, AUTH, with keratoconjunctivitis sicca, Horner syndrome, and trigeminal nerve neuropathy (right temporal and masticatory muscle atrophy and facial paralysis) was euthanized and submitted for necropsy, with the suspicion of trigeminal nerve tumour. Tissue samples collected at necropsy were stained with HE or synaptophysin-, NSE (Neuron Specific Enolase)-, and S-100-specific immunohistochemistry.

Results

Grossly, two unilateral firm, encapsulated, smooth-surfaced, coarsely multilobulated, ovoid masses with largest diameters of 5.8 and 1.5 cm were found in the inferior dorsolateral cervical area. Suspected bone metastatic lesions were seen in the cranial cavity surface of the temporal bones. Both primary neoplastic and metastatic lesions showed histopathological and immunohistochemical features typical for chemodectoma. Synaptophysin-, NSE- and S-100- positive round to polygonal neoplastic cells were separated by variable amounts fibrovascular stroma into lobules, nests or packages. Capsule and vascular invasion was evident in the large cervical mass.

Conclusions

Chemodectoma arising from the innominate artery below the right subclavian artery, metastasized probably via the internal carotid artery into the petrous bone resulting in trigeminal nerve destruction, veli palatini muscle dysfunction, and Horner syndrome in this dog.

Poster Abstracts Veterinary Pathology

TUMOUR PATHOLOGY

176 | ADRENAL CAVERNOUS HAEMANGIOMA IN A SHIH-TZU DOG: AN INCIDENTAL FINDING

H. Fattahian^{*}, Z. Mostahsan[†], N. Mansouri[†], Y. Dibavand[‡], S.S. Sharifzad[§] and M. Khoei[¶]

^{}Department of Clinical Sciences, Faculty of specialized Veterinary Science, Science and Research branch, Islamic Azad University and [†]Department of Surgery, [‡]Department of Pathology, [§]Department of Internal Medicine and [¶]Department of Diagnostic Imaging, Hamidreza Fattahian Small Animal Hospital, Tehran, IR*

Introduction

Cavernous haemangioma are benign endothelial tumours that rarely affect the adrenal gland without vascular structure infiltration. Most of these unilateral tumours remain silent and are incidentally found on abdominal imaging.

Materials and Methods

A 10-year-old castrated male shih-tzu dog was presented to the hospital for periodic check-up. A left retroperitoneal mass was observed through radiography. Abdominal ultrasonography confirmed enlargement of the right adrenal gland with heterogeneous echo texture. A blood sample was obtained from the patient for haematological, biochemical and hormonal analysis. Left adrenalectomy was performed via midline exploratory laparotomy, and the mass was submitted for histopathological examination.

Results

Laboratory findings showed normal hepatic, renal, lipid and haematological profiles but an elevated serum cortisol level. Microscopic examination of the surgical specimen revealed a mass composed of dilated vascular channels lined by the single layer of endothelium filled with red blood cells. The presence of intermingled adrenocortical elements was seen at the periphery. Immunohistochemistry demonstrated that tumour cells were diffusely positive for CD34 and Factor VIII related antigen. A diagnosis of cavernous hemangioma with no malignancy was made.

Conclusions

We presented this clinical case report because of its rarity, and also to highlight the histopathological and immunohistochemical diagnostic features. The patient is alive without any complications two months post-operatively.

Poster Abstracts Veterinary Pathology

TUMOUR PATHOLOGY

181 | CLINICOPATHOLOGICAL FEATURES OF CANINE "PAEDIATRIC" GLIOMAS

A. Oevermann^{*}, N. Shihab[†] and A. Maiolini[‡]

^{}Division of Neurological Sciences, DCR-VPH and [†]Southern Counties Veterinary Specialists, Hampshire, GB and [‡]Department of Clinical Veterinary Science, University of Bern, Bern, CH*

Introduction

Malignant CNS tumours are the second most common tumours in children, and gliomas account for approximately one third. Although gliomas are the most common CNS tumours in dogs, gliomas in puppies have been very rarely reported. Therefore, this study describes the clinicopathological features of childhood canine gliomas based on a case series of six dogs < 1 year of age.

Materials and Methods

Clinical and pathological data of dogs < 1 year with glioma diagnosis were collected from the neuropathological archive of the Division of Neurological Sciences.

Results

The age of the 6 dogs (Boxer, Doberman, Newfoundland, Cavalier King Charles Spaniel, Jack Russel Terrier, Chihuahua) at first presentation ranged from 5 to 9 months. The most commonly reported clinical signs were ataxia, cranial nerve deficits, obtundation, recumbency, and reduced/delayed proprioception. All gliomas were high grade (5 anaplastic oligodendrogliomas, 1 anaplastic astrocytoma). Three oligodendrogliomas appeared to originate near the midline (septum/septal nuclei) and extended extensively into the lateral ventricles. One oligodendroglioma occurred in the brainstem and another in the temporal lobe. The astrocytoma extended from the midbrain to the thalamus.

Conclusions

The high proportion of anaplastic oligodendrogliomas in puppies reflects the high prevalence of oligodendrogliomas in adult dogs. Known predisposed breeds were not overrepresented in this puppy population. Puppy gliomas occurred in caudal brain areas (midbrain, brainstem) and near the midline (septal nuclei) rather than in adult glioma predilection sites (frontal, parietal, temporal lobes). These observations suggest differences in oncogenesis between "paediatric" and adult gliomas in dogs.

Poster Abstracts Veterinary Pathology

TUMOUR PATHOLOGY

185 | UNUSUAL METASTASIS SITE FOR DERMAL MELANOMATOSIS IN A LIPIZZANER MARE

A.A. Dobrin*, **G.L. Nicolae***, **R.E. Tiu***, **R. Nuțiu***, **A.S. Pașca†**, **O.M. Hrițcu†** and **M. Militaru***

**Pathology, University of Agronomic Sciences and Veterinary Medicine of Bucharest, Bucharest, RO and †Pathology, University of Life Sciences, Iași, RO*

Introduction

Equine melanocytic tumours are reported to have 15-20% prevalence, approximately 66% being likely to acquire malignant behaviour. Lipizzaner horses develop melanomas with a 50% incidence. Dermal melanomatosis is a malignant form occurring in white/grey horses older than 10-15 years.

Materials and Methods

A 20-year-old Lipizzaner mare with body condition score of 2 (out of 9) and difficulties in defecation was euthanised. It had previously been diagnosed with dermal melanomatosis. A perineal melanoma detected and surgically resected 5 months ago had recurred rapidly. The mare was submitted to post-mortem examination. Cytological and histopathological investigations were performed.

Results

The mare showed a 22 x 32 x 10 cm plaque-like grey circular mass involving perianal, perineal, vulvar regions with confluent nodular masses and ulcerations. Metastases were noted at the ventral part of the tail, in the mammary gland region, left atrium, anorectal and tracheobronchial lymph nodes. Histologically, the primary tumour was a deep dermal pseudo-encapsulated, slightly pigmented mass with pleomorphic melanocytes and melanophages; marginal embolism was noted. The mammary gland showed focal lesions with highly-pigmented epithelioid cells in papillary dermis, fibrous stroma and mammary lobules; junctional dermal-epidermal activity was present. The nodular cardiac mass was pseudo-encapsulated in the myocardium with melanophages containing abundant amounts of melanin pigment.

Conclusions

In this case, typical internal metastases (lungs, liver, spleen) were not encountered, apart from the nodule in left atrium that was confirmed as distant melanoma. This has previously been described as a less common metastatic site (29%) in equine dermal melanomatosis.

Poster Abstracts Veterinary Pathology

TUMOUR PATHOLOGY

188 | A CASE OF EQUINE MULTICENTRIC LYMPHOMA: CLINICAL, MICROSCOPICAL AND MOLECULAR FINDINGS

G.F. Silva*, **M.C.P. Rocha[†]**, **T.E. Ribeiro***, **R. Cunha^{*‡}**, **P.B. Salas***, **T.P. Guimarães^{*‡}**, **M. Ribeiro***, **F. Carvalho***, **J. Mesquita*** and **I. Amorim***

**ICBAS School of Medicine and Biomedical Sciences, Porto University, Porto, PT, †Departament of Sugery and Clinical Veterinary, FCAV-UNESP, Paulista State University, Julio de Mesquita Filho, Jaboticabal, BR and ‡AL4animals, Associate Laboratory for Animal and Veterinary Sciences, Lisbon, PT*

Introduction

Lymphoma represents a heterogeneous group of haematopoietic tumours originating in lymphoid tissue. Although uncommon, multicentric lymphoma remains the most prevalent form in horses. Recently, EHV-5 infection has been associated with lymphoproliferative diseases in young horses. This study investigated the clinical, pathological and molecular features of a case of equine multicentric lymphoma.

Materials and Methods

In 2022, a 5-year-old crossbreed mare was admitted to the ICBAS-Equine Clinical Center with fever, supraorbital oedema and mandibular lymph node enlargement. Twenty days later, there was a severe worsening of the clinical condition and the mare died. Haematological and biochemical tests, necropsy and tissue histological evaluation, along with immunohistochemistry employing antibodies for CD3, Pax5, CD79alpha, CD20, PDL-1, C-KIT and Ki-67, and EHV-5 PCR analysis, were performed.

Results

At necropsy, the main findings were multiple and well circumscribed white to brownish nodular lesions, distributed along the serous surface of oropharynx, trachea, pericardium, gastrointestinal tract and mesentery. Microscopically, these consisted of solid proliferations of neoplastic round cells, displaying significant anisokaryosis, anisocytosis and high mitotic activity. The great majority of neoplastic population exhibited immunopositivity for CD3 (T cells) however, there was also a significant number of CD79alpha-positive cells (B cells). Additionally, the Ki-67 proliferative index reach 19%. PCR evaluation is still ongoing.

Conclusions

Based on these findings, a multicentric T lymphoma was diagnosed. There is still very little research regarding the molecular characterization of lymphoma in horses. As an entity itself quite heterogeneous, it is important to describe the interspecies particularities to understand its development and behaviour.

Poster Abstracts Veterinary Pathology

TUMOUR PATHOLOGY

190 | METHYLATION ANALYSIS OF LINE-1 ELEMENTS IN CANINE MAST CELL TUMOURS

G. Bogdanov Giorgini, R.A. da Silva, J.G. Xavier and E.F. Bondan

Graduate Program in Environmental and Experimental Pathology, University Paulista, São Paulo, BR

Introduction

Epigenetics is the study of changes in gene function that are meiotically or mitotically heritable but without implying DNA change. LINE-1 (long interspersed nuclear element-1) is a family of related class I transposable elements in the DNA that is dispersed throughout the entire genome. The study of its methylation pattern is used in the understanding of several neoplasms. Canine mast cell tumours represent a frequent cutaneous neoplasm presenting different degrees of malignancy, being classified according to their histological differentiation. In view of the current scientific scarcity in relation to the epigenetic pattern of neoplasms in domestic animals, this study aimed to verify whether there is correlation between the methylation pattern of LINE-1 with the different staging of canine mastocytomas according to the Kiupel classification.

Materials and Methods

DNA and RNA were extracted from paraffinized healthy and neoplastic (classified as low grade and high grade) tissue samples using the phenol/chloroform/isoamyl alcohol and TRIzol® methods, respectively. LINE-1 methylation pattern and gene expression were quantified by qPCR.

Results

A higher LINE-1 gene expression was observed in neoplasms with a higher degree of malignancy in relation to healthy samples and neoplasms with a lower degree of malignancy. Hypomethylation of the LINE-1 promoter region was also noted in both neoplastic mast cell tumour classifications in relation to the healthy tissue.

Conclusions

Tumours classified as more malignant present higher gene expression of LINE-1 and lower degree of methylation of the promoter region, evidencing the potential use of LINE-1 as a biomarker of genomic instability.

Poster Abstracts Veterinary Pathology

TUMOUR PATHOLOGY

191 | RELATIONSHIP BETWEEN HISTOLOGICAL PARAMETERS, PROLIFERATIVE INDEX AND THE EXPRESSION OF VIMENTIN AND FASCIN-1 IN PAPILOMAS AND ORAL SQUAMOUS CELL CARCINOMAS IN DOGS

T.M. Queté dos Reis and J.G. Xavier

Patologia Ambiental e Experimental, Universidade Paulista-UNIP, São Paulo, BR

Introduction

Epithelial cells can acquire a mesenchymal phenotype as a consequence of the down-regulation of epithelial cell hallmarks during the epithelial-to-mesenchymal transition (EMT), generally with expression of vimentin, fibronectin and N-cadherin. Cells undergoing EMT lose epithelial characteristics and acquire mesenchymal features, such as motility. Fascin is a cytoskeleton-binding protein associated with cell motility in both normal and neoplastic conditions. The expression of fascin is low or absent in adult epithelial cells but its overexpression in tumours is associated with poor prognosis. An in vitro study has shown that fascin regulates EMT and invasion in oral squamous cell carcinoma (OSCC) cells. In this retrospective study, the EMT and fascin expression were investigated in samples of canine papillomas and OSCCs.

Materials and Methods

Fifteen canine biopsy samples, diagnosed as papilloma (n=5) and OSCC (n=10) were morphologically analysed, and the OSCC graded. Immunohistochemistry was performed, using the MACH1 Universal HRP-Polymer detection system on 4 µm-thick sections of formalin-fixed paraffin-embedded blocks. Monoclonal antibodies to Ki-67 (MIB-1), vimentin (V9) and fascin-1 (FSCN/417) were used.

Results

The proliferative index was higher in malignant lesions (>30%). Vimentin expression occurred in carcinomas, and in these stained only invasive neoplastic cells in aggregates or isolated. Fascin-1 expression was identified in both benign and malignant lesions but with greater labelling intensity in the latter. There was an association between high histological grade, elevated proliferative index, and expression of vimentin and fascin-1 in carcinoma cells.

Conclusions

These findings suggest that vimentin and fascin-1 are promising prognostic markers for canine OSCCs.

Poster Abstracts Veterinary Pathology

TUMOUR PATHOLOGY

194 | CLINICAL, ULTRASONOGRAPHIC AND IMMUNOHISTOCHEMICAL STUDY OF DIFFUSE LARGE B CELL LYMPHOMAS IN DOGS

M.C.P. Rocha*, **I.C.K. Cruz†**, **B.B. Lima***, **G.J.U. Carra***, **R.A.R. Uscategui‡**, **M.A.R. Feliciano§**, **J.M. Pazzini¶** and **A.B. DeNardi***

**FCAV-UNESP-Paulista State University Julio de Mesquita Filho and †Federal University of Espírito Santo (UFES), Center for Agricultural Sciences and Engineering (CCAIE), BR, ‡INCA-CES research group, Facultad de Medicina Veterinaria y Zootecnia, Universidad CES, Medellín, CO, §Department of veterinary medicine, Faculty of Animal Science and Food Engineering - University of São Paulo, Pirassununga, BR and ¶Department of General Surgery and Oncology, Clinic my pet -UniSALESIANO, Araçatuba, BR*

Introduction

Diffuse large B cell lymphoma (DLBCL) is the most common type of non-Hodgkin lymphoma in people and dogs, with differing survival times and variable aggressiveness. This study aimed to establish criteria for better prognostic characterization and therapeutic monitoring of the disease in dogs.

Materials and Methods

The ultrasonographic features of peripheral lymph nodes were evaluated in 16 dogs with DLBCL (GL), diagnosed through histopathology and immunohistochemistry (IHC), and in 12 healthy dogs (GC). B mode ultrasonography and quantitative and qualitative elastography were performed serially during CHOP (cyclophosphamide, doxorubicin, vincristine, prednisone) chemotherapy treatment, at T0, T5, T10, T15 and T19 weeks. The expression of the biomarker of activated fibroblasts, alpha-SMA, was evaluated by IHC along with the expression of type I and III collagen in Picrosirius red stained sections, in the stroma of lymph node biopsies. These evaluations aimed to establish a possible correlation with therapeutic response and survival time.

Results

There was a statistically significant difference ($P < 0.05$) between the qualitative and quantitative ARFI elastography and the minor axis/major axis ratio measured using the B mode in the lymph nodes, among the different lengths of therapy and the therapeutic response identified by cytology. More rigid structures, evaluated by qualitative elastography, were correlated significantly with shorter patient survival ($P = 0.026$). No statistical differences were found between groups regarding alpha-SMA and collagen expressions.

Conclusions

It is suggested that elastography is an auxiliary, non-invasive diagnostic tool in veterinary oncology to monitor the therapeutic response during chemotherapy in canine DLBCL.

Acknowledgements: to FCAV/ UNESP- Jaboticabal and by the science and research funding institution, CAPES.

Poster Abstracts Veterinary Pathology

TUMOUR PATHOLOGY

198 | RHABDOMYOMATOUS MESENCHYMAL HAMARTOMA IN A DOG

R. Marica, C. Toma, D. Hodor and A. Negoescu

Department of Veterinary Pathology, Faculty of Veterinary Medicine, University of Agricultural Sciences and Veterinary Medicine, Cluj-Napoca, RO

Introduction

Rhabdomyomatous mesenchymal hamartoma (RMH), also known as striated muscle hamartoma, is an uncommon tumour-like process in animals, with only a few cases described in the literature. Here we present a case of RMH in a dog, along with the histopathological and immunohistochemical features.

Materials and Methods

A 7-year old male mixed-breed dog presented with a papillary-like cutaneous mass on the skin of the head. The tumour measured approximately 0.5 x 1 cm and excisional biopsy was performed for microscopical diagnosis. The sample was stained with hematoxylin-eosin and Masson's trichrome stains, followed by immunohistochemical evaluation, using anti-S100 and anti-desmin antibodies.

Results

The histopathological examination revealed a non-encapsulated, poorly circumscribed dermal mass covered by intact epidermis. The mass consisted of haphazardly arranged dense collagen fibres admixed with interfollicular proliferation of well-differentiated striated muscle fibres. The muscle fibres were arranged individually or in bundles, extending towards the epidermal basement membrane. Multifocally, islands of mature adipocytes, nests of epithelial cells with sebaceous differentiation, and bundles of peripheral nerve tissue were identified. All components were well differentiated, and no malignancy features or nuclear atypia were observed. Multifocally, the overlying surface epithelium showed hyperkeratosis and moderate acanthosis. Immunohistochemically, the mass showed intense desmin and S100 expression. Collectively, these data supported a diagnosis of rhabdomyomatous mesenchymal hamartoma.

Conclusions

This report offers an evaluation of a rare tumour-like lesion, which, although uncommon in animals, must be included in the differential diagnosis when assessing cutaneous masses. RMH has a good prognosis following surgical removal.

Poster Abstracts Veterinary Pathology

TUMOUR PATHOLOGY

200 | INCIDENCE OF THE MOST FREQUENT CANINE TUMOURS BASED ON THE SWISS CANINE REGISTRY DATA FROM 2008 TO 2020

E.S. Dhein*, **U. Heikkilä†**, **A. Oevermann‡**, **D. Meier§**, **S. Hartnack¶** and **F. Gusceiti‡**

**Institute of Veterinary Pathology, Vetsuisse Faculty, University of Zurich, Zurich, CH, †Identitas AG, CH-3014 Bern, CH, ‡Division of Neurological Sciences, Department of Clinical Research and Veterinary Public Health, Vetsuisse Faculty, University of Bern, CH-3001 Bern, CH, §Zyto/Histo Diagnostik Labor Freienstein, CH-8427 Freienstein, CH and ¶Section of Epidemiology and ‡Institute of Veterinary Pathology, Vetsuisse Faculty, University of Zurich, CH-8057 Zurich, CH*

Introduction

Cancer is the leading cause of death in dogs. Monitoring cancers in standardized registries facilitates epidemiological studies to investigate risk factors for tumour development. The aim of the study was to determine the incidence rates (IR) of tumours in the Swiss dog population and to unveil unknown breed-related tumour susceptibilities.

Materials and Methods

Between January 2008 and December 2020, 54,986 tumours were registered in the Swiss Canine Cancer Registry. Diagnoses were coded according to the Vet-ICD-O-canine-1 and tumour IRs were calculated using demographic data from the Swiss national dog registration database Amicus.

Results

The overall tumour IR was 775 (95%CI 764-777) tumours/100,000 dog-years at risk. The highest tumour IR was found in 11-year-old dogs (IR: 1,857, 95%CI 1,780-1,867). Female dogs (IR: 850, 95%CI 834-853) exhibited an elevated IR compared to male dogs (IR: 679, 95%CI 666-684). Frequently diagnosed tumours were lipomas (IR: 100, 95%CI 108-112; 14.27% of all tumours), mast cell tumours (IR: 77, 95%CI 75-79; 9.98%) and cutaneous histiocytomas (IR: 46, 95%CI 44-47; 5.91%). Most of the tumours occurred in the skin (n=19,234; 34.98%), followed by soft tissues (n=10,871; 19.77%) and the mammary gland (n=7,970 tumours; 14.49%). Breeds with the highest IRs comprised Polski Owczarek Nizinny (IR: 3,303, 95%CI 2,502-3,864), Magyar Vizsla (IR: 3,154, 95%CI 2,824-3,352) and Flat Coated Retrievers (IR: 3,024, 95%CI 2,778-3,114).

Conclusions

Known breed predispositions were confirmed and previously unknown ones were identified. The results are of potential utility in various areas of veterinary medicine, including oncology research and breeding management.

Acknowledgements: The Swiss National Research Foundation is acknowledged for funding (Projekt Biolink 31BL30_189698)

Poster Abstracts Veterinary Pathology

TUMOUR PATHOLOGY

205 | INTER-INSTITUTIONAL STUDY REGARDING THE EPIDEMIOLOGY OF GASTROINTESTINAL TUMOURS IN DOGS AND CATS

A. Negoescu*, **C. Toma***, **C. Gal†**, **I. Amorim‡**, **K. Aharoni§** and **M. Taulescu***

**Veterinary Pathology, Faculty of Veterinary Medicine, University of Agricultural Sciences and Veterinary Medicine, Cluj-Napoca, RO, †Synevovet Laboratory, Chiajna, RO, ‡Institute of Molecular Pathology and Immunology of the University of Porto (IPATIMUP), Porto, PT and §Koret School of Veterinary Medicine, IL*

Introduction

Gastrointestinal (GI) tumours in dogs and cats are relatively uncommon and are mainly represented by lymphoma, adenocarcinoma, gastrointestinal stromal tumour, leiomyoma, and leiomyosarcoma. The epidemiological data regarding these tumours in domestic species is insufficient. This study aimed to provide an overview of the epidemiological and pathological features of GI tumors in dogs and cats.

Materials and Methods

Databases from the past 10 years (2013-2023) from different laboratories (Romania, Israel, and Portugal) were assessed. A total of 210 GI tumour cases in dogs and cats were selected and statistically evaluated.

Results

The average age at diagnosis of GI tumours was 9.85 years for dogs and 10.08 years for cats. In dogs, a higher prevalence was recorded in males for both gastric (61.11%) and intestinal (69.35%) locations. In cats, females showed a higher predisposition (stomach: 51.42% and intestine: 61.84%). In dogs, gastric malignant tumours (MT) accounted for 23 cases, with lymphomas being the most common neoplasm (39.13%), while leiomyoma (61.53%) was the most common benign gastric neoplasia. Canine intestinal MT comprised 51 cases, of which lymphomas accounted for 45.09%, followed by mesenchymal (33.33%), and epithelial (23.52%) tumours. In cats, lymphoma was the most common tumour for both gastric (80%) and intestinal (84.21%) locations. Similar results were obtained from all laboratories.

Conclusions

For both dogs and cats lymphoma was the most common GI tumour regardless of location. These findings provide insights into the epidemiology of GI tumours in dogs and cats, which can aid in the early diagnosis and management of these conditions.

Poster Abstracts Veterinary Pathology

TUMOUR PATHOLOGY

216 | CYTOLOGICAL AND PATHOLOGICAL FINDINGS IN A FELINE CHOROID PLEXUS CARCINOMA

A. Perez-Ecija^{*}, S. Guil[†], J. Morgaz[‡], B. Blanco[‡] and Y. Millan[†]

^{}ANIMAL MEDICINE AND SURGERY, UNIVERSITY OF CORDOBA, CORDOBA, ES and [†]Anatomia y anatomia patologica comparadas and [‡]ANIMAL MEDICINE AND SURGERY, UNIVERSITY OF CORDOBA, ES*

Introduction

Choroid plexus carcinomas are relatively common in dogs, mostly found in the fourth ventricle, often leading to secondary obstructive hydrocephalus due to their intraventricular location. These tumours are rare in cats. A 2 year old male Angora cat was referred to the Veterinary Teaching Hospital due to sudden blindness. Ophthalmological examination did not find significant changes in the fundus which suggested central blindness. No other neurological abnormality or cranial nerve change was noted.

Materials and Methods

A cranial CT scan revealed a large mass occupying the right auditory bulla and horizontal ear canal, causing adjacent osteolysis and bone remodeling, affecting the optic nerve and compressing the right lateral ventricle. Ventral bulla osteotomy revealed that the cavity was almost completely filled with friable, caseous to gelatinous material. Samples for microbial culture, cytology (impression smears), and histology including immunohistochemistry were obtained.

Results

Cytology found moderate to high cellularity. Cells formed tight groups, were round to columnar, showing marked anisocytosis with moderate anisokaryosis and naked nuclei in the background. Histology revealed a multilobulated neoplasia with palisading cells arranged in nests and trabecula separated by scant fibrovascular stroma. Atypia was moderate, mitoses were rare. Neoplastic cells were positive for Glial fibrillary acidic protein (GFAP), S-100 and cytokeratins (AE1/AE3), while negative for neurofilaments, synaptophysin and calponin.

Conclusions

Although there is a marked variation between reports, both the cytological and histological findings and the immunohistochemistry results in this case are consistent with a choroid plexus carcinoma, providing further data on this sporadic tumour in cats.

Poster Abstracts Veterinary Pathology

TUMOUR PATHOLOGY

217 | RARE AND UNCOMMON MALIGNANT MAMMARY TUMOURS IN DOGS AND CATS: PRELIMINARY RESULTS FROM A PORTUGUESE MULTICENTRIC STUDY

A. Gama^{*†}, F. Seixas^{*†}, P. Maria dos Anjos^{*†}, A. Alves^{*†}, C. Marrinhas^{‡§}, H. Vilhena^{§†}, A. Santos^{¶‡}, F. Ferreira^{*Δ}, J. Santos, P. Dias Pereira[‡], P. Faísca and J. Correia^{*Δ}

[†]Department of Veterinary Sciences, School of Agrarian and Veterinary Sciences (ECAV), University of Trás-os-Montes e Alto Douro (UTAD) and [‡]Animal and Veterinary Research Centre (CECAV), UTAD and Associate Laboratory for Animal and Veterinary Science (AL4Animals), Vila Real, PT, [‡]Onevetgroup - Hospital Veterinário do Baixo Vouga, Aveiro, PT, [§]Centro de Investigação Vasco da Gama (CIVG), Escola Universitária Vasco da Gama (EUVG), Onevetgroup Hospital Veterinário Universitário de Coimbra (HVUC), Coimbra, PT, [¶]Centro de Estudos em Ciência Animal (CECA), and Associate Laboratory for Animal and Veterinary Science (AL4Animals) and ^ΔInstituto de Ciências Biomédicas de Abel Salazar da Universidade do Porto (ICBAS-UP), Porto, PT, ^{}Center of Interdisciplinary Research in Animal Health (CIISA), University of Lisbon and Associate Laboratory for Animal and Veterinary Science (AL4Animals), ^ΔFaculdade de Medicina Veterinária da Universidade de Lisboa, FMV-ULisboa, DNAtech Veterinary Laboratory and Faculty of Veterinary Medicine and CBIOS-University Lusófona's Research Center for Biosciences & Health Technologies, University Lusófona, Lisboa, PT*

Introduction

Canine and feline mammary tumours (MT) are frequently diagnosed neoplasms. Histological proposed classifications recognize distinct entities, with several histotypes considered as uncommon or rare, such as MT of special type. The main objective of this study was to gather a large series of rare or uncommon canine and feline malignant MT (RUMT) from four different Portuguese institutions to better characterize these MT.

Materials and Methods

Canine and feline MT submitted for histopathology from 2018 to 2022 were retrospectively selected from the laboratory databases; when diagnoses were compatible with a RUMT (special histotypes, micropapillary carcinoma, anaplastic carcinoma, carcinosarcoma), cases were reviewed and histologically graded, using a grading system for canine/feline mammary carcinomas.

Results

From a total of 6420 MT (4642 canine and 1778 feline, excluding hyperplasias/dysplasias), 259 RUMT (256 animals) were found, with a higher prevalence in dogs; 205 (4.42%) represented canine and 54 (3.04%) feline RUMT. In dogs, RUMT included adenocarcinoma (n=34; 0.73%), mucinous (n=15; 0.32%), lipid-rich (n=2; 0.04%), spindle cell (n=1; 0.02%), inflammatory mammary carcinomas (n=24; 0.52%), malignant myoepithelioma (n=27; 0.58%), micropapillary (n=5; 0.11%), anaplastic (n=32; 0.69%) and carcinosarcoma (n=65; 1.4%); in cats, RUMT included adenocarcinoma (n=12; 0.68%), mucinous (n=11; 0.62%), inflammatory mammary (n=6; 0.38%), micropapillary (n=6; 0.33%), anaplastic carcinomas (n=9; 0.51%) and carcinosarcoma (n=10; 0.56%). Adenocarcinoma was the most common special histotype in both species. Most carcinomas were grade III (63.9%).

Conclusions

This joint effort of Portuguese academic and private institutions allows a large-scale comprehensive investigation of epidemiological, morphological and immunohistochemical RUMT specific data.

Acknowledgements: This work was financed by national funds through FCT-Portuguese Foundation for Science and Technology, within the scope of the projects UIDB/CVT/00772/2020 (CECAV), UIDB/00276/2020 (CIISA), LA/P/0059/2020 and AL4A-PROJ-LT3.2 (AL4Animals).

Poster Abstracts Veterinary Pathology

TUMOUR PATHOLOGY

223 | A RARE CASE OF GIANT CELL RICH EXTRASKELETAL OSTEOSARCOMA OF CARDIAC MUSCLE IN A DOG

C. de Meeûs¹, M. Gérardy¹, D. Cassart¹, M. Romnee¹, M.-M. Garigliany¹

¹Department of Morphology and Pathology, Faculty of Veterinary Medicine, ULiège, Belgium

Introduction

Osteosarcoma (OSA) is the most common primary bone tumour of the appendicular skeleton in dogs and can be defined as a malignant mesenchymal tumour producing osteoid matrix. Occasionally, OSA can arise in soft tissues without presence of a primary bone tumour, which is defined as extra skeletal OSA and has been found in skin, muscle, mammary gland, spleen, liver and eye, but has never been described in cardiac muscle. A rare histological variant of OSA is the giant cell rich osteosarcoma that has, to our knowledge, never been described in dogs.

Materials and Methods

An 11-year-old neutered male Dogue de Bordeaux was presented for anorexia, lethargy, cough and presence of multiple nodules. The dog was euthanized and a necropsy was performed.

Results

A high volume of serohaemorrhagic fluid was found in both the abdominal and thoracic cavities. Several mineralized nodules of 1 mm to 3 cm were found in the myocardium of the right atrium and ventricle. Furthermore, small mineralized masses on the intestines, mesenterium and internal abdominal wall were found, as well as more than 100 small mineralized cannonball metastases on the lungs. Histologically, all masses were similar, and were composed of chords of pleiomorphic polygonal to spindle shaped cells with oval nucleus, surrounded by an osteoid matrix, interspersed by giant cells that contained up to 10 nuclei. There was marked anisokaryosis and anisocytosis and a high mitotic count.

Conclusion

This is a rare case of extraskeletal giant cell rich OSA in atypical locations, such as the myocardium.

Poster Abstracts Clinical Pathology

4 | INCIDENCE OF GENETIC VARIANTS IN SELECTED CANINE CARDIOMYOPATHIES IN SEVERAL BREED

K. Törner¹, C. Beitzinger¹, A.L. Van de Weyer¹, K. Kempker² and H. Aupperle-Lellbach¹

¹LABOKLIN GmbH & Co. KG, Bad Kissingen, Germany and ²Tierärztliche Gemeinschaftspraxis Dres. Fischer & Dr. Kempker, Niederwern, Germany

Background

Canine primary cardiomyopathies include hypertrophic, dilated (DCM), arrhythmogenic right ventricular, and juvenile cardiomyopathies.

Objective

The aim of this study was to describe the genotype variants in selected cardiomyopathies in certain breed.

Methods

Routine blood samples and swabs from 1,961 dogs were genotyped as N/N (free), N/mut (carrier), or mut/mut (affected), and allele frequency (AF) was calculated. Samples from 94 Doberman pinschers were tested for DCM1 and DCM2. DCM variant RBM20 was evaluated in 13 miniature (MS), 343 standard (SS), and 457 giant schnauzers (GS). Gil1 was tested in 553 Rhodesian Ridgebacks for inherited ventricular arrhythmia (IVA). Belgian shepherd variants (n=501) were analysed for variants in YARS2 (cardiomyopathy with juvenile mortality, CJM). Depending on type and position of the genetic variant, direct sequencing, real-time PCR or fragment length analysis was performed.

Results

Doberman pinschers were DCM1 N/N (73.4%), N/DCM1 (24.4%), or DCM1/DCM1 (2.2%); DCM2 N/N (78.4%) or N/DCM2 (21.6%). AF was 14.4% (DCM1) and 10.8% (DCM2). For IVA, Rhodesian Ridgebacks were N/N (58%), N/IVA (36.5%) or IVA/IVA (5.4%); AF was 23.7%. MS were RBM20 free. SS were 89.5% N/N and 10.5% N/DCM; AF was 5.2%. GS were 91.0% N/N and 9% N/DCM; AF was 0.65%. AF of YARS2 in Belgian shepherd was 11.2% (Malinois, n=410), 7.25% (Tervueren, n=62), 1.8% (Groenendael, n=27).

Conclusion

Genetic testing allows diminishing breeding risks. Future studies would profit from additional data about genetic relationships or clinical presentation. Moreover, cardiomyopathies are multifactorial processes and genetic variants represent only one factor for the development of cardiac diseases.

Poster Abstracts Clinical Pathology

9 | A CASE OF PERICARDIAL EFFUSION ASSOCIATED WITH CANINE LEISHMANIOSIS IN A SAINT BERNARD DOG

C Rodríguez-Cariño¹, P García-Ortells², A Alonso-Herrero³, D Marí-Martorell⁴ and L Hernández-Martínez⁵

¹Clinical Pathology Department, IDEXX Laboratories Iberia, Barcelona-Spain; ²Hospital Veterinario Albéitar, Logroño-Spain; ³Clínica Veterinaria La Dehesa, Soria-Spain, ⁴Professional Services Veterinarian IDEXX Laboratories Iberia, Barcelona-Spain; ⁵Medical Consultant Service, IDEXX Laboratories Iberia, Madrid-Spain

Background

Canine leishmaniosis (CanL) is a zoonotic disease caused by *Leishmania infantum*. The domestic dog is the most important reservoir and can present a broad range of clinical manifestations. Pericardial effusion (PE) is an uncommon presentation in dogs.

Objective

Describe an unusual presentation of leishmaniosis with PE in a dog and the treatment follow-up.

Methods

An eight-year-old male Saint Bernard presented with lethargy, anorexia, and tachypnoea. Cardiomegaly, cardiac tamponade, pericardial and abdominal effusion were found by thoracic radiography and abdominal ultrasound. Pericardiocentesis was performed and submitted for cytological evaluation, microbiology, and RT-PCRs (*Anaplasma* spp., *Bartonella* spp., *Ehrlichia* spp. and *Leishmania* spp). Moreover, hematology, serum biochemistry and electrophoresis, urinalysis, and serology for leishmaniosis, ehrlichiosis and anaplasmosis.

Results

PE was classified as exudate with predominance of macrophages containing *Leishmania* amastigotes. Additional findings included abdominal transudate, non-regenerative anemia, polyclonal gammopathy, hypoalbuminemia and elevated C-reactive protein. Serology and qPCR for leishmaniosis were positive (77,300 parasites/1 million cells), while no other pathogens were found. After 15 days of allopurinol, meglumine antimoniate and specific treatment for pleural effusion, favorable clinical response was observed, and PE had resolved. Six months later, the patient was seronegative.

Conclusion

The visualization of amastigotes and the high parasite load of *Leishmania* spp. on PE supported the suspicion that PE was a clinical manifestation of leishmaniosis, highlighting that CanL should be included in the differential diagnosis of PE in dogs in endemic areas. Unlike what was observed in previously published cases, a favorable clinical and serological evolution was achieved after treatment.

Acknowledgements: We are grateful to personnel of the IDEXX Laboratories, especially to Dr. Nikola Pantchev for his scientific advice.

Poster Abstracts Clinical Pathology

10 | THE SIGNIFICANCE OF SERUM PROTEOME ANALYSIS IN DIAGNOSIS OF CANINE IDIOPATHIC EPILEPSY

R. D. Baka¹, J. Kuleš², A. Beletić^{3,4}, V. Farkaš³, D. Rešetar Maslov³, B. Beer Ljubić⁵, I. Rubić³, V. Mrljak^{3,5}, M. MacLaughlin⁶, D. Eckersall⁶ and Z. Polizopoulou¹

1Diagnostic Laboratory, Faculty of Veterinary Medicine, School of Health Sciences, Aristotle University of Thessaloniki, Thessaloniki, Greece, 2Department of Chemistry and Biochemistry and 3Laboratory of Proteomics, Internal Diseases Clinic, Faculty of Veterinary Medicine, University of Zagreb, 4Genos Ltd, Glycoscience Research Laboratory and 5Internal Diseases Clinic, Faculty of Veterinary Medicine, University of Zagreb, Zagreb, Croatia and 6Institute of Biodiversity, Animal Health & Comparative Medicine and School of Veterinary Medicine, College of Medicine, Veterinary Medicine and Life Sciences, University of Glasgow, Glasgow, United Kingdom

Background

Despite advances in veterinary neurology, canine idiopathic epilepsy (IE) still represents a diagnostic challenge. Proteomic studies contribute to a better understanding of the pathogenesis and identification of biomarkers candidates.

Objective

The purpose of the study was to investigate serum proteome profile of two groups of IE dogs and compare findings with healthy controls.

Methods

Three groups of dogs (group A: healthy controls, group B: IE receiving antiepileptic medication (IE-AEM), and group C: IE dogs without treatment) were included. Proteomic analysis of serum samples employed the quantitative Tandem-Mass-Tags approach using the Ultimate 3000 RSLCnano instrument coupled with Q-Exactive-Plus mass-spectrometer.

Results

The relative abundance of 81 proteins differed between the three groups and 25 of them were master proteins. Clusterin (CLU), and apolipoprotein-A1 (APOA1) had higher abundance in groups B and C compared to A. Amine oxidase (AOC3) was higher in abundance in group B compared to group C, but lower than in group A. Haptoglobin (HP) abundance differences showed the pattern inverse to AOC3. The difference in adiponectin (ADIPOQ) abundance was also present among all three groups, with the highest values in group B, followed by group C and the lowest in group A. Groups B and C differed in abundance of fibronectin (FN1), with the highest values present in group B.

Conclusion

Study results indicated CLU as a potential marker of epilepsy, changes in APOA1 abundance as a potential indicator of nerve tissue regeneration, and AOC3 as a contributing factor to epileptogenesis. AEM could alter extracellular matrix proteins (FN1).

Poster Abstracts Clinical Pathology

11 | AUTOMATED DIFFERENTIAL CELL COUNT IN BRONCHOALVEOLAR LAVAGE FLUID (BALF) OF WISTAR RATS WITH THE XN1000VET HEMATOLOGY ANALYZER

V. Strauss and S. Gröters

Experimental Toxicology and Ecology, BASF SE, Ludwigshafen, Germany

Background

Differential cell count in BALF of rats is an obligatory investigation in inhalation toxicity studies. The manual differential cell count is a laborious work, and the question is if an automated, differential cell count in BALF can be used as screening method.

Objective

1. automated counting of total cells in bronchoalveolar lavage fluid (BALF) of rats; 2. estimation of ratio of mononuclear cells (macrophages, monocytes, lymphocytes) and polymorphonuclear cells (mainly neutrophils) in BALF

Methods

optimization of scattergram gate setting after measurement of 15 BALF samples of healthy rats and 5 BALF samples with neutrophilia in the body-fluid-mode (BF) of the hematology instrument XN1000vet, Sysmex, Norderstedt, Germany; measurement of two sets of 20 BALF samples each for validation of the optimized gates; comparison of the results with manual total cell counts in a Neubauer counting chamber, and microscopic differential cell counts of the samples after a WRIGHT stain.

Results

Total cell counts of rat BALF samples of the XN1000vet correlate well with the manual counts. The differentiation of the BALF cells in mononuclear cells and polymorphonuclear cells of the XN1000vet instrument correlates with the microscopic differential cell count.

Conclusion

The BF mode of the XN1000vet instrument can be used to measure total cell counts in rat BALF samples including a categorization of the cells in mononuclear and polymorphonuclear cells as screening method.

Poster Abstracts Clinical Pathology

13 | REFERENCE INTERVALS AND INFLUENCE OF SAMPLING TECHNIQUE ON CANINE TEG VELOCITY CURVE VARIABLES AND DELTA

A. Gläsel¹, O. Eralp Inan², E. Er³ and N. Bauer¹

¹Department of Veterinary Clinical Sciences, Clinical Pathophysiology and Clinical Pathology, Justus-Liebig-University Giessen

²Department of Animal Science, Faculty of Agriculture, Eskisehir Osmangazi University, Eskisehir, Turkey and

³Biocontrol, Bioscientia Institute for Medical Diagnostics GmbH, Germany

Background

Thrombelastography (TEG) evaluates the overall clotting properties of whole blood via viscoelastic measurements. The velocity curve (VC) represents the first mathematical derivative of the TEG and generates additional variables: maximum rate of thrombus generation (MRTG), time to maximum rate of thrombus generation (TMRTG) and thrombus generation (TG). These variables further characterize the clotting process. Delta is another novel variable thought to evaluate initial thrombin generation and may be able to differentiate the cause of hypercoagulable states (platelet activation versus plasmatic hypercoagulability).

Objective

Provide reference intervals (RI) for VC-variables and Delta and evaluate the influence of four different blood sampling techniques (20-gauge intradermic needle, 18-gauge venous catheter, 14-gauge central venous catheter via Seldinger technique, 13-gauge central venous catheter via catheter-through-the-needle method).

Methods

TEG data from 56 healthy dogs (31 male, 25 female; aged 1-6 years) and 6 healthy Beagles (4 males, 2 females; aged 2-3 years) was retrospectively analyzed to calculate RIs (using Reference value advisor) and influence of sampling respectively. Analysis was performed on TEG-5000 with recalcified citrated whole blood 60 minutes after sampling using Kaolin as an activator. VC parameters were calculated based on clot strength (G).

Results

Calculated RIs were as follows: MRTG (0.78-8.0 dyn/cm²/s), TMRTG (3.2-15.9 min), TG (325.5-1036.1 dyn/cm²), Delta (0.0-1.3 min) and SP (1.1-7.6 min). Friedmann test to evaluate possible sampling effects showed p-values > 0.25 for all tested TEG variables.

Conclusion

Reference intervals were calculated and no effect could be shown using different sampling methods for any of the TEG variables.

Poster Abstracts Clinical Pathology

16 | A STUDY OF TWO ACUTE PHASE PROTEINS IN CATS WITH GINGIVITIS

I. Oikonomidis¹, I. Kavarnos², S. Papadimitriou², J.J. Ceron³, M. Kouki², K. Adamama-Moraitou² and N. Soubasis²

¹ Diagnostic Laboratory, School of Veterinary Medicine, Aristotle University of Thessaloniki, Thessaloniki, Greece; ² Clinics of Companion Animals, School of Veterinary Medicine, Aristotle University of Thessaloniki, Thessaloniki, Greece; ³ Interdisciplinary Laboratory of Clinical Analysis, University of Murcia, Murcia, Spain

Background

Periodontal disease has been associated with acute phase reaction in both humans and dogs. Chronic gingivostomatitis has been associated with increases in α 1-acid glycoprotein and serum haptoglobin (Hp) in cats. However, serum amyloid A (SAA) and Hp have not been previously evaluated in cats with uncomplicated gingivitis.

Objective

To compare SAA and Hp between cats with gingivitis and healthy cats, and to investigate the correlation between these two proteins and the severity of gingivitis.

Methods

Adult, FIV and FeLV seronegative cats were included. The cats were allocated into two age- and sex-matched groups. Case group included cats with gingivitis and control group included clinically and clinicopathologically healthy cats. The severity of gingivitis was assessed by the Total Mouth Periodontal Score (TMPS)-G index. Serum samples were used to measure SAA and Hp using a previously validated turbidimetric immunoassay and haemoglobin-binding method, respectively.

Results

Twenty-two cats were included (11 in control and 11 in case group). The median (range) age of cats was 5.0 (3.0-11.0) years. The median Hp concentration was significantly higher ($P=0.001$) in the case group [2.40 (0.72-4.44) g/L] compared with the control group [1.06 (0.50-1.42) g/L]. A significant correlation was found between Hp and TMPS-G ($\rho=0.636$, $P=0.040$). The SAA was below the detection limit (0.4 mg/L) in all samples of the control group and in 10/11 samples of the case group.

Conclusion

Feline gingivitis is associated with increased Hp, suggesting the presence of acute phase reaction. Haptoglobin appears to be correlated with the severity of the disease.

Poster Abstracts Clinical Pathology

18 | PERFORMANCE OF SYSMEX XT, SYSMEX XN-VET AND MANUAL METHODS ON CHICKEN BLOOD: A COMPARISON STUDY

D. Legroux¹, L. Kersten¹, G. Barral¹, A. Mauras¹, T. Buronfosse¹ and E. Ramery¹

¹VetAgro-Sup and 1Oniris, France

Background

Because they have nucleated red blood cells and thrombocytes, birds' haematology parameters are challenging to evaluate and manual methods are privileged. However, it is time consuming, especially when dealing with large numbers series. We hypothesized that new generation haematology analysers might be of help.

Objective

To determine if automated analyser Sysmex XT and Sysmex XN-Vet can be used in poultry haematology.

Methods

In order to evaluate their performance, we compared results obtained by manual methods and Sysmex XT and Sysmex XN-Vet analysers, using 309 and 84 chicken EDTA blood samples, respectively.

Results

There was good correlation between the gold standard packed cell volume (PCV) and hematocrit measured with Sysmex XT analyser ($R_s=0,81$). The intercept of the regression curve was close to 1. Bias was below 4%. On the contrary, the correlation was poor between XT and XN Vet ($R_s=0,41$) and between XN Vet and PCV ($R_s= 0,39$). There was no correlation between white blood cells (WBCs) manual counts and automated counts.

Conclusion

The study confirmed Sysmex XT and Sysmex XN-Vet haematology analysers are not able to evaluate WBCs and platelets. However, hematocrit and red blood cells parameters appeared to be reliable on Sysmex XT, but not XN-Vet.

Acknowledgements: We would like to thank Iodolab for their help in collecting samples.

Poster Abstracts Clinical Pathology

22 | COMPARISON STUDY OF HEMOGLOBIN VALUES IN BLOOD FROM JUGULAR AND CEPHALIC VEINS IN HEALTHY CATS

R. Moreira¹, R. Marcos², M. Santos², M. Morais¹ and R. Ferreira¹

¹Animal Blood Bank, Porto, Portugal; and ²Cytology Diagnostic Services, Institute of Biomedical Sciences Abel Salazar, University of Porto, ICBAS-UP, Porto, Portugal

Background

Capillary blood has higher hemoglobin (Hb) and hematocrit values than venous blood in human medicine. Differences in Hb have also been described in humans when a tourniquet has been left too long, causing hemoconcentration. Such differences in Hb between blood collected at different sites have never been detailed in cats. However, such knowledge may be relevant when evaluating hematological parameters.

Objective

To assess and compare Hb values obtained in blood from jugular and cephalic veins in healthy cats.

Methods

Private-owned healthy cats were recruited at Animal Blood Bank (Porto, Portugal) between September/December 2021. Immediately before the donation, blood was collected from the cephalic and jugular veins. A 24-gauge catheter collected the cephalic vein's blood and in the jugular vein by a 25-gauge needle attached to a five-milliliter syringe, with a minute maximum difference between the two collections. Hb measurement was performed by photometry using a portable device (Compolab). The mean and SD were calculated for each location, and a paired sample t-test was performed.

Results

A total of 867 healthy felines blood donors were enrolled. Samples with hemolysis were excluded. Cephalic blood samples presented significantly higher Hb values (13.95 ± 0.06 compared to the jugular vein (12.62 ± 0.06 g/dl) ($p < 0.01$).

Conclusion

Significant different Hb values can be obtained depending on the collection site. Such differences are related to minor but significant hemoconcentration in cephalic vein samples. Further studies are warranted to understand these findings by comparing other analytical parameters.

Poster Abstracts Clinical Pathology

23 | LEUKOCYTE COUNTS IN DOGS WITH ACUTE LEUKAEMIA (223 CASES)

M. Guzera^{1,2}, D. Ippolito³, T.L. Williams¹, M. Aquino Cleto⁴, L.G. Moreno Perez⁴, G. Polton⁵ and J. Archer¹

¹Department of Veterinary Medicine, University of Cambridge, Cambridge, United Kingdom

²Laboklin Polska, Warsaw, Poland

³Department of Veterinary Sciences, University of Turin, Turin, Italy

⁴National Autonomous University of Mexico, Mexico City, Mexico and ⁵North Downs Specialist Referrals, Bletchingley, United Kingdom

Background

Acute leukaemia (AL) is a group of malignancies deriving from immature hematopoietic cells.

Objective

The study aim was to determine leukocyte counts in a large group of dogs with various AL subtypes.

Methods

Cases of dogs diagnosed with AL using haematology (Sysmex XT-2000iV analyser) and flow cytometry between 2013 and 2017 were categorized into acute lymphoblastic leukaemia (ALL), acute myeloid leukaemia (AML) and acute undifferentiated leukaemia (AUL). Data are presented as median (range) and comparisons between groups were made using non-parametric statistics.

Results

152 (68%) ALLs, 38 (17%) AMLs and 33 (15%) AULs were included. WBC count of all dogs with AL was $67.91 \times 10^9/L$ (range: 2.51-907.77 $\times 10^9/L$). WBC count was higher in ALL than in AML ($75.52 \times 10^9/L$ (range: 6.21-907.77 $\times 10^9/L$) vs. $52.31 \times 10^9/L$ (range: 2.51-254.02 $\times 10^9/L$); $P=0.049$) and tended to be higher in ALL than in AUL ($53.98 \times 10^9/L$ (range: 3.35-574.8 $\times 10^9/L$); $P=0.076$). Overall, leukocytosis was present in 87.4% of AL dogs, specifically in 90.1% cases of ALL, 86.8% of AML and 75.8% of AUL. The leukocyte count was within the reference interval in 11.2% of AL cases, 9.9% cases of ALL, 10.5% of AML and 18.2% of AUL. Leukopenia was identified in only 3 AL cases (1.3%); its prevalence was higher in AUL than ALL (6.1% vs. 0%; $P=0.031$), but was not different between AUL and AML (6.1% vs. 2.6%; $P=0.594$) or between ALL and AML ($P=0.2$).

Conclusion

Leukocyte counts are significantly higher in ALL than AUL, whereas leukopenia is more common in AUL than ALL.

Poster Abstracts Clinical Pathology

24 | SUSPECTED PHENOBARBITAL INDUCED THROMBOCYTOPENIA IN A DACHSHUND

R. Mischke¹, A. Frommeyer¹ and E. Hühnerfauth¹

Small Animal Clinic, University of Veterinary Medicine Hannover, Hannover, Germany

Background

Haematological changes are common in dogs treated with phenobarbital although isolated thrombocytopenia has rarely been reported.

Objective

A 14-year-old dachshund suffering from gingival bleeding due to thrombocytopenia was referred to the Small Animal Clinic. The dog received treatment with phenobarbital due to epilepsy. The referring veterinarians had started treatment with prednisolone and doxycycline.

Methods

Apart from routine haematology, a bone marrow aspirate was assessed. Platelet associated antibodies were analysed flowcytometrically. Serological examination of various infectious agents was initiated.

Results

At initial presentation, platelet count was $6 \times 10^9/l$. Bone marrow aspirate revealed high thrombopoietic activity. Platelet associated antibodies were not detectable. Infectious serology revealed a high titer against *Anaplasma phagocytophilum* (EIA) of 48,97 TE (negative: < 8 TE), whereas titers against *Leishmania*, *Babesia canis*, *Ehrlichia canis*, and *Dirofilaria immitis* were negative. The patient did not respond to immunosuppression (prednisolone supplemented by azathioprine) and antibiotics (doxycycline, marbofloxacin). A possible idiosyncratic reaction to phenobarbital was considered and on day 12 imepitoin was administered parallelly to allow tapering of phenobarbital. After the relatively sudden stop of phenobarbital on day 17, additionally levetiracetam was temporarily applied. On day 4 after discontinuing the phenobarbital treatment, an extreme rebound thrombocytosis of $1,363 \times 10^9/l$ occurred, which further increased to $3,768 \times 10^9/l$ within the following days. Prednisolone and azathioprine were continuously reduced during following weeks. For more than one year, the platelet count remains within the reference range.

Conclusion

In this case, high-grade thrombocytopenia was likely a consequence of an idiosyncratic reaction induced by phenobarbital.

Poster Abstracts Clinical Pathology

26 | THE VALUE OF CYTOLOGY IN THE DIAGNOSIS OF ENDOMETRITIS IN THE MARE - CORRELATION WITH MICROBIAL CULTURE

I. Bessa de Carvalho¹, S. Conceição¹, H. Guimarães¹, C. Queiroga^{1,2}, M. Laranjo², E. Bettencourt^{1,2}, J. Lopes² and S. Branco^{1,2}

¹MED – Mediterranean Institute for Agriculture, Environment and Development & CHANGE – Global Change and Sustainability Institute, Institute for Advanced Studies and Research, Universidade de Évora, Évora, Portugal

²Departamento de Medicina Veterinária, Escola de Ciências e Tecnologia, Universidade de Évora, Évora, Portugal.

Background

Endometritis is a common cause of infertility in mares, and the presence of uterine inflammation can be determined by cytology or biopsy. Microbiological analyses and testing the sensitivity to antibiotics are important to maximise the therapy efficacy.

Objective

Our aim was to examine the relationship between the presence of inflammation and microbial growth, including its association to the presence of Gram-positive / Gram-negative bacteria.

Methods

Lusitano broodmares (n=112), aged 4-24 yo, in estrus (n=78) or diestrus (n=34), were evaluated during two breeding seasons. Uterine samples were collected aseptically by either: lavage (n=65), swab (n=13) or biopsy (n=34). For cytology, slides were Giemsa stained (inflammation >5% polymorph nuclear neutrophils). For microbiology, blood and McConkey agar were plated, followed by biochemical or molecular identification.

Results

Bacterial growth was found in 64.8% of the samples. Uterine biopsy was the method that detected more positive culture (76.5%), followed by lavage (60,3%). Within samples with positive culture, 63.6% showed no inflammation on cytology, followed by 18.2% presenting moderate inflammation. Absence of inflammation occurs more often with Gram-positive (66.7%) in comparison to Gram-negative bacteria (25.9%). Severe inflammation occurred more often in association with Gram-negative bacteria (66.7%). From the mares with negative culture, 36% had some degree of inflammation.

Conclusion

Mares with inflammation but no bacterial growth highlight the high sensibility of cytology in the diagnosis of uterine inflammation. A positive culture without inflammation nor clinical signs should not be considered pathogenic. In our mares, the presence of Gram-negative bacteria induced a stronger pro-inflammatory immune response.

Acknowledgements: This work was funded by Equi Mais (Project ALT20-03-0246-FEDER-000055) and FCT – Fundação para a Ciência e a Tecnologia (Project UIDB/05183/2020)

Poster Abstracts Clinical Pathology

30 | INTESTINAL METAPLASIA OF ESOPHAGEAL MUCOSA (BARRETT ESOPHAGUS) IN A CAT

M. Zanetti¹, G. Vichi¹, F. Raponi², M. Attini¹, C. Zamboni³, D. Olivero¹, S. Klenner-Gastreich⁴ and G. Ghisleni¹

¹Biessea - Laboratorio Analisi Veterinarie, a company of scil animal care company

²Endovet, Ancona, Italy

³Department of Veterinary Medicine (DIMEVET), University of Milan, Milan, Italy

⁴scil animal care company GmbH, Viernheim, Germany

Background

In veterinary medicine few reports exist regarding intestinal metaplasia of esophageal mucosa (Barrett esophagus-like lesions); a cytological evaluation of the lesions, associated with histological and endoscopic findings, has never been reported in the cat.

Objective

To describe the cytological findings in a case of intestinal metaplasia of esophageal mucosa in a 5-year-old castrated male Ragdoll cat presented for chronic gastrointestinal signs.

Methods

A clinical examination comprehensive of CBC, biochemistry profile and serum protein electrophoresis was performed, followed by esophagogastroduodenoscopy. Biopsies of the lesion were performed. Cytologic samples, obtained by squash preparation, were air-dried and stained with May-Grunwald-Giemsa. Subsequently the bioptic specimens were fixed in 10% buffered formalin and routinely processed for histology.

Results

Esophagogastroduodenoscopy revealed a localized proliferation in the distal part of the esophagus, characterized by irregular shape and surface, severe erosion and oedema. Cytologically, numerous well differentiated squamous epithelial cells arranged in large cohesive groups were seen; groups of columnar epithelial cells containing red-magenta granules were also present and were interpreted as muciparous goblet cells. Histological findings confirmed the hypothesis of Barrett esophagus-like lesion.

Conclusion

Barrett esophagus-like lesion is rare in cats and dogs; similarly to humans, neoplastic evolution is also reported in dogs. Cytological evaluation of the lesions can help differentiate it from other esophageal diseases and to evaluate a possible neoplastic transformation. To the authors knowledge, this is the first report that describes the cytological findings of intestinal metaplasia of esophageal mucosa in cats.

Poster Abstracts Clinical Pathology

31 | VITAMIN D AND ACUTE PHASE PROTEIN EXPRESSION IN DOGS WITH DIFFUSE B-CELL LYMPHOMA: ASSOCIATION WITH CLINICOPATHOLOGICAL PARAMETERS

M.D.C.P. Rocha¹, T.K. Garnica², H. Fukumasu², R.A.R. Uscategui³, J.M. Pazzini⁴, F.A.R. Sueiro⁵, I. Amorim⁶ and A.B. DeNardi¹

¹*Surgery and Clinical Veterinary, Universidade Estadual Paulista Júlio de Mesquita Filho (UNESP), Jaboticabal, Brazil*

²*Department of veterinary medicine, FZEA-Universidade de São Paulo (USP), Pirassununga, Brazil*

³*Grupo de investigación INCA-CES, Facultad de Medicina Veterinaria y Zootecnia, Universidad CES, Medellín, Colombia*

⁴*Department of veterinary medicine, União das Faculdades dos Grandes Lagos (UNILAGO), Rio Preto, Brazil*

⁵*CEO (Pathology and Molecular Biology) Employment, VETPAT Campinas, Campinas, Brazil*

⁶*CBAS School of Medicine and Biomedical Sciences, Porto University, Porto, Portugal*

Background

Lymphomas are a group of neoplasms that originate in lymphocytes which represents 8.8% of all cancers in dogs.

Objective

This study aimed to evaluate the serum concentration of vitamin D (25-Hydroxyvitamin D) and acute phase proteins (APPs; alpha1 acid glycoprotein, haptoglobin, transferrin, ceruloplasmin, albumin, IgA, IgG and alpha-1 - antitrypsin) as potential biomarkers for prognostic and therapy response in dogs with multicentric lymphoma submitted to CHOP (Cyclophosphamide, Doxorubicin, Vincristine and Prednisone) chemotherapeutic protocol.

Methods

Thirteen dogs diagnosed with high grade multicentric lymphoma were included in the treatment group (LG), while ten healthy dogs were included in the control group (GC). Diagnosis and staging were performed for all the LG dogs, based in cytopathology, histopathology and immunohistochemistry of the affected lymph node. Serum was collected a single time in the animals of CG, while in the animals of LG, serum was collected at weeks T0, T5 and T10 of CHOP chemotherapy. All the collected samples were evaluated for the APPs and vitamin D concentrations through electrophoresis and chemiluminescence methods, respectively.

Results

Of these dogs, 9 achieved a complete response and 4 a partial response to the adjuvant treatment. The results demonstrated that serum concentrations of IgA, haptoglobin and α 1-acid glycoprotein were significantly higher in the LG group and also between the different chemotherapy periods analyzed ($p < 0,05$).

Conclusions

These proteins can be considered sensitive biomarkers for lymphoma in dogs. Furthermore, the α 1-acid glycoprotein showed prognostic value for the disease, when compared with the survival time, with 63% specificity.

Acknowledgements: Acknowledgments to the research funding institution CAPES and UNESP-Jaboticabal

Poster Abstracts Clinical Pathology

33 | FLOW CYTOMETRIC CD44 AND CD45 EXPRESSION IN NEOPLASTIC AND REACTIVE NON-HEMOPOIETIC CELLS IN CANINE EFFUSIONS

F. Sini¹, B. Miniscalco¹, P. Valenti², M. Melega³, A. Poggi¹ and F. Riondato¹

¹Department of Veterinary Sciences, University of Turin, Turin, Italy

²Clinica Veterinaria Malpensa Anicura, Samarate, Italy

³Royal (Dick) School of Veterinary Studies, University of Edinburgh, Edinburgh, United Kingdom

Background

the identification of neoplastic non-hematopoietic (NH) cells in cavitory effusions is challenging. Flow cytometry can be used to characterize these cells.

Objective

this preliminary study aims to investigate CD44 expression in CD45-negative NH cells in canine effusions.

Methods

effusions analyzed by flow cytometry were retrospectively included and grouped in neoplastic (NEffs = 15) and reactive (REffs = 13) based on clinical and clinicopathological data including histopathology where available. The proportion of CD45-negative cells (%CD45neg), CD45 (autofluorescence) and CD44 normalized Median Fluorescence Intensity (nMFI) were recorded, and the CD44/CD45 ratio was calculated. %CD45neg, CD44nMFI, CD45nMFI and CD44/CD45 ratio were compared between the two groups (Mann-Whitney test). ROC curves were prepared for statistically different parameters and cut-off values to distinguish NEffs and REffs favoring specificity over sensitivity were defined.

Results

NEffs had higher %CD45neg cells ($p=0,001$). %CD45neg $>35,4\%$ and $<0,26\%$ had 100% specificity, 26,7% and 61,5% sensitivity for NEffs and REffs, respectively. NEffs had lower CD44nMFI (4,8 vs 25,4; $p=0,025$), higher CD45nMFI (0,57 vs 0,22; $p=0,001$) and lower CD44/CD45 ratio (9,1 vs 74,5; $p=0,002$). CD44/CD45 ratio <4 and $>106,3$ had 100% specificity, 33% and 39% sensitivity for NEffs and REffs, respectively.

Conclusion

a combined flow cytometric CD44/CD45 labelling can contribute to distinguish neoplastic and non-neoplastic NH cells in effusions by measuring the %CD45neg cells, autofluorescence and CD44-MFI. These preliminary results have to be confirmed in a larger series of cases.

Poster Abstracts Clinical Pathology

34 | SEQUENCING OF THE SOUTHERN WHITE RHINOCEROS (CERATOTHERIUM SIMUM SIMUM) CARDIAC TROPONIN I GENE AND ANALYTICAL VALIDATION OF A POINT-OF-CARE CARDIAC TROPONIN I IMMUNOASSAY

Y. Rautenbach^{1,2}, S.D.C. Parsons³, A. Goddard^{1,2}, L.C.R. Meyer^{4,2}, P. Buss^{5,2} and E.H. Hooijberg^{1,2}

¹Department of Companion Animal Clinical Studie

²Centre for Veterinary Wildlife Research

³Afrivet Business Management, Pretoria, South Africa

⁴Department of Paraclinical Sciences, Faculty of Veterinary Science, University of Pretoria, Onderstepoort, Pretoria, South Africa

⁵Veterinary Wildlife Services, South African National Parks, Kruger National Park, Skukuza, South Africa

Background

Conservation strategies for the critically endangered white rhinoceros (*Ceratotherium simum simum*) often involve chemical immobilization and translocation. Dehydration, acid-base disturbances, hypoxemia, negative energy balance, stress-induced immunomodulation, and skeletal muscle injury are common adverse changes in translocated rhinoceros. Investigation into potential concurrent myocardial injury in transported rhinoceros is limited due to a lack of validated immunoassays.

Objective

Firstly, to determine the mRNA transcript sequence of white rhinoceros's cardiac troponin I (cTnI) and evaluate sequence homology. Secondly, to validate a point-of-care cTnI immunoassay.

Methods

RNA was extracted from ventricular myocardium of deceased adult white rhinoceros and complementary DNA was synthesized via rt-PCR and sequenced. Analytical method validation of the Siemens Stratus CS 200 Acute Care Analyzer included linearity, repeatability, reproducibility, recovery and detection limit experiments using homogenates of rhinoceros myocardium and serum. Results were assessed against prescribed total allowable error (TEa) of 70% for cTnI.

Results

The nucleotide sequence identity of the rhinoceros cTnI gene with human and equine cTnI genes was high (97% and 96%, respectively). Predicted amino acid sequence matched assay antibody epitope-binding sites. The assay was linear within a range of 0.05-38.39 ng/mL. Imprecision ranged from 1.9%-8.0%. The proportional systematic error was -46.2% and was < TEa. Limit of the blank was below the detection limit of the assay (<0.03 ng/mL) and the limit of detection was 0.04 ng/mL.

Conclusion

The Stratus CS 200 is suitable for the measurement of cTnI in white rhinoceros and can be used to investigate potential myocardial injury in this species.

Acknowledgements: Funding was obtained from the Health and Welfare Sector Education and Training Authority (HWSETA) and the European College of Veterinary Clinical Pathology (ECVCP) Research Fund.

Poster Abstracts Clinical Pathology

35 | URINARY PROTEIN-TO-CREATININE RATIO (UPC) IN THE EUROPEAN HEDGEHOG ERINACEUS EUROPAEUS: CLINICAL USE AND REFERENCE INTERVAL ESTABLISHMENT

J. Botman¹, P. Gourlay¹, L. Chauvin¹, D. Legroux¹, F. Ayrat¹ and E. Ramery¹

¹Wildlife Health Centre, University Veterinary Hospital, Oniris National Veterinary College and 1VetAgro-Sup, France

Background

European hedgehogs *Erinaceus europaeus* are very commonly admitted in wildlife rescue centers in France. In order to ease the medical triage, clinicians are looking for lab tests useful to predict the outcome. Whereas blood sampling can be challenging in this species, urine collection by cystocentesis is easy to perform during the routine admission inhalant chemical restraint.

Objective

To determine if admission UPC could bring useful information on the outcome of distressed wild hedgehogs, and to generate UPC reference intervals in hedgehogs.

Methods

Between 20th April 2022 and 20th June 2022, UPC was determined on 53 wild hedgehogs at admission and their respective outcome (dead vs. released) was recorded. In addition, UPC was performed on 59 recovered and ready-to-be-released hedgehogs, with the aim to establish reference values using Reference Value Advisor.

Results

Extremely variable UPC values were detected at admission, with no significant difference between hedgehogs that survived (Min-Max-Mean-Median:0.7-43.3-6.2-4.2) and those who died (Min-Max-Mean-Median:1.1-41.9-8.2-4.6). The reference interval obtained from the ready-to-be-released hedgehogs was [0.2-1.8] with 90% confidence interval (CI) for lower limit [0.2-0.3] and 90% CI for upper limit [1.6-1.9].

Conclusion

The admission UPC is not predictive of the outcome of distressed wild hedgehogs. UPC values in hedgehogs in apparently good health condition were wider and higher compared to small domestic mammal species (Cat, Dog, Ferret). This might reflect subclinical renal disease or physiologic proteinuria.

Poster Abstracts Clinical Pathology

36 | AVIAN MALARIA IN PENGUINS. TWO CASE REPORTS IN AFRICAN PENGUINS (SPHENISCUS DEMERSUS)

M. Attini¹, M. Zanetti¹, C. Curcio¹, G. Tramontano¹, A. Torri¹, F. Grande¹, R. Capitelli², P. Roccabianca³ and G. Ghisleni¹

¹BiEsseA Laboratorio analisi veterinarie, a company of scil animal care company Loro Parque Fundación - Avenida Loro Parque sn - 38400 Puerto de la Cruz, Tenerife, Spain

²CSV-Labvet, Cornaredo, Italy

³Department of Veterinary Medicine (DIMEVET), University of Milan, Milan, Italy

Background

Avian Malaria (AM) is a mosquito-borne disease of birds caused by Plasmodium spp. and it is subclinical in native birds. The family Spheniscidae is especially susceptible to infection. AM cause significant mortality in captive penguins. In susceptible penguins, Plasmodium species mainly elicit acute disease without clinical specific signs, and because of the low parasitemia, destruction of red blood cells is not severe enough to induce clinical overt anemia.

Objective

To outline the clinical signs and pathology of AM in two African penguins (*Spheniscus demersus*) living in an openair colony.

Methods

The penguins died within few days of the onset of nonspecific clinical signs. CBC, biochemistry, and electrophoresis were performed before death. Necropsy was performed, and main organs were harvested. Microbial cultures, ELISA for exotoxins and PCR for Plasmodium spp. were carried out on selected organs. Cytological samples, obtained by tissue's imprint, were stained with May-Grunwald-Giemsa. Tissue specimens were fixed in 10% buffered formalin and routinely processed for histology.

Results

In both penguins, neither parasitemia nor significant laboratory abnormalities were detected except for marked dyserythropoiesis in only one penguin. On gross examination, multi-organ granulomatous lesions and pericardial effusion were present. Cytology revealed meronts, free and within the cytoplasm of hematopoietic cells. PCR on lung and brain tissues amplified Plasmodium spp.

Conclusion

As previously reported, due to the acute clinical course of disease, the diagnosis of AM is frequently only possible post-mortem by PCR. Cytology of the affected organs may represent a rapid and useful diagnostic tool for Plasmodium spp. detection.

Poster Abstracts Clinical Pathology

37 | A COMPARISON STUDY BETWEEN THE SIEMENS ADVIA 120 AND THE MANUAL METHOD FOR THE DIFFERENTIAL WHITE BLOOD CELL COUNT IN GOATS

T.Tsouloufi, C. Brozos, M. Kritsepi-Konstantinou, E. Kiossis and I. Oikonomidis.

School of Veterinary Medicine, Aristotle University of Thessaloniki, Greece

Background

The Advia 120 haematology analyser has not been previously validated for determining the differential leukocyte count in goats.

Objective

To compare the differential leukocyte counts provided by the Advia 120 (A-diff) and the manual method (M-Diff) in goats.

Methods

EDTA blood samples that were analysed within 4h of collection were used in the study. The following exclusion criteria were applied: inappropriately filled tubes or tubes containing clots, erroneous Advia peroxidase cytograms, and blood smears of poor quality. The A-Diff was compared to the M-Diff performed by two independent observers on 200 leukocytes.

Results

Forty-eight samples were initially included. Eight samples were excluded from further analysis. The correlation between the A-Diff and M-Diff was very strong for eosinophils ($\rho=0.870$, $P<0.001$), and strong for lymphocytes ($\rho=0.796$, $P<0.001$) and neutrophils ($\rho=0.730$, $P<0.001$), while no significant correlation was observed for monocytes ($\rho=0.026$, $P=0.872$). The Passing-Bablok regression analyses revealed statistically significant constant errors for neutrophils [5.83%; 95% confidence interval: 0.41-12.18%] and eosinophils [1.89%; 95% confidence interval: 1.17-2.71%]. Bland-Altman analyses showed a statistically significant negative bias for lymphocytes (-5.0%) and a statistically significant positive bias for eosinophils (2.2%). The very low basophil percentages precluded a meaningful method comparison.

Conclusion

The Advia 120 demonstrated an overall good performance for the differential WBC count in goats under the conditions of this study. Therefore, it can be considered suitable for routine hematologic screening in goats. Nonetheless, it should be emphasized that any abnormal result should be confirmed with a blood smear evaluation.

Poster Abstracts Clinical Pathology

39 | PRESUMED PSEUDO-PELGER-HUËT ANOMALY AND BASOPHILIA IN A DOG SECONDARY TO CHRONIC LYMPHOCYTIC LEUKAEMIA - CASE PRESENTATION

J. Martínez-Caro¹, B. Agulla¹, C. Viñeta², M. Mesalles³ and J. Pastor¹

¹*Departament de Medicina i Cirurgia Animals*

²*Hospital Clínic Veterinari, Universitat Autònoma de Barcelona, Barcelona, Spain*

³*Departament de Medicina i Cirurgia Animals, Universitat Autònoma de Barcelona, Barcelon, Spain*

Background

Two forms of Pelger-Huët anomaly have been described in dogs, including an inherited condition and an acquired or pseudo Pelger-Huët anomaly (PPHA).

Case description

A 10-year-old, neutered male Maltese dog presented for investigation of lymphocytosis. The animal was properly vaccinated and dewormed. Physical examination did not reveal any significant abnormalities. CBC showed mild leucocytosis with moderate lymphocytosis, basophilia and neutropenia with no left shift or toxic change. Serum biochemistry and urinalysis were unremarkable. All performed tests for common geographical infectious agents were negative: serology for *Leishmania* spp. (ELISA); for *Ehrlichia canis* and *Ehrlichia ewingii*, *Borrelia burgdorferi*, *Anaplasma phagocytophilum* and *Anaplasma platys* and antigen detection of *Dirofilaria immitis* (SNAP 4Dx Plus Test); and PCR for *Babesia* spp. and *Theileria* spp. Flow cytometry of peripheral blood revealed a CD8+ T-cell lymphocytosis. PARR test performed on IDEXX Laboratories revealed a clonal expansion of T-cell receptor gamma chain genes. On day 48 post-presentation CBC showed mild non-regenerative anaemia (NRA), moderate leucocytosis due to lymphocytosis, basophilia and marked increased non-segmented neutrophils with mild toxic change. Treatment with chlorambucil and prednisolone was initiated. On day 87, CBC showed mild NRA and slight increase in non-segmented neutrophils.

Discussion

A diagnosis of chronic lymphocytic leukaemia (CLL) was made due to the monoclonal expansion of CD8+ T-cells and exclusion of common infectious aetiologies or any evident organomegaly or lymph node enlargement. Basophilia and probable PPHA were considered possibly secondary to CLL. To the authors' knowledge, this is the first report of PPHA secondary to CLL in dogs.

Poster Abstracts Clinical Pathology

41 | GRANULOMATOUS INFLAMMATION IN A TURTLE (*TRACHEMYS SCRIPTA ELEGANS*) WITH THROMBOPHAGOCYTOSIS AND LEUKOPHAGY IN PERIPHERAL BLOOD

C. Meneses Nava, A. Majluf Trejo and M. Guadarrama Olhovich

UNAM, CDMX, Mexico and UNAM, Mexico

Background

There is scarce information about hemophagocytic syndromes or macrophage/monocytic hyperactivation secondary to inflammatory processes in veterinary medicine; it is believed that it may be related to immune complex deposition, cross-antigenicity, or a cytokine storm, as in humans.

Objective

A 5-year-old red-eared slider (*Trachemys scripta elegans*) was taken to the Exotic Animal Hospital (FMVZ-UNAM) showing a mass in the right pelvic limb with 6 years of evolution; in addition to several months of anorexia.

Methods

The radiographic study showed an increase in soft tissue density and a fine needle puncture was taken for cytological evaluation. Septic heterophilic macrophage inflammation with a mixed microbiome were observed, as well as spindle cells with moderate dysplastic changes secondary to the inflammatory process. Antibiotic and anti-inflammatory treatment was established, with no response. A sample was taken for a complete blood count and blood chemistry tests.

Results

Monocytosis $1.17 \times 10^9/L$ [$0.04 - 0.65 \times 10^9/L$] and hyperproteinemia of 66 g/L [$36 - 53 \text{ g/L}$] were found, along with changes related to chronic inflammation. Monocytes phagocytizing thrombocytes and heterophils were observed by blood smear evaluation. Due to the poor response to treatment, it was decided to perform surgical debridement of the lesion.

Conclusion

More studies are needed to clarify the pathophysiology and diagnosis of this type of alterations in turtles; however, this clinical case is reported as an precedent of the findings in turtles with chronic inflammation.

Poster Abstracts Clinical Pathology

42 | KI67 INDEXES IN PAIRED CYTOLOGICAL SMEARS AND CELL BLOCKS OF CANINE LYMPHOMA: PRELIMINARY RESULTS

F. Sampaio^{1,2}, C. Marrinhas^{1,3}, L. Fonte Oliveira^{1,4}, F. Malhão¹, C. Lopes¹, H. Gregório⁴, C. Correia-Gomes⁵, R. Marcos¹ and M. Santos¹

¹Cytology and Hematology Diagnostic Services, ICBAS - School of Medicine and Biomedical Sciences, University of Porto

²Laboratório INNO, Braga, Portugal

³Hospital do Baixo Vouga, OneVet Group, Águeda, Portugal

⁴Anicura CHV Porto, Porto, Portugal and ⁵Animal Health Ireland, Carrick-on-shannon, Ireland

Background

Ki67 is a protein expressed in all the cell cycle phases, except G0 and is used as a proliferation marker in canine lymphoma (CL). Ki67 protein can be immunodetected on biopsies and cytology smears of CL. Ki67 index cut-offs with prognostic significance have been defined for histopathology and flow-cytometry.

Objective

Compare the Ki67 indexes estimated on previously-stained cytology smears and on matched cell tube blocks (CTB) of CL.

Methods

Previously-stained cytology smears and matched CTB of 20 cases CL were retrospectively selected. Ki67 immunolabelling with MIB-1 antibody was performed. Ki67 index was classified as low or high according to a previously reported cut-off (12.2%) defined by flow-cytometry. The correlation between the Ki67 indexes values and the agreement of the low/high Ki67 index classification were statistically analysed.

Results

There was no significant correlation between Ki67 indexes obtained on the cytology and CTB of 20 CL cases. Ki67 index classification was different in 6 cases, with 4 cases being classified as high Ki67 only on CTB. In these discrepant cases, the cytology smears had been archived for more than 24 months. The kappa value for the definition of low vs high Ki67 index was 0.74, indicating a moderate agreement.

Conclusion

The estimates of the Ki67 index on cytology and on paired CTB in CL cases can vary. However, when a Ki67 index cut-off of 12.2% for defining low vs high proliferative CL is used, the CTB and cytology tend to agree, especially in recent cytology cases.

Poster Abstracts Clinical Pathology

43 | INTRODUCTION OF NU.Q® VET CANCER TEST INTO A CLINICAL LABORATORY

E. De Faveri¹, G. Tramontano¹, C. Curcio¹, A. Torri¹, M. Zanetti¹, M. Attini¹, B. Carimati¹, S. De Cia¹, S. Dell' Aere¹, G. Ghisleni¹ and S. Klenner-Gastreich²

¹BiEsseA Laboratorio analisi veterinarie, a company of scil animal care company Department of Veterinary Medicine (DIMEVET), University of Milan, Milan, Italy

²scil animal care company GmbH, Viernheim, Germany

Background

Early screening of patients is of benefit to detection of neoplasia. Nucleosomes are small DNA fragments wrapped around a histone octamer nucleus. Neoplasms or inflammation cause cell death, resulting in fragmentation and release of nucleosomes into the blood. Nu.Q™ assay evaluates the level of nucleosomes derived from a neoplasm to detect and identify cancer, even in the early stages.

Objective

To describe the protocol adopted, after three months from the introduction of Nu.Q™ assay in our laboratory.

Methods

Nu.Q™ assay is an indirect quantitative sandwich ELISA with a capture antibody directed at histone H3.1. A standard curve was generated using the positive control stock provided. Values were distributed into three levels of risk: low (< 50 ng/ml), medium (51-80 ng/ml), high (> 81 ng/ml). Preanalytical errors were detected. Assays were performed on 237 samples.

Results

In agreement with previous studies, feeding, storage, shipping at improper temperature and processing time can significantly alter the plasma nucleosome concentration in dogs. In 4 samples the nucleosome concentration exceeded a value of 81 ng/ml (high risk for the presence of neoplasia). In all 4 cases, further investigations revealed neoplastic condition.

Conclusions

Nucleosome elevations often allow earlier detection of neoplasia and the Nu.Q™ assay can be a useful blood-based marker to screen patients. Preanalytical errors are mainly secondary to feeding and processing time. Due to the other possible causes of increased nucleosome concentrations, it is recommended to repeat the assay before starting further investigations.

Poster Abstracts Clinical Pathology

44 | REFERENCE INTERVALS FOR SERUM BIOCHEMISTRY IN ADULT MIRANDA'S DONKEYS

G. Silva¹, F. Queiroga^{2,3}, B. Leiva⁴, D. Andrade⁴ and A.C. Silvestre-Ferreira^{2,3}

¹Departamento de Ciências Veterinárias, Universidade de Trás-os-Montes e Alto Douro (UTAD), Vila Real, Portugal; ²Centro de Ciência Animal e Veterinária (CECAV), Universidade de Trás-os-Montes e Alto Douro, Vila Real, Portugal; ³Laboratório Associado para a Ciência Animal e Veterinária- AL4Animals, Portugal; ⁴Associação para o Estudo e Proteção do Gado Asinino (AEPGA), Atenor, Miranda do Douro, Portugal

Background

Miranda's donkeys is a Portuguese breed originally from the north of Portugal, considered endangered. Despite the increase in the number of animals, the breed still requires efforts in several areas for its preservation. The knowledge of normal serum biochemistry values is important to characterize the breed and assist veterinarians in the diagnosis of diseases.

Objective

The aim of this study was to determine reference intervals (RI) for serum biochemistry in a healthy adult population of Miranda's donkeys.

Methods

Blood samples were collected from 55 healthy adult Miranda's Donkeys (27 males, 28 females), aged 4-25 years old. All determinations were performed on the Response920 automated biochemistry analyzer and the RI were established with the Reference Value Advisor v2.1, strictly following American Society for Veterinary Clinical Pathology guidelines.

Results

The following IR have been established: Alkaline phosphatase (68.6-232.5 U/L), albumin (2.5-3.4 g/dl), alanine aminotransferase (1.8-8.2 U/L), aspartate aminotransferase (151.6-366.2), total bilirubin (0.1-0.2 mg/dl), calcium (9.2-12.9 mg/dl), cholesterol (52.4-114.8 mg/dl), creatine phosphokinase (56.2-189.9 U/L), chlorine (97.7-112.3 mmol/l), creatinine (0.8-1.7 mg/dl), gamma-glutamyl transferase (11.2-47.9 U/L), globulin (2.8-4.8 g/dl), glucose (56.7-123.1 mg/dl), potassium (2.3-4.8 mmol/l), phosphorus (2.3-25.9 mg/dl), magnesium (1.7-2.9 mg/dl), sodium (125.8-140.3 mmol/l), total protein (5.6-7.8 g/dl), triglycerides (29.1-199.8 mg/dl), urea (12.2-46.2 mg/dl).

Conclusion

Several factors can influence biochemical parameters, such as race, sex, age and geographic location. The values described here can be used by veterinarians to assess and monitor the health status of animals and herds, helping to select suitable and healthy animals for reproduction, contributing to their preservation.

Acknowledgements: The authors would like to thank the Fundação para a Ciência e a Tecnologia (FCT), Centro de Ciência Animal e Veterinária (CECAV/project UIDP/CVT/00772/2020) and Associação para o Estudo e Proteção do Gado Asinino (AEPGA).

Poster Abstracts Clinical Pathology

46 | INTRACYTOPLASMIC GRANULES IN BLOOD NEUTROPHILS OF FRENCH BULLDOG: FRIENDS OR FOES?

M. Giraldi¹, P. Romanelli¹, L. Aresu², W. Bertazzolo¹, U. Bonfanti¹, S. Paltrinieri³

¹*Mylav – La Vallonea, Rho, Italy*

²*Dept of Veterinary Science, University of Turin, Grugliasco, Turin, Italy*

³*Dept of Veterinary Medicine and Animal Sciences, University of Milan, Lodi, Italy*

Background

Intracytoplasmic granules can be found in circulating neutrophils (CN) in various diseases or as inheritance in certain canine or feline breeds. However, they were never described in French Bulldogs (FB).

Objective

To describe CN intracytoplasmic granules in blood smears from FB and to provide preliminary information about their possible nature and significance.

Methods

May-Grunwald Giemsa-stained blood smears from 23 FB were examined microscopically. The dogs ranged from 6 months to 9 years; 13 were males and 10 females. One sample was also stained with toluidine blue and PAS and subjected to electron microscopy (EM). Clinical and hematological results, and geographical origin were also collected.

Results

In all 23 FB, small intracytoplasmic purple/reddish granules (1-2 micrometres in size, 2-10 per CN) were observed. EM and special stains did not reveal any abnormalities. All the dogs but one lived in central-northern Italy. The genetic relationship could not be determined. Three dogs exhibited thrombocytosis and one had neutrophilia. Clinical records were available for 12 dogs (3 healthy, 2 each with PU/PD, neurological signs, chronic enteropathy; 1 each with dermatitis, mast cell tumor, weight loss).

Conclusion

Intracytoplasmic granules are occasionally found in CN of FB. This finding is uncommon, as it was observed in a small number of cases compared to the total number of FB blood samples analyzed in the laboratory in the same period. The presence of these granules does not seem to be associated with specific clinical changes and the exact nature remains unknown.

Poster Abstracts Clinical Pathology

48 | DELTA TOTAL NUCLEATED CELLS ASSESSED VIA SYSMEX XT-2000IV AND SYSMEX XN-1000V ON FELINE EFFUSIONS: COMPARABLE DIAGNOSTIC ACCURACY FOR FELINE INFECTIOUS PERITONITIS

M Zanetti¹, S Paltrinieri², S Meazzi², S Novellini², V Martini², S Lauzi², S Rossi³, G Mangiagalli⁴, A Giordano²

¹Biessea Laboratorio analisi veterinarie, a company of Scil animal care company, Milan, Italy

²Dept of Veterinary Medicine and Animal Sciences, Lodi, Italy

³CDVet, Roma, Italy

⁴Veterinary Clinic Gran Sasso, Milan, Italy

Background

The Delta total nucleated cell count (DTNC), calculated based on the cell counter Sysmex XT-iV (DTNC-XT) DIFF and BASO counts on feline effusions, is higher in feline infectious peritonitis (FIP) cases than in any other disease. Indeed, BASO channel acidic reagent induces the formation of clots entrapping the cells, leading to a BASO count lower than the DIFF count. The new Sysmex-XN-V reagents used to count the cells in the WNR and WDF channels differ from those of Sysmex XT-iV. The performances of DTNC-XN to diagnose FIP have not been investigated yet.

Objective

To compare DTNC-XN and DTNC-XT values in feline effusions.

Methods

The DTNCs of 36 effusions analyzed with both instruments were compared and correlated to each other. The concordance in detecting samples with DTNC-XT >1.7 (suggestive of FIP, n=10) or >2.5 (consistent with FIP, n=9) was calculated. ROC curves were designed to assess the DTNC-XN discriminating power at these two thresholds.

Results

The median DTNC-XN (1.03) was lower ($P=0.017$) than the median DTNC-XT (1.14). The DTNCs correlated to each other ($P<0.001$; $r_s=0.706$) despite slight constant and proportional biases (intercept: -1.057; slope: 1.874). The DTNC-XN correctly identified 26/26 samples with DTNC-XT <1.7, 10/10 with DTNC-XT >1.7, 8/9 with DTNC-XT >2.5 and 27/27 with DTNC-XT <2.5. The AUCs of ROC curves were 1.000 ($P<0.001$) and 0.992 ($P<0.001$) for the thresholds of 1.7 and 2.5, respectively, with absolute specificity at DTNC-XNs of >1.4 and >5.3.

Conclusion

Despite differences in the raw values of both DTNCs, the diagnostic accuracy for FIP overlapped.

Poster Abstracts Clinical Pathology

50 | CANINE MAST CELL TUMOURS: PROGNOSTIC VALUE OF CYTOLOGY GRADING PARAMETERS IN ROUTINE STAINING AND HAEMATOXYLIN-EOSIN RESTAINING

G. Azevedo¹, C. Lopes¹, M. Caniatti², C. Correia-Gomes³, R. Marcos¹ and M. Santos¹

¹Laboratory of Histology and Embryology, ICBAS, Porto, Portugal

²Dipartimento di Medicina Veterinaria e Scienze Animali (DIVAS), Università degli Studi di Milano, Lodi, Italy

³Animal Health Ireland, Carrick-on-Shannon, Ireland

Background

Cytology plays a major role in the diagnosis of cutaneous canine mast cell tumors (MCTs). Different MCT grading systems have been applied to cytology, but the prognostic value of each system has never been fully compared. Theoretically, the use of staining that enhances nuclear details, such as hematoxylin-eosin (HE), may improve the prognostic value of nuclear grading parameters.

Objective

Assessing the clinical value of two cytological grading systems for MCTs. Comparing the prognostic role of evaluating nuclear grading parameters in smears routinely stained with May Grunwald-Giemsa (MGG) and restained with HE.

Methods

Routine cytology smears of 37 MCT cases with available clinical follow-up information, were graded by a consensus of two observers, using the cytology adaptation of the Kiupel and the Camus systems. The slides were then destained and restained with HE and the grade was reassigned blinded to the previous grade. The prognostic value of the grade and grading parameters was analyzed with regression tests.

Results

The cytological adaptation of the Kiupel grade was superior to the Camus grade in predicting survival. The presence of ≥ 7 mitotic figures (in MGG and HE smears) and the cytoplasmic granularity were the only grading parameters associated with survival. Restaining with HE did not significantly increase the prognostic value of the grade or nuclear grading parameters.

Conclusion

This study demonstrated that the cytological features of granularity and mitotic activity were prognostic factors in canine MCTs. The mitotic count in MCT smears should be included in cytology reports.

Poster Abstracts Clinical Pathology

51 | STABILITY OF MIRANDA'S DONKEY RED BLOOD CELL PARAMETERS AT ROOM AND REFRIGERATED TEMPERATURE AND FIVE PERIODS OF STORAGE WITH A PROCYTE DX HAEMATOLOGY ANALYSER (IDEXX)

A. Carneiro¹, G. Silva^{1,2,3}, F. Queiroga^{1,2,3}, Â. Martins^{2,3,4}, B. Leiva⁵, Z. Cruz⁵ and A. C. Silvestre-Ferreira^{1,2,3}

¹Departamento de Ciências Veterinárias, Universidade de Trás-os-Montes e Alto Douro (UTAD), Vila Real, Portuga; ²Centro de Investigação Animal e Veterinária (CECAV), Universidade de Trás-os-Montes e Alto Douro (UTAD), Vila Real, Portuga; ³Laboratório Associado de Zootecnia e Veterinária – AL4Animals, Portuga; ⁴Departamento de Zootecnia, Universidade de Trás-os-Montes e Alto Douro (UTAD), Vila Real, Portuga; ⁵ Associação para o Estudo e Proteção do Gado Asinino (AEPGA), Atenor, Miranda do Douro, Portugal

Background

It is advocate that haematological analyses be executed quickly after sampling. Miranda's donkey is an autochthonous Portuguese breed that lives in the Miranda plateau, delaying analysis due to shipment of specimens to a laboratory.

Objective

To evaluate the stability of Miranda's donkey red blood cell parameters at room and refrigerated temperature and five periods of storage with ProCyte Dx haematology analyser (IDEXX).

Methods

Eight EDTA-K2 whole blood samples were analysed, with ProCyte Dx (IDEXX), at room and refrigerated temperature and within 6, 12, 24, 48 and 72 hours of sampling following manufacturer's instructions. The stability of red blood cell parameters was evaluated using one-way analysis of variance (ANOVA) and Tukey's test for comparison of means if $p < 0.05$.

Results

Influence of storage time was observed. Red blood cell count was stable until 12h of sampling, haematocrit and haemoglobin until 6h. For mean corpuscular volume, mean corpuscular haemoglobin, mean corpuscular haemoglobin concentration and red cell distribution width (RDW) no statistically significant changes were found during the entire study period ($p > 0.05$). The stability of the parameters in refrigeration showed little or no change in relation to the ambient temperature in all studied parameters when compared to room temperature, RDW was stable only until 12 hours of sampling.

Conclusion

Storage at room temperature must take into account the different stability times and must not exceed 6 hours. Refrigeration has not been shown to have advantages over storage at room temperature. Awareness of this helps in avoiding pre-analytical errors in Miranda's donkey haematology.

Acknowledgements: The authors would like to thank the Fundação para a Ciência e a Tecnologia (FCT), Centro de Ciência Animal e Veterinária (CECAV/project UIDP/CVT/00772/2020).

Poster Abstracts Clinical Pathology

52 | ABC BLOOD GROUP SYSTEM IN CATS FROM LUANDA (ANGOLA) - PRELIMINARY STUDY

A.C. Silvestre-Ferreira^{1,2,3}, H. Vilhena^{2,3,4,5}, G. Silva^{2,3}, A.C. Oliveira⁶, J.R. Mendoza⁶, M.G. Aura⁶ and J. Pastor⁷

¹Departamento de Ciências Veterinárias, Universidade de Trás-os-Montes e Alto Douro (UTAD), Vila Real, Portugal; ²Centro de Investigação Animal e Veterinária (CECAV), Universidade de Trás-os-Montes e Alto Douro (UTAD), Vila Real, Portugal; ³Laboratório Associado de Zootecnia e Veterinária – AL4Animals, Portugal; ⁴Centro de Investigação Vasco da Gama (CIVG), Departamento de Medicina Veterinária, Escola Universitária Vasco da Gama (EUVG), Coimbra, Portugal; ⁵Onevetgroup Hospital Veterinário Universitário de Coimbra (HVUC), Coimbra, Portugal; ⁶Clínica Veterinária Casa dos Animais, Luanda, Angola; ⁷Departamento de Medicina e Cirurgia Animal, Universitat Autònoma de Barcelona (UAB), Barcelona, Espanha

Background

The most important blood group system in the cat is the ABC (former AB), in which cats are classified as type A, B or C. Cats express alloantibodies against the blood type they lack, as they do not require prior sensitization by transfusion, pregnancy, or other blood products. Alloantibodies are responsible for post-transfusion hemolytic reactions that can lead to the death of the animal if a type B cat receives type A or C blood and neonatal isoerythrolysis. Type A blood is the most prevalent across the world. Early studies in non-pedigree cats reported blood types B and C as rare. However, racial and geographic variations have been demonstrated.

Objective

To determine the prevalence of blood types A, B and C in a non-pedigree cat population from Luanda (Angola).

Methods

Forty-six samples obtained from 26 male and 20 female cats, aged between 8 months and 17 years, were typed by the immunochromatographic strip technique (QuickTest BT A+B, Alvedia, Limonest, France).

Results

The prevalence of blood types A, B and C was 95.7% (n=44), 4.3% (n=2) and 0% respectively.

Conclusion

To the best of our knowledge, this is the first study on the ABC blood group system in cats carried out on the African continent. The results underscore the usefulness of regional studies to identify different prevalences of cat blood types. Blood typing should be considered a fundamental test in cats of any origin as a way to ensure a safe and efficient blood transfusion and to prevent neonatal isoerythrolysis.

Acknowledgements: The authors would like to thank the Fundação para a Ciência e a Tecnologia (FCT), Centro de Ciência Animal e Veterinária (CECAV/project UIDP/CVT/00772/2020).

Poster Abstracts Clinical Pathology

54 | RECYCLE AND REPURPOSE - USEFULNESS OF IMMUNOHISTOCHEMISTRY ON CELL BLOCKS PREPARED FROM CYTOLOGY SLIDES

S Carvalho^{1,2*}; A Verdi^{3*}; R Noiva^{1,2*}

1CIISA - Centre for Interdisciplinary Research in Animal Health, Faculty of Veterinary Medicine, University of Lisbon and 2Associate Laboratory for Animal and Veterinary Sciences (AL4AnimalS), Lisbon, Portugal and 3Università degli Studi di Milano, Milan, Italy

* These authors contributed equally to this work

Background

Cytology is among the most used and fastest non-invasive techniques for the diagnosis of neoplasia in veterinary medicine but immunohistochemistry on cytology slides can be challenging, due to low cellularity or insufficient slides. Since biopsy samples are not always readily available, converting cytology slide samples into cell blocks could bypass the difficulties of immunohistochemistry in cytology.

Objective

This study aims to test the effectiveness of immunohistochemistry staining on cell blocks prepared from cytology slides.

Methods

10 mast cell tumor and 7 lymphoma archive cases were selected, diagnosed using both cytology and histology, between 2021 and 2023, at the Laboratory of Anatomic Pathology of the Faculty of Veterinary Medicine, ULisboa. Of these, 7 had previous immunohistochemistry results on histopathology/standard cell block samples (CD3 and CD20/Pax5 for lymphoma, and CD117 and Ki67 for mast cell tumors). Cytology slides of 13 of these cases were immersed in formalin and scraped for processing into Histogel® to make a cell block. Cell blocks were routinely processed for histopathology and, after evaluating cellularity, samples of 10 cases were stained by immunohistochemistry with appropriate markers (CD3/Pax5 or CD117/Ki-67).

Results

Results show that, in all 10 cases, while the cell blocks obtained had sufficient cellularity, cells did not stain consistently by immunohistochemistry with the antibodies and protocol used for standard cell blocks (positive controls stained as expected).

Conclusion

While this technique could increase the versatility of cytology samples for other diagnostic techniques, provided cellularity is sufficient, further refinement is necessary to make them compatible with routine immunohistochemistry.

Acknowledgements: This study has been funded by CIISA and by the Associate Laboratory for Animal and Veterinary Sciences (AL4AnimalS): UIDB/00276/2020 and LA/P/0059/2020.

Poster Abstracts Clinical Pathology

56 | NORMAL CYTOLOGICAL BONE MARROW EXAMS ASSOCIATED TO ALTERED HEMOGRAMS IN CATS: A RETROSPECTIVE STUDY

V. Turinelli¹, M. Quagliardi², G. Rossi² and A. Gavazza²

¹Idexx Laboratories, Milan, Italy and ²School of Biosciences and Veterinary Medicine, University of Camerino, Matelica (MC), Italy

Background

bone marrow and blood smear cytological analysis together with a complete hemogram represent the only method for examining the hematopoietic tissue and function. Sometimes in clinical practice, pathological hemograms are associated with cytological normal bone marrow exams

Objective

the aim of this retrospective study was to evaluate a series of feline cytological bone marrow samples, together with hematological and clinicopathological data. This, to judge if the normality of these cytological exams is reliable or if it indicates an intrinsic failure.

Methods

two-hundred-fourteen bone marrow samples and blood smears were examined using morphological and numerical criteria together with complete hemograms. Bone marrow cytological examinations were performed after the identification of hematological or clinical alterations such as anemia, leukocytosis, fever of unknown origin, and staging of neoplasia (i.e., lymphoma).

Results

among the 214 bone marrow samples evaluated, 41 (19%) were classified as normal. However, only 4 of those cases (10%) exhibited normal hemograms. The most common hematological anomalies, often seen in combination, were anemia (56%), thrombocytopenia (17%) and leucopenia (10%). Furthermore, anemia associated with other abnormal hematological findings (51 %) and lymphoma (15%)

Conclusion

this retrospective study suggests that bone marrow cytological exams, despite appearing normal in terms of morphological or numerical parameters, can still be associated with abnormal hemograms. As a result, they should not be automatically considered as clinically normal. Instead, they should prompt additional research and, occasionally, a second cytological bone marrow examination in the following days.

Poster Abstracts Clinical Pathology

57 | SERIAL MEASUREMENT OF MYELOPEROXIDASE INDEX AND ITS ASSOCIATION WITH OUTCOME IN HOSPITALISED DOGS WITH PARVOVIRAL ENTERITIS: PRELIMINARY RESULTS

T. Tsouloufi¹, K. Theodorou², I. Oikonomidis¹, E. Papaioannou², K. Adamama-Moraitou², M. Kritsepi-Konstantinou¹, V. Ntakis³, A. Konstantinidis² and N. Soubasis²

¹Diagnostic Laboratory, School of Veterinary Medicine, Faculty of Health Sciences, Aristotle University of Thessaloniki, Thessaloniki, Greece; ²Companion Animal Clinic, School of Veterinary Medicine, Faculty of Health Sciences, Aristotle University of Thessaloniki, Thessaloniki, Greece; ³Biomedical Sciences Research Center 'Alexander Fleming', Vari, Greece

Background

The myeloperoxidase index (MPXI) is a numerical estimate of the neutrophil myeloperoxidase content and a marker of neutrophil activation.

Objective

To serially evaluate MPXI in hospitalised dogs with canine parvoviral enteritis (CPVE) and compare it in dogs that died with survivors.

Methods

Data of hospitalised dogs with a diagnosis of CPVE were retrospectively reviewed. CBCs were run on ADVIA 120 and results were recorded for up to day 7 of hospitalisation. Survivors were defined as dogs that were discharged or were still hospitalised on day 7. Non-survivors included dogs that died during the 7-day hospitalisation period.

Results

Thirty-four dogs (26 survivors, 8 non-survivors) with a median (minimum, maximum) age of 3 (1.5, 12) months were included. The linear mixed effects model revealed a significant interaction between day of hospitalisation and outcome for MPXI ($P < 0.001$) and a significant effect of day of hospitalisation on neutrophils ($P < 0.001$). Specifically, non-survivors had significantly higher ($P < 0.05$) MPXI on days 2 [9.3 (1.4, 76.8)], 4 [23.8 (-0.7, 62.9)] and 5 [24.7 (10.3, 73.5)] of hospitalisation compared to admission day [8.9 (-1.4, 19.1)]. MPXI was significantly higher ($P = 0.004$) in non-survivors [23.8 (-0.7, 62.9)] compared to survivors [2.5 (-11.5, 25.6)] on day 4. Neutrophils were significantly lower ($P < 0.05$) on days 3 [1,530 (40, 9,450) /uL], 4 [1,210 (30, 13,490) /uL] and 5 [1,690 (10, 12,890) /uL] compared to admission day [6,555 (50, 21,040) /uL]. MPXI was significantly correlated with neutrophils ($\rho = -0.266$, $P = 0.001$).

Conclusion

Serial measurements of MPXI appeared to have prognostic value in hospitalised dogs with CPVE.

Poster Abstracts Clinical Pathology

58 | RICKETTSIA CONORII IN DOGS WITH HEMATOLOGICAL DISORDERS IN MARCHE REGION: PRELIMINARY STUDY

S. Mangiaterra¹, F. Guglielmo¹, B. Castellucci¹ and A. Gavazza²

¹FUTURAVET veterinary reference centre

²University of Camerino, Italy

Background

Rickettsia conorii are obligate intracellular coccoid and Gram-negative organisms, responsible for Mediterranean spotted fever¹. In Mediterranean countries, dogs are natural host of the infection, however, the clinical progression and clinical signs associated with the disease are not fully understood².

Objective

The aim of the study is to describe clinical and hematological alterations in dogs seropositive for Rickettsia conorii in Marche Region (central Italy). The aim of the study is to verify the presence of parasites and in particular of Rickettsia conorii in dogs showing weakness, depression, loss of appetite, difficulty walking and to describe the hematological alterations.

Methods

From January 2022 to April 2023, 31 dogs of different breeds and aged between 5 months and 12 years, were presented to the veterinary hospital for anemia and/or thrombocytopenia and symptoms as depression, loss of appetite, difficulty walking. Haemato-biochemical and tests (PCR or IFAT) for vector-borne blood diseases were performed in all patients.

Results

26 out 31 dogs resulted positive for Rickettsia conorii antibody in serum (IgG and IgM). Among these 1/26 was also positive for Toxoplasma gondii IgG and IgM, 1/26 was also positive for Anaplasma phagocytophilum, and 3/26 were also positive for Ehrlichia canis.

Conclusion

The findings of Rickettsia conorii in all dogs with symptoms and hematological disorders as anemia and thrombocytopenia shows an increasing tendency in Marche region. This vector-borne disease should always be tested in dogs with suspected clinical or clinical-pathological symptoms.

Poster Abstracts Clinical Pathology

59 | PERIPHERAL BLOOD CELL RATIOS AS PROGNOSTIC FACTORS IN FELINE ALIMENTARY LYMPHOMA – A PRELIMINARY STUDY

J Fonseca^{*,†}, **J Peixoto**^{*}, **J Martins**^{*,†}, **J Henriques**^{*,‡}, **N Pinto da Cunha**^{*,§}

^{*} Faculty of Veterinary Medicine, Lusófona University, Lisbon, Portugal, [†] Escola Superior de Saúde, Proteção e Bem Estar Animal, Instituto Politécnico da Lusofonia, Portugal, [‡]Anicura Atlântico, Oncology Referral Centre, Mafra, Portugal, [§] VEDIS – Veterinary Expertise In Diagnosis, Porto, Portugal

Background

Peripheral blood cell ratios have been described as prognostic markers in human medicine, with fewer studies on canine and feline species. No studies have assessed the prognostic value of these ratios on feline lymphoma.

Objective

To determine the prognostic value of neutrophil-lymphocyte ratio (NLR) and lymphocyte-monocyte ratio (LMR) on the 60 days survival time on feline alimentary lymphoma.

Methods

Medical data from 30 cats diagnosed with alimentary lymphoma was reviewed. Only cases with a complete blood cell count and blood smear examination, cytology and/or histopathologic diagnosis, complete staging and follow-up were included. The blood ratios and its association with the 60 days survival time were studied with the Chi-square test; cut-off values were achieved using ROC curve analysis.

Results

Chi-square test showed that a low LMR is predictive of dead at 60 days ($p=0,026$). A cut-off point of 3,7 for LMR had a sensitivity and specificity for predicting 60-days survival of 88,9% and 75%, respectively. On ROC curve analysis, the area under the curve (AUC) for LMR was 0,806 (95% CI, 0,621-0,926) ($p=0,001$). There was no association between the NLR ratio and the survival time. ($p=0,457$)

Conclusions

These preliminary results suggest that LMR, but not NLR, may be a non-invasive predictive marker of a shorter survival time in feline alimentary lymphoma. Further studies on a larger cohort of cases, divided according to specific lymphoma classification and with homogeneous inclusion criteria related to treatment, are needed to validate its clinical use.

Poster Abstracts Clinical Pathology

62 | CYTOLOGICAL BONE MARROW CELL DIFFERENTIAL COUNTS AND MORPHOLOGICAL FINDINGS IN THE COMMON MARMOSET (*CALLITHRIX JACCHUS*)

M. Defontis*, **A. Bidaut†** and **R. Fares†**

**Tox and Diag, Defontis Veterinary Clinical Pathology, Bully, FR and †ERBC, FR*

Introduction

Cytological bone marrow evaluation is performed in nonclinical toxicological studies to identify potential effects of tested compounds on hematopoiesis. The common marmoset (*Callithrix jacchus*) is a nonhuman primate (NHP) species used in biomedical research. Due to its small size and the current limited supply of other NHP species such as the Cynomolgus monkey, the number of marmosets used in toxicological studies is expected to increase. The purpose of this study is to describe bone marrow cell differential counts and morphological findings from healthy marmosets.

Materials and Methods

Bone marrow smears were prepared from 7 control marmosets (4 males, 3 females). Two bone marrow smears from one proximal femur were prepared and stained with MGG stain. An approximative 400-cell complete differential cell count and morphological assessment were performed. For each sex, myeloid to erythroid (M:E) ratios and the percentage of each individual cell types, total granulocytic cells, total erythroid cells, total lymphocytes related to total bone marrow cells were calculated.

Results

All smears were of adequate quality. M:E ratios ranged from 0.8:1 to 1.6:1. Percentages of total granulocytic cells, total erythroid cells and lymphocytes ranged from 40.4% to 52.1%, 33.2% to 50.7% and 8.3 to 13.5%, respectively. Morphological findings were similar to those observed in the Cynomolgus monkey and consisted of occasional giant metamyelocytes and band neutrophils and metarubricyte nuclear blebbing and binucleation.

Conclusions

These results demonstrate technical and scientific appropriateness of cytological bone marrow evaluation in the common marmoset and provide preliminary data regarding background morphological findings.

Poster Abstracts Clinical Pathology

64 | EFFECT OF CHRONIC DISEASES ON CORTISOL LEVELS IN HAIR OF DAIRY GOATS IN INTENSIVE SYSTEM

M. Sierra-García*, **Y. Domínguez-Hernández†**, **A. de la Peña-Moctezuma‡**, **A. Terrazas-García§**, **D. Méndez-Medina¶**, **C. Murcia-Mejía***, **A. Rodríguez-Cortez*** and **E. Candanosa-Aranda***

**Laboratory of Pathology, †Goat Farm and ‡Laboratory of Bacteriology, Highlands Teaching and Research Farm (CEIEPAA), Faculty of Veterinary Medicine (FMVZ), National Autonomous University of Mexico (UNAM), Tequisquiapan, MX, §Department of Livestock Sciences, Faculty of Higher Studies Cuautitlán, National Autonomous University of Mexico (UNAM), Cuautitlán, MX and ¶Department of Pathology and †Department of Reproduction, Faculty of Veterinary Medicine (FMVZ), National Autonomous University of Mexico (UNAM), Mexico City, MX*

Introduction

Stress occurs when an individual perceives the demands of a situation that exceeds their physiological resources and can increase vulnerability to certain diseases. The effect of diseases on chronic stress in goats is unknown. Objective. To determine the effect of chronic infectious diseases in dairy goats on hair cortisol concentrations.

Materials and Methods

60 dairy goats, clinically healthy, multiparous and older than 4 years, were used. Blood samples were collected before pregnant (BP), and samples of hair BP, 7, 80 and 150 d PP. The Luminex Multiplex technique for the determination of Small Ruminant Lentivirus (SRL) (p16 and gp38 antigen), Mycobacterium avium subspecies paratuberculosis (PPA3 antigen) and Brucella sp (native Hapten antigen). The Microscopic Agglutination technique was performed to determine ten serovars of Leptospira spp (Autumnalis, Bratislava, Canicola, Grypotyphosa, Hardjo, Icterohaemorrhagiae, Pomona, Pyrogenes, Serdjo and Tarassovi).

Results

The registered seroprevalences of 71.66% for SRL, 40% for Leptospira and 5% for paratuberculosis. 33.33% of goats tested positive for one disease, 48.33% for two diseases, 10% for 3 diseases and 8.33% were negative for any disease. The highest concentrations of cortisol in hair were at 150 d PP (16.65 ± 1.39 pg/mg) with respect to BP (9.55 ± 0.04 pg/mg) ($P < 0.05$), without significant differences ($P > 0.05$) in cortisol concentrations with respect to the number of diseases.

Conclusions

The results suggest that the concentrations of cortisol in hair was due to the effect of the productive stages. Although no differences were detected between hair cortisol concentrations and diseases.

Acknowledgements: To the National Autonomous University of Mexico for financial support through the project PAPIIT-IN220420

Poster Abstracts Clinical Pathology

67 | RELATION OF DAIRY GOAT CHRONIC DISEASES AND HAIR CORTISOL IN AN INTENSIVE GRAZING PRODUCTION SYSTEM

J.I. Ortega Cortés*, **Y.M. Domínguez Hernández***, **A.M. Terrazas García†**, **L. Cobos Marín‡**, **J.G. Perera Marín§** and **I.E. Candanosa Aranda***

**Faculty of Veterinary Medicine and Zootechnics, Center for Teaching, Research and Extension in Animal Production in Altiplano, National Autonomous University of Mexico, Tequisquiapan, Querétaro, MX, †Faculty of Superior Studies Cuautitlán, Department of Livestock Sciences., National Autonomous University of Mexico, Cuautitlán, Estado de México, MX and ‡Faculty of Veterinary Medicine and Zootechnics, Department of Microbiology and Immunology and §Faculty of Veterinary Medicine and Zootechnics, Department of Reproduction, National Autonomous University of Mexico, Mexico City, MX*

Introduction

There is evidence of the relation between animal welfare and the presence of chronic diseases. Most of dairy goat herds, deal with at least one chronic disease such as caprine arthritis encephalitis (CAE), paratuberculosis (PTB), toxoplasmosis, caseous lymphadenitis, among others. Hair cortisol concentration has been proved as a reliable chronic stress indicator.

Materials and Methods

A group of 70 grazing dairy goats were oestrus-synchronized, 43 pregnant were selected. Blood samples were taken for leptospirosis diagnosis by Microscopic Agglutination Test (MAT), while CAE, PTB and brucellosis via Luminex multiplex. Hair samples were taken (3 d before mating, 7 d postpartum, 60 and 150 d of lactation) for cortisol determination via ELISA assay. SAS® software for statistical analysis with Proc Univariate, Shapiro Wilk, ANOVA with repeated measurements and Tukey tests. Significance level $P < 0.05$.

Results

A 44.18% *Leptospira* sp prevalence was observed, with Icterohaemorrhagiae being the most frequent serovar (51.7%), Hardjo and Pomona (20.7%) and Gripotyphosa (6.9%). CAE-positive in 72% and 46.5% for PTB. 6 goats (14%) were negative for all diseases, 14 (32.5%) positive for 1, 18 (42%) positive for 2, and 5 (11.5%) positive for 3. Hair cortisol showed differences ($P = 0.008$) between productive stages. Productive stages vs number of diseases comparison showed differences in groups with more diseases regardless of productive stage.

Conclusions

Association between number of diseases and higher cortisol concentrations was demonstrated. Or more chronic stress due to more diseases. It is necessary to study other stimuli that raise cortisol concentrations, such as pain.

Acknowledgements: To contact for the financial support.

To the National Autonomous University of Mexico for financial support through PAPIIT-IN220420 project.

Dr. Mayra Sierra for support for statistical analysis.

Poster Abstracts Clinical Pathology

69 | CYTOLOGICAL AND PATHOLOGICAL FINDINGS IN A HORSE WITH HEMOCHROMATOSIS DUE TO CHRONIC IRON OVERLOAD

A. Perez-Ecija^{*}, I. Rodriguez[†] and F.J. Mendoza[‡]

^{}Animal Medicine and Surgery, University of Cordoba, Cordoba, Es and [†]Anatomia y anatomia patológica comparadas and [‡]Animal Medicine and Surgery, University of Cordoba, Es*

Introduction

A 19-years old male Andalusian horse was referred to the Veterinary Teaching Hospital of Cordoba due chronic weight loss, apathy and jaundice.

Materials and Methods

Hematology was normal. Biochemistry showed elevated total bilirubin, aspartate aminotransferase (AST), glutamate dehydrogenase (GDH), gamma-glutamyl transferase (GGT), lactate dehydrogenase (LDH) and alkaline phosphatase (AP). Iron concentration in plasma was in upper limits, while both ferritin and total iron binding capacity (TIBC) were elevated. Clotting times were markedly elongated. An abdominal ultrasound revealed severe hepatic atrophy with rounded liver margins, loss of normal echogenicity and multifocal hyperechoic foci. Liver neoplasia or cirrhosis were the main differential diagnoses.

Methods

Hematology was normal. Biochemistry showed elevated total bilirubin, aspartate aminotransferase (AST), glutamate dehydrogenase (GDH), gamma-glutamyl transferase (GGT), lactate dehydrogenase (LDH) and alkaline phosphatase (AP). Iron concentration in plasma was in upper limits, while both ferritin and total iron binding capacity (TIBC) were elevated. Clotting times were markedly elongated. An abdominal ultrasound revealed severe hepatic atrophy with rounded liver margins, loss of normal echogenicity and multifocal hyperechoic foci. Liver neoplasia or cirrhosis were the main differential diagnoses.

Results

An ultrasound-guided fine-needle aspiration cytology was performed, showing common presence of a golden granular cytoplasmic pigment in hepatocytes and macrophages, marked anisocytosis and mild anisokaryosis in hepatocytes, marked fibrosis and moderate macrophagic inflammation. Histology revealed a severe bridging and portal fibrosis, with severe periportal hepatocellular degeneration and marked hepatocellular and histiocytic siderosis. Perls Prussian blue staining demonstrated that the pigment observed was iron. Since this patient had not received any previous transfusion, a chronic iron nutritional overload causing hepatopathy and hemochromatosis was finally diagnosed. Although owners rejected more testing, it is noteworthy that the horse was in an area where heavy metal are commonly found in water sources.

Conclusions

This case is an example of a uncommon condition which cytological features have been rarely reported.



IDEXX

Discover Pathology Careers



200+ pathologists globally

We are a global team of Veterinary Pathologists who bring experience, dedication, and passion to our work.

When you look for your next opportunity, we hope you'll consider joining!

Ask us about roles in...

- Clinical Pathology
- Anatomic Pathology
- BioAnalytics

[IDEXX.com/careers](https://www.idexx.com/careers)





Sysmex veterinary solutions

Less blood. Deeper insight.






EVIDENT

OLYMPUS

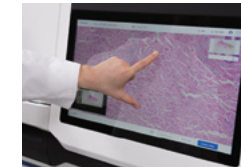
Digital Pathology Slide Scanner
GO DIGITAL WITH SLIDEVIEW DX

Our 1st solution
for clinical routine
digital pathology.
Built on over 100
years of optical
experience.



[EvidentScientific.com](https://www.evidentscientific.com)

EVIDENT EUROPE GMBH
Caffamacherreihe 8-10, 20355 Hamburg, Germany
Postbox 10 49 08, 20034 Hamburg, Germany



Fast and easy to use



Microscope-quality images



Flexible and fully integrated

PARTNERS

Gold sponsor

AnaPath AnaPath is renowned for its scientific competence in toxicological pathology, high operational speed, and reliability. Though a relatively young company, our team's extensive background endows us with a remarkably broad range of experience. We have the resources to support development of pharmaceuticals, chemicals, agrochemicals, and medical devices among many others. Our work encompasses not only our core business of toxicological pathology but also neuropathology, inhalation pathology, bone marrow evaluations, immunological processes, pathology in uncommon laboratory species (fish, amphibian, birds, and invertebrates), hard material techniques, immunohistochemistry/TCR, fetal pathology, and image analysis. Our clients benefit from our teams' scientific excellence in anatomy, toxicological pathology, biomedical engineering, genetics, and regulatory toxicology, regardless of whether they only need support in reevaluating the pathology of an unexpected finding or want us to fully design a complex pre-clinical safety assessment package. www.anapathresearch.com



Silver sponsor

IDEXX At IDEXX, we're focused on enhancing the health and well-being of pets, people, and livestock. With customers in 175+ countries and a global workforce of more than 10,000 talented people - including our team of dedicated Veterinary Pathologists - we work together digitally and in person to give animals a voice. We help pets lead fuller lives by giving veterinarians the tools, technology, and insights to see clearly and get the answers they need. At IDEXX, everything we do is connected. We design the products and services that keep animals around the world healthy and protect life's essentials, like clean drinking water. In doing so, we also enrich the livelihoods of our employees with a positive and respectful work culture that embraces challenges and encourages learning and discovery. That's what matters to us. What about you? www.idexx.com



Sysmex Sysmex supports healthcare professionals around the world in lighting the way with diagnostics by providing a broad range of medical diagnostics products and solutions. With over 50 years' experience in the haematology market, we take veterinary haematology to the next level. Veterinary testing can be challenging at times, not only because of the many species particularities, but also because volume really matters. Maximum insight from minimum sample volumes is at the core of our solutions. Sysmex Europe SE, located near Hamburg, Germany, is a subsidiary of the Sysmex Corporation from Kobe, Japan. From our Hamburg offices, we serve our affiliates, distributors and customers throughout Europe, the Middle East, and Africa (EMEA). www.sysmex-europe.com



PARTNERS

Bronze

EVIDENT

Exhibitor L

Autoscribe Informatics
Deciphex
Diapath
Scil animal care
Slide Score B.V

Exhibitor S

Hammamatsu
Laboklin
PraxisLab
Quilaban
Smart in Media
SPCV
Tridelta Development

Other

Visiopharm

5th Cutting Edge Pathology Congress

28-31 AUGUST 2024
SAN LORENZO DE EL ESCORIAL
(MADRID) SPAIN

Organized under the auspices of the
European Society of Toxicologic Pathology
www.eurotoxpath.org
The European Society of Veterinary Pathology &
The European College of Veterinary Pathologists
www.esvp.eu | www.ecvpath.org



CUTTING EDGE

PATHOLOGY



www.cep-congress.eu

5th Cutting Edge Pathology Congress

28-31 AUGUST 2024 SAN LORENZO DE EL ESCORIAL (MADRID) SPAIN

Dear colleagues and friends,

The European Society of Toxicologic Pathology, the European Society of Veterinary Pathology & The European College of Veterinary Pathologists are pleased to invite you to the **5th Cutting Edge Pathology Congress**. This congress is special as the conference will be a joint venture between the European Society of Toxicologic Pathology, the European Society of Veterinary Pathology and European College of Veterinary Pathologists with an extensive program covering veterinary pathology as well as toxicologic pathology. The meeting will enable both disciplines of pathology to learn from each other's work and we hope it provides opportunities for new collaborative ventures between veterinary and toxicologic pathologists.

For the first time, **5th Cutting Edge Pathology Congress** will be held in San Lorenzo de El Escorial, the mountainous northern satellite town close to Madrid at the Real Centro Universitario Maria Cristina from 28th to 31st August 2024. The venue of the congress is part of the historic monastery declared a UNESCO World Heritage Site and location of the summer courses of the University Complutense of Madrid. Tucked into the mountainous surrounding, San Lorenzo de El Escorial offers not only the impressive monastery closely linked to the Spanish crown, but also quaint little boutiques and a collection of vibrant Spanish tapas bars and elegant restaurants. However, this shall not distract from this event intended to provide a forum for colleagues working in toxicologic and veterinary pathology not only from Europe but from all over the world coming together to exchange their expertise, current challenges and future visions on all aspects of Cutting Edge Pathology.

Two Scientific Committees (ESVP/ECVP and ESTP), comprising both nationally and internationally recognized experts are responsible for preparing the scientific program of the congress. The ESTP part of the congress will be held under the fascinating topic "Neuropathology- The Vast Pink Wonderland". This is an incredibly complex field, encompassing both preclinical and clinical aspects of assessment and therapy. Neurodegenerative diseases serve as a prime example of how impactful neuropathology can be in our daily lives, not to mention the renewed interest in CNS diseases like Alzheimer's, since a number of new drugs received marketing authorization last year. The program will also include additional side topics of highly relevant interest for toxicologic pathologists and preclinical safety scientists. There will be plenary lectures, oral presentations of original scientific work, interactive case presentations, and poster session.

In addition to interesting ESVP/ECVP/ESTP Joint Plenary Lectures, the ESVP/ECVP part of the congress will offer a wide range of updated veterinary pathology topic sessions, covering diseases in both domestic and non-domestic animals. Engaging interactive workshops and educational sessions will be held, along with poster presentations and oral communications. Importantly, the top posters and oral communications will be eligible for prizes to recognize their outstanding contributions to the field. This congress will provide an excellent opportunity to meet and exchange science and knowledge with veterinary pathologist colleagues from all over Europe. Furthermore, following tradition, we will give a warm and proud welcome to the new ECVP graduates of 2024, who represent the brightest future of our specialty.

During the congress you will dive into cutting edge scientific content and also an international trade exhibition where contract laboratories and other services display books, new equipment and latest technologies, etc. in the halls of the Real Centro Universitario Maria Cristina. For all participants, the social program will include a welcome reception and a congress dinner español.

We would be very pleased to welcome you to San Lorenzo de El Escorial (Madrid) in August 2024!



www.cep-congress.eu



28-31 AUGUST 2024 BUDAPEST
EUROPEAN SOCIETY OF VETERINARY
CLINICAL PATHOLOGY CONFERENCE

