

## **Skin Lump in a Cat**

**Contributors:** Harold Tvedten DVM PhD, Anna Hillström DVM PhD

University Animal Hospital

Swedish University of Agricultural Sciences

Ultunaallén 75007 Uppsala Sweden

E-mail: harold.tvedten@slu.se

**Signalment:** 12-year-old, male castrated, house cat had a 5 mm lump in the intact skin of the left side of the thorax.

**Specimen:** Photomicrographs of two smears of a fine needle aspirate (FNA) of the mass, Wright-Giemsa stain

### **Question/task:**

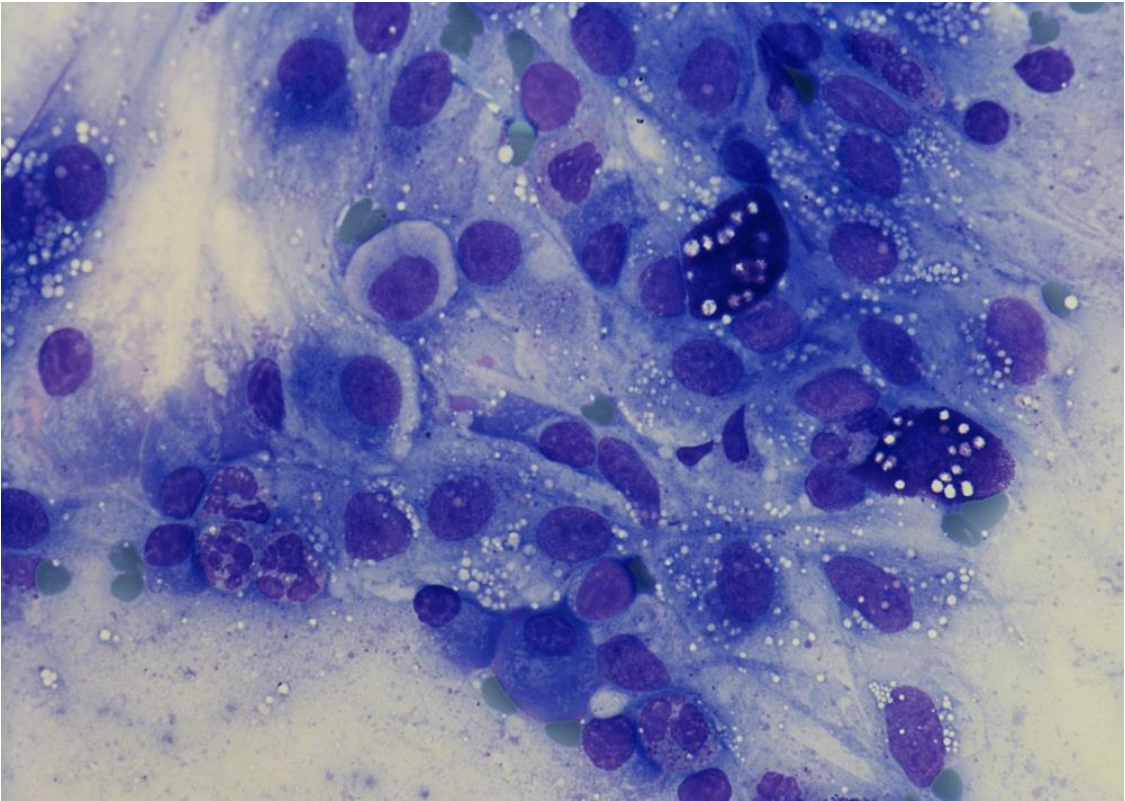
Evaluate the photographs and make as firm a conclusion/ diagnosis as possible.

The most likely diagnosis is:

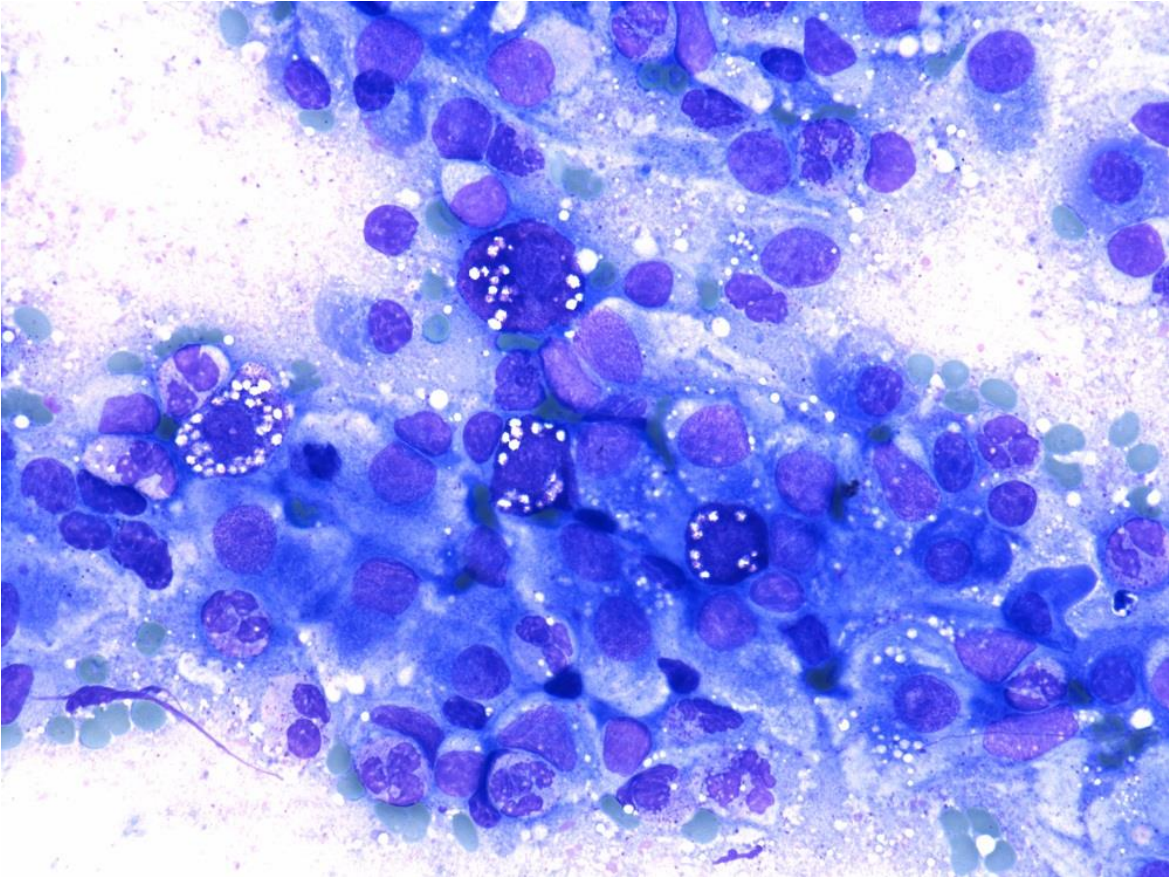
1. Atypical mast cell tumor (histiocytic type)
2. Squamous cell carcinoma
3. Amelanotic melanoma
4. Plasma cell tumor
5. Tick bite reaction

**Figures**

**Figure 1** Smear of a FNA of the lump stained Giemsa stain. Original magnification 600X.



**Figure 2** Smear of a FNA of the lump stained with Giemsa stain. Original magnification 600X.





**Figure 3** Smear of a FNA of the lump stained with Giemsa stain. Original magnification 600X.

